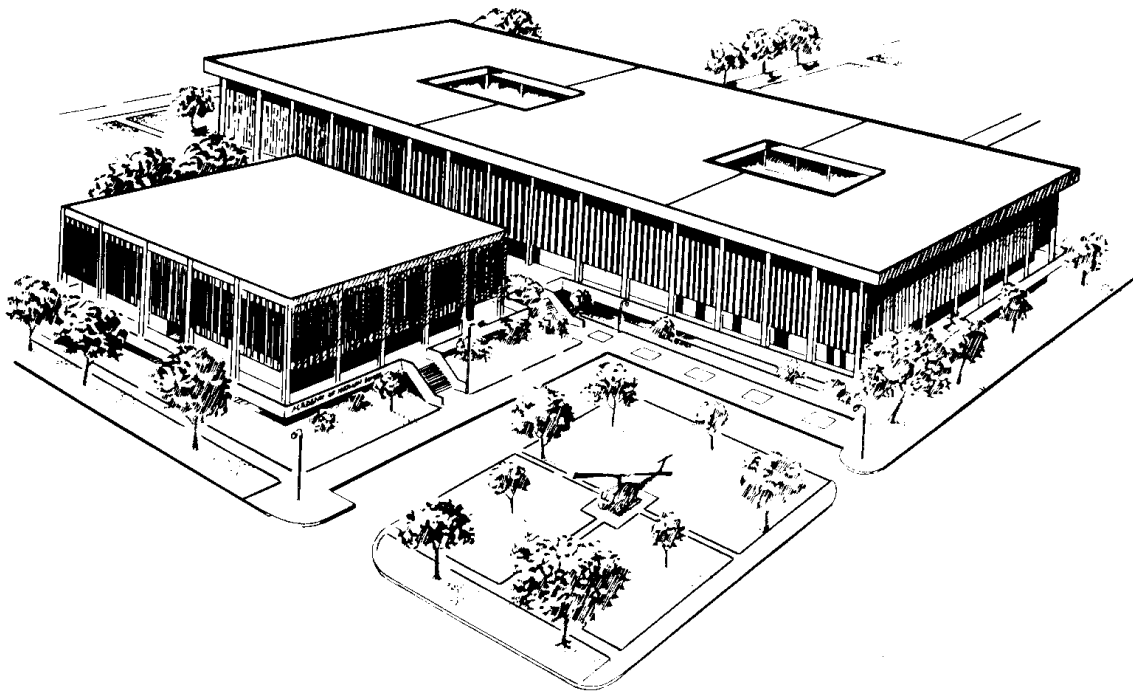

U. S. ARMY MEDICAL DEPARTMENT CENTER AND SCHOOL
FORT SAM HOUSTON, TEXAS 78234



MD0006

BASIC HUMAN ANATOMY

EDITION 100

DEVELOPMENT

This subcourse reflects the current thought of the Academy of Health Sciences and conforms to printed Department of the Army doctrine as closely as currently possible. Development and progress render such doctrine continuously subject to change.

When used in this publication, words such as "he," "him," "his," and "men" are intended to include both the masculine and feminine genders, unless specifically stated otherwise or when obvious in context.

ADMINISTRATION

Students who desire credit hours for this correspondence subcourse must meet eligibility requirements and must enroll through the Nonresident Instruction Branch of the U.S. Army Medical Department Center and School (AMEDDC&S).

Application for enrollment should be made at the Internet website: <http://www.atrrs.army.mil>. You can access the course catalog in the upper right corner. Enter School Code 555 for medical correspondence courses. Copy down the course number and title. To apply for enrollment, return to the main ATRRS screen and scroll down the right side for ATRRS Channels. Click on SELF DEVELOPMENT to open the application and then follow the on screen instructions.

In general, eligible personnel include enlisted personnel of all components of the U.S. Army who hold an AMEDD MOS or MOS 18D. Officer personnel, members of other branches of the Armed Forces, and civilian employees will be considered eligible based upon their AOC, NEC, AFSC or Job Series which will verify job relevance. Applicants who wish to be considered for a waiver should submit justification to the Nonresident Instruction Branch at e-mail address: accp@amedd.army.mil.

For comments or questions regarding enrollment, student records, or shipments, contact the Nonresident Instruction Branch at DSN 471-5877, commercial (210) 221-5877, toll-free 1-800-344-2380; fax: 210-221-4012 or DSN 471-4012, e-mail accp@amedd.army.mil, or write to:

NONRESIDENT INSTRUCTION BRANCH
AMEDDC&S
ATTN: MCCS-HSN
2105 11TH STREET SUITE 4191
FORT SAM HOUSTON TX 78234-5064

TABLE OF CONTENTS

<u>Lesson</u>	<u>Paragraphs</u>	<u>Page</u>
INTRODUCTION		vi
1 INTRODUCTION TO BASIC HUMAN ANATOMY		
Section	I. General.....	1-1--1-6 1-2
	II. Anatomical Terminology	1-7--1-11 1-5
	III. Cells.....	1-12--1-15 1-9
Exercises	1-12
2 TISSUES OF THE BODY		
Section	I. General.....	2-1--2-3 2-2
	II. Epithelial Tissues.....	2-4--2-6 2-2
	III. Connective Tissues	2-7--2-13 2-4
	IV. Muscle Tissues.....	2-14--2-15 2-6
	V. Nervous Tissue.....	2-16--2-17 2-7
Exercises	2-9
3 THE HUMAN INTEGUMENTARY AND FASCIAL SYSTEMS		
Section	I. General.....	3-1--3-2 3-2
	II. The Human Integumentary System.....	3-3--3-8 3-3
	III. The Fascial System of the Human Body.....	3-9--3-11 3-6
	IV. Serous Cavities of the Human Body.....	3-12--3-14 3-6
Exercises	3-9
4 THE HUMAN SKELETAL SYSTEM		
Section	I. General.....	4-1--4-3 4-3
	II. Bone As An Individual Organ.....	4-4--4-6 4-4
	III. Arthrology--The Study of Joints (Articulations)	4-7--4-11 4-7
	IV. The Human Skeleton.....	4-12--4-14 4-12
Exercises	4-27

5 THE HUMAN MUSCULAR SYSTEM			
Section	I.	The Skeletal Muscle	5-1--5-4 5-2
	II.	Some Elementary Skeleto- Muscular Mechanics.....	5-5--5-8 5-6
Exercises		5-10
6 THE HUMAN DIGESTIVE SYSTEM			
Section	I.	Introduction.....	6-1--6-2 6-2
	II.	The Supragastric Structures	6-3--6-5 6-3
	III.	The Stomach	6-6--6-7 6-6
	IV.	The Small Intestines and Associated Glands.....	6-8--6-11 6-6
	V.	The Large Intestines.....	6-12--6-14 6-8
	VI.	Associated Protective Structures	6-15--6-16 6-9
Exercises		6-10
7 THE HUMAN RESPIRATORY SYSTEM AND BREATHING			
Section	I.	The Respiratory System	7-1--7-5 7-2
	II.	Breathing and Breathing Mechanisms in Humans	7-6--7-8 7-9
Exercises		7-11
8 THE HUMAN UROGENITAL SYSTEMS			
Section	I.	The Human Urinary System	8-1--8-6 8-2
	II.	Introduction to Human Genital (Reproductive) Systems.....	8-7--8-9 8-6
	III.	The Human Female Genital (Reproductive) System	8-10--8-13 8-7
	IV.	The Human Male Genital (Reproductive) System	8-14--8-16 8-10
Exercises		8-14

9 THE HUMAN CARDIOVASCULAR AND LYMPHATIC SYSTEMS

Section	I. Introduction.....	9-1--9-3	9-3
	II. The Human Cardiovascular System.....	9-4--9-8	9-4
	III. The Human Lymphatic System	9-9--9-10	9-16
Exercises		9-18

10 THE HUMAN ENDOCRINE SYSTEM

Section	I. Introduction.....	10-1--10-2	10-2
	II. The Pituitary Body	10-3--10-5	10-4
	III. The Thyroid Gland.....	10-6--10-8	10-5
	IV. The Parathyroid Glands.....	10-9--10-10	10-6
	V. The Pancreatic Islets (Islands of Langerhans).....	10-11--10-12	10-6
	VI. The Suprarenal (Adrenal) Glands	10-13--10-15	10-6
	VII. The Gonads.....	10-16--10-18	10-7
Exercises		10-8

11 THE HUMAN NERVOUS SYSTEM

Section	I. Introduction.....	11-1--11-2	11-3
	II. The Neuron and Its "Connections"	11-3--11-7	11-3
	III. The Human Central Nervous System.....	11-8--11-13	11-7
	IV. The Peripheral Nervous System (PNS).....	11-14--11-15	11-15
	V. The Autonomic Nervous System (ANS).....	11-16--11-18	11-19
	VI. Pathways of the Human Nervous System	11-19--11-21	11-21
	VII. The Special Sense of Smell (Olfaction).....	11-22--11-23	11-23
	VIII. The Special Sense of Taste (Gustation).....	11-24--11-25	11-23
	IX. The Special Sense of Vision (Sight)	11-26--11-29	11-24
	X. The Special Sense of Hearing (Auditory)	11-30--11-33	11-30
	XI. The Special Sense of Equilibrium (Balance)	11-34--11-37	11-35

	XII. Controls in the Human Nervous System	11-38--11-39	11-37
Exercises		11-39

LIST OF ILLUSTRATIONS

<u>Figure</u>		<u>Page</u>
1-1	Regions of the human body	1-4
1-2	Anatomical position and medial-lateral relationships.....	1-7
1-3A	The sagittal plane	1-8
1-3B	The horizontal plane.....	1-8
1-3C	The frontal plane	1-8
1-4	A "typical" animal cell (as seen in an electron microscope)	1-10
1-5	Planes of the body (exercise 14).....	1-14
1-6	Directions (exercise 15).....	1-15
1-7	Directions upon members (exercise 16).....	1-16
1-8	A "typical" animal cell (exercise 18).....	1-17
2-1	Epithelial cells.....	2-3
2-2	Types of epithelial tissues	2-3
2-3	Types of muscle tissue.....	2-7
2-4	A neuron.....	2-8
2-5	A synapse.....	2-8
3-1	The integument and related structures.....	3-2
3-2	The integumentary derivatives (appendages)	3-4
3-3	A bursa--the simplest serous cavity.....	3-7
4-1	A mature long bone (femur)	4-4
4-2	A "typical synovial joint"--diagrammatic.....	4-9
4-3A	Anterior view of the human skeleton	4-13
4-3B	Posterior view of the human skeleton	4-14
4-4	A typical vertebra (superior and side views)	4-15
4-5	The human thorax with bones of the shoulder region	4-17
4-6	The human skull (front and side views).....	4-18
4-7	A general pattern of the upper and lower members	4-21
4-8	The human scapula and clavicle (pectoral girdle)	4-22
4-9	The humerus, radius, and ulna.....	4-23
4-10	The human hand	4-24
4-11	The bony pelvis (two pelvic bones and sacrum).....	4-24
4-12	The femur, tibia, and fibula (anterior views)	4-25
4-13	The human foot.....	4-26
5-1	Skeletal and facial muscles, anterior view.....	5-4
5-2	Skeletal and facial muscles, posterior view	5-5
5-3	Types of lever systems.....	5-7
5-4	A simple pulley (the human knee mechanism).....	5-7
5-5	The skeleto-muscular unit (arm-forearm flexion (3rd class lever system))	5-8
6-1	The human digestive system.....	6-2
6-2	Anatomy of the oral complex.....	6-4
6-3	Section of a tooth and jaw	6-4

7-1	The human respiratory system	7-3
7-2	Supralaryngeal structures.....	7-4
7-3	The larynx.....	7-7
7-4	Infralaryngeal structures ("respiratory tree").....	7-8
8-1	The human urinary system.....	8-2
8-2	A section of a human kidney	8-3
8-3	A "typical" nephron	8-4
8-4	The human female genital system	8-8
8-5	The human male genital system (continued)	8-11
9-1	Scheme of blood vessels	9-6
9-2	The human heart.....	9-8
9-3	Scheme of heart valves.....	9-9
9-4	Cardiovascular circulatory patterns	9-11
9-5	Main arteries of the human body.....	9-13
9-6	Main veins of the human body	9-15
9-7	The human lymphatic system.....	9-16
10-1	The endocrine glands of the human body and their locations.....	10-3
11-1	A "typical" neuron	11-4
11-2	A synapse.....	11-6
11-3	A neuromuscular junction.....	11-7
11-4	The human central nervous system (CNS)	11-8
11-5A	Human brain (side view).....	11-9
11-5B	Human brain (bottom view)	11-10
11-6	A cross section of the spinal cord.....	11-13
11-7	A schematic diagram of the meninges, as seen in side view of the CNS....	11-14
11-8	A "typical" spinal nerve, with a cross section of the spinal cord	11-16
11-9	The general reflex arc	11-18
11-10	A horizontal section of the eyeball.....	11-25
11-11	Cellular detail of the retina.....	11-26
11-12	A frontal section of the human ear	11-31
11-13	The labyrinths of the internal ear.....	11-32
11-14	Diagram of the scalae	11-34
11-15	Diagram of semicircular duct orientation	11-36

LIST OF TABLES

<u>Table</u>		<u>Page</u>
4-1	The tissues and functions of structures of a "typical" synovial articulation	4-11
4-2	Bones of the upper and lower members	4-20
7-1	The main divisions of the respiratory system	7-4

**CORRESPONDENCE COURSE OF THE
U.S. ARMY MEDICAL DEPARTMENT CENTER AND SCHOOL**

SUBCOURSE MD0006

BASIC HUMAN ANATOMY

INTRODUCTION

In this subcourse, you will study basic human anatomy. Anatomy is the study of body structure. Physiology is the study of body functions. Anatomy and physiology are two subject matter areas that are vitally important to most medical MOSs. Do your best to achieve the objectives of this subcourse. As a result, you will be better able to perform your job or medical MOS.

Subcourse Components:

This subcourse consists of 11 lessons and an examination. The lessons are:

Lesson 1, Introduction to Basic Human Anatomy.

Lesson 2, Tissues of the Body.

Lesson 3, The Human Integumentary and Fascial Systems.

Lesson 4, The Human Skeletal System.

Lesson 5, The Human Muscular System.

Lesson 6, The Human Digestive System.

Lesson 7, The Human Respiratory System and Breathing.

Lesson 8, The Human Urogenital Systems.

Lesson 9, The Human Cardiovascular and Lymphatic Systems.

Lesson 10, The Human Endocrine System.

Lesson 11, The Human Nervous System.

Credit Awarded:

Upon successful completion of this subcourse, you will be awarded 26 credit hours.

Material Furnished:

In addition to this subcourse booklet, you are furnished an examination answer sheet and an envelope. Answer sheets are not provided for individual lessons in this subcourse because you are to grade your own lessons. Exercises and solutions for all lessons are contained in this booklet.

You must furnish a #2 pencil to be used when marking the examination answer sheet.

You may keep the subcourse.

Procedures for Subcourse completion:

You are encouraged to complete the subcourse lesson by lesson. When you have completed all of the lessons to your satisfaction, fill out the examination answer sheet and mail it to the AMEDDC&S along with the Student Comment Sheet in the envelope provided. *Be sure that your name, rank, social security number, and address is on all correspondence sent to the AMEDDC&S.* You will be notified by return mail of the examination results. Your grade on the examination will be your rating for the subcourse.

Study Suggestions:

Here are some suggestions that may be helpful to you in completing this subcourse:

Read and study each lesson assignment carefully.

After reading and studying the first lesson assignment, work the lesson exercises for the first lesson, marking your answers in the lesson booklet. Refer to the text material as needed.

When you have completed the exercises to your satisfaction, compare your answers with the solution sheet located at the end of the lesson. Reread the referenced material for any questions answered incorrectly.

After you have successfully completed one lesson, go to the next lesson and repeat the above procedures.

When you have completed all of the lessons, complete the examination. Reread the subcourse material as needed. We suggest that you mark your answers in the subcourse booklet. When you have completed the examination items to your satisfaction, transfer your responses to the examination answer sheet.

Student Comment Sheet:

Provide us with your suggestions and comments by filling out the Student Comment Sheet found at the back of this booklet and returning it to us with your examination answer sheet.

LESSON ASSIGNMENT

LESSON 1

Introduction to Basic Human Anatomy.

TEXT ASSIGNMENT

Paragraphs 1-1 through 1-15.

LESSON OBJECTIVES

After completing this lesson, you should be able to:

- 1-1. Define anatomy.
- 1-2. Characterize individuals according to body type and state clinical significance.
- 1-3. Identify kinds of anatomical studies.
- 1-4. Trace the organization of the human body into cells, tissues, organs, organ systems, and the total organism.
- 1-5. List the parts of an upper member and the parts of a lower member.
- 1-6. Identify a reason for studying terminology.
- 1-7. Define the anatomical position.
- 1-8. Given drawings illustrating planes and directions, name the planes and directions.
- 1-9. Define the cell and match names of major components with drawings representing them.

SUGGESTION

After completing the assignment, complete the exercises at the end of this lesson. These exercises will help you to achieve the lesson objectives.

LESSON 1

INTRODUCTION TO BASIC HUMAN ANATOMY

Section I. GENERAL

1-1. DEFINITIONS

a. Anatomy is the study of the structure of the body. Often, you may be more interested in functions of the body. Functions include digestion, respiration, circulation, and reproduction. Physiology is the study of the functions of the body.

b. The body is a chemical and physical machine. As such, it is subject to certain laws. These are sometimes called natural laws. Each part of the body is engineered to do a particular job. These jobs are functions. For each job or body function, there is a particular structure engineered to do it.

c. In the laboratory, anatomy is studied by dissection (SECT = cut, DIS = apart).

1-2. BODY TYPES

No two human beings are built exactly alike, but we can group individuals into three major categories. These groups represent basic body shapes.

MORPH = body, body form

ECTO = all energy is outgoing

ENDO = all energy is stored inside

MESO = between, in the middle

ECTOMORPH = slim individual

ENDOMORPH = broad individual

MESOMORPH = body type between the two others, "muscular" type

Ectomorphs, slim persons, are more susceptible to lung infections. Endomorphs are more susceptible to heart disease.

1-3. NOTE ON TERMINOLOGY

a. Each profession and each science has its own language. Lawyers have legal terminology. Physicians and other medical professions and occupations have medical

terminology. Accountants have debits, credits, and balance sheets. Physicists have quanta and quarks. Mathematicians have integrals and differentials. Mechanics have carburetors and alternators. Educators have objectives, domains, and curricula.

b. To work in a legal field, you should know the meaning of quid pro quo. To work in a medical field, you should know the meanings of terms such as proximal, distal, sagittal, femur, humerus, thorax, and cerebellum.

1-4. KINDS OF ANATOMICAL STUDIES

a. Microscopic anatomy is the study of structures that cannot be seen with the unaided eye. You need a microscope.

b. Gross anatomy by systems is the study of organ systems, such as the respiratory system or the digestive system.

c. Gross anatomy by regions considers anatomy in terms of regions such as the trunk, upper member, or lower member.

d. Neuroanatomy studies the nervous system.

e. Functional anatomy is the study of relationships between functions and structures.

1-5. ORGANIZATION OF THE HUMAN BODY

The human body is organized into cells, tissues, organs, organ systems, and the total organism.

a. Cells are the smallest living unit of body construction.

b. A tissue is a grouping of like cells working together. Examples are muscle tissue and nervous tissue.

c. An organ is a structure composed of several different tissues performing a particular function. Examples include the lungs and the heart.

d. Organ systems are groups of organs which together perform an overall function. Examples are the respiratory system and the digestive system.

e. The total organism is the individual human being. You are a total organism.

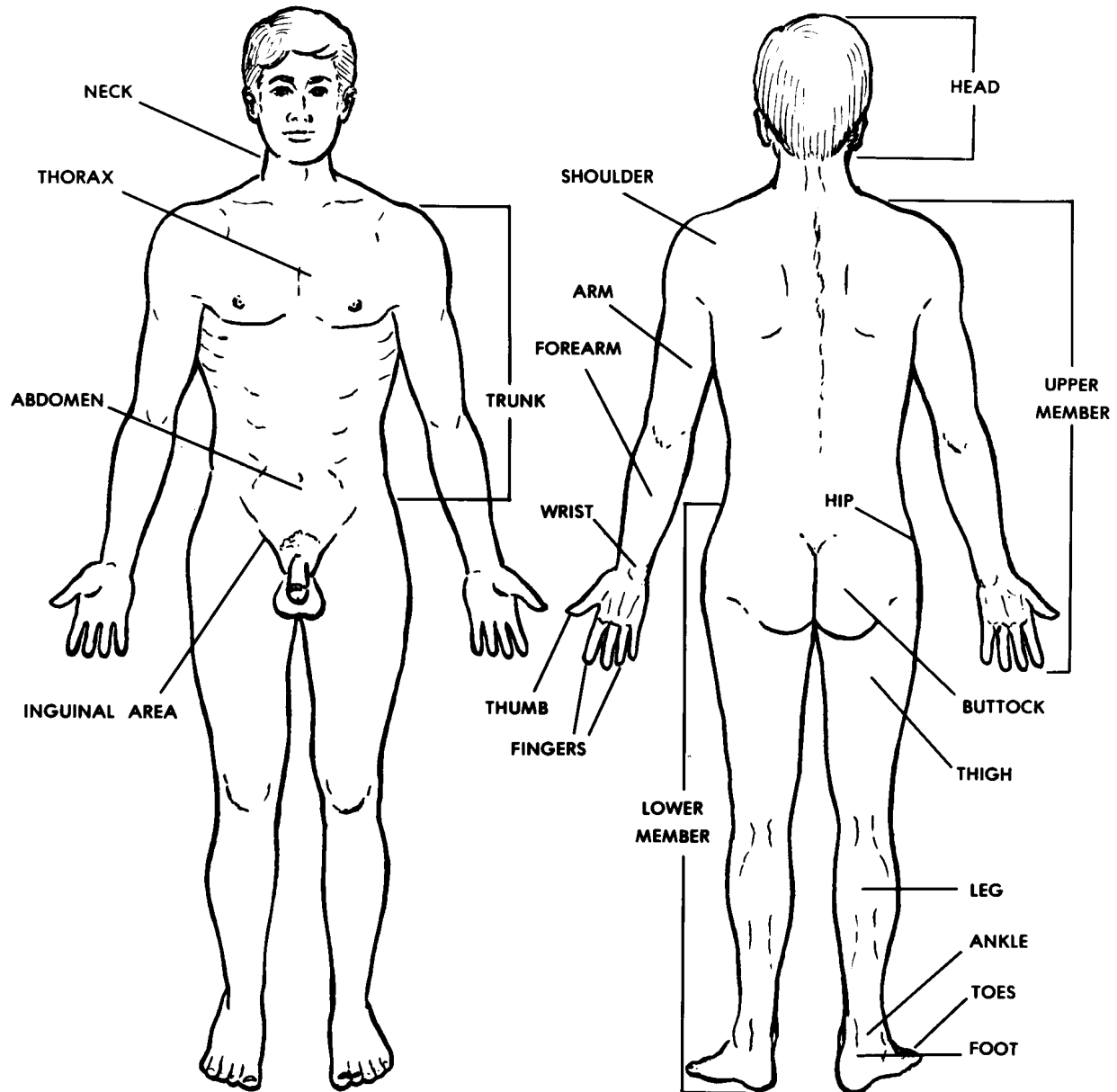


Figure 1-1. Regions of the human body.

1-6. REGIONS OF THE HUMAN BODY (FIGURE 1-1)

The human body is a single, total composite. Everything works together. Each part acts in association with ALL other parts. Yet, it is also a series of regions. Each region is responsible for certain body activities. These regions are:

a. **Back and Trunk.** The torso includes the back and trunk. The trunk includes the thorax (chest) and abdomen. At the lower end of the trunk is the pelvis. The perineum is the portion of the body forming the floor of the pelvis. The lungs, the heart, and the digestive system are found in the trunk.

b. **Head and Neck.** The brain, eyes, ears, mouth, pharynx, and larynx are found in this region.

c. **Members.**

(1) Each upper member includes a shoulder, arm, forearm, wrist, and hand.

(2) Each lower member includes a hip, thigh, leg, ankle, and foot.

Section II. ANATOMICAL TERMINOLOGY

1-7. ANATOMICAL TERMINOLOGY

a. As mentioned earlier, you must know the language of a particular field to be successful in it. Each field has specific names for specific structures and functions. Unless you know the names and their meanings, you will have trouble saying what you mean. You will have trouble understanding what others are saying. You will not be able to communicate well.

b. What is a scientific term? It is a word that names or gives special information about a structure or process. Some scientific terms have two or three different parts. These parts are known as a PREFIX, a ROOT (or base), and a SUFFIX. An example is the word subcutaneous.

SUB = below prefix

CUTIS = skin root

SUBCUTANEOUS = below the skin

A second example is the word myocardium.

MYO = muscle prefix

CARDIUM = heart root

MYOCARDIUM = muscular wall of the heart

A third example is the word tonsillitis.

TONSIL = tonsil (a specific organ) root

ITIS = inflammation suffix

TONSILLITIS = an inflammation of the tonsils

1-8. THE ANATOMICAL POSITION

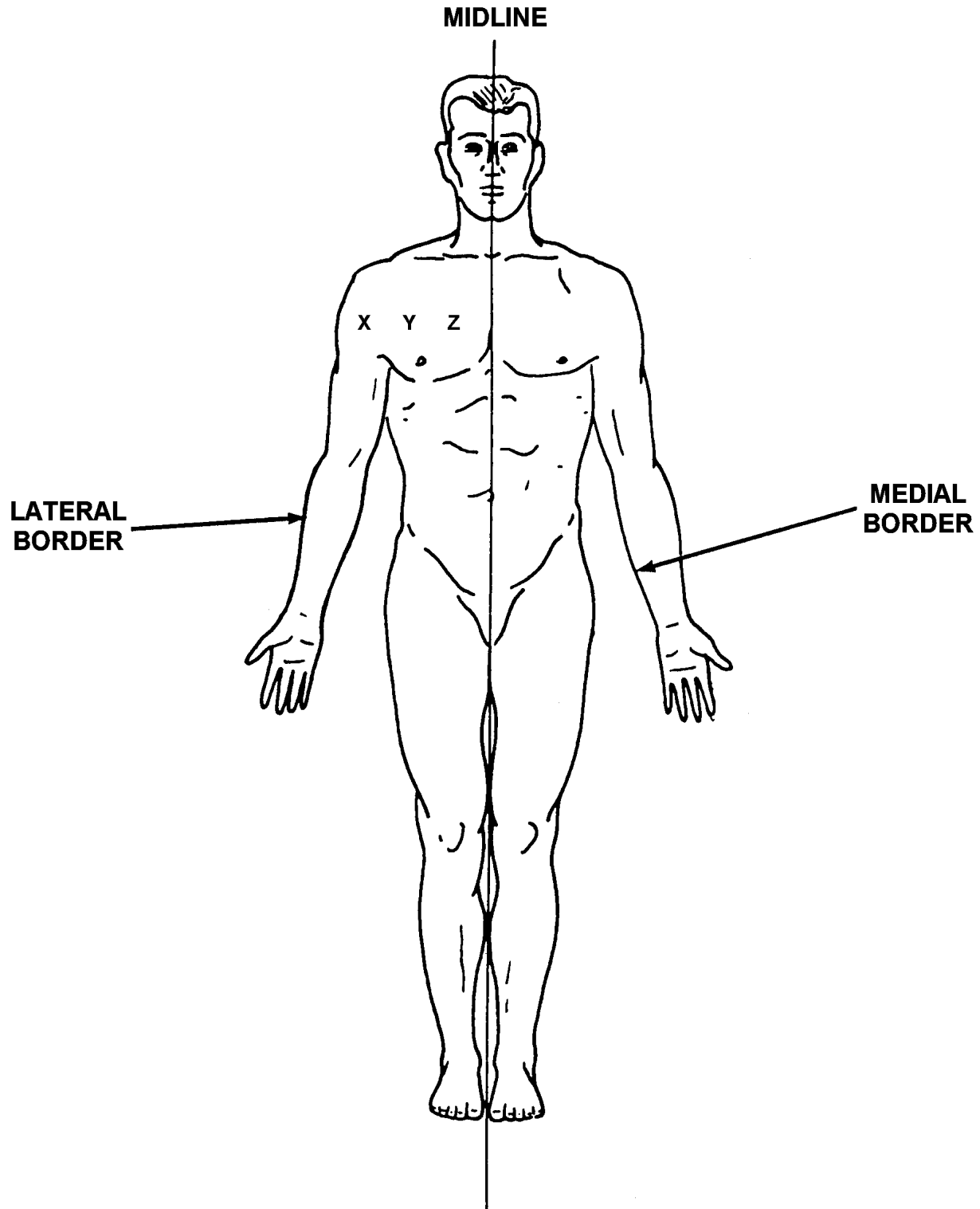
The anatomical position is an artificial posture of the human body (see figure 1-2). This position is used as a standard reference throughout the medical profession. We always speak of the parts of the body as if the body were in the anatomical position. This is true regardless of what position the body is actually in. The anatomical position is described as follows:

- a. The body stands erect, with heels together.
- b. Upper members are along the sides, with the palms of the hands facing forward.
- c. The head faces forward.

1-9. PLANES OF THE BODY

See figures 1-3A through 1-3C for the imaginary planes used to describe the body.

- a. Sagittal planes are vertical planes that pass through the body from front to back. The median or midsagittal plane is the vertical plane that divides the body into right and left halves.
- b. Horizontal (transverse) planes are parallel to the floor. They are perpendicular to both the sagittal and frontal planes.
- c. Frontal (coronal) planes are vertical planes which pass through the body from side to side. They are perpendicular to the sagittal plane.



**X is lateral to Y and Z; Y is medial to X and lateral to Z
In the example shown, the body is in the normal anatomical position.**

Figure 1-2. Anatomical position and medial-lateral relationships.

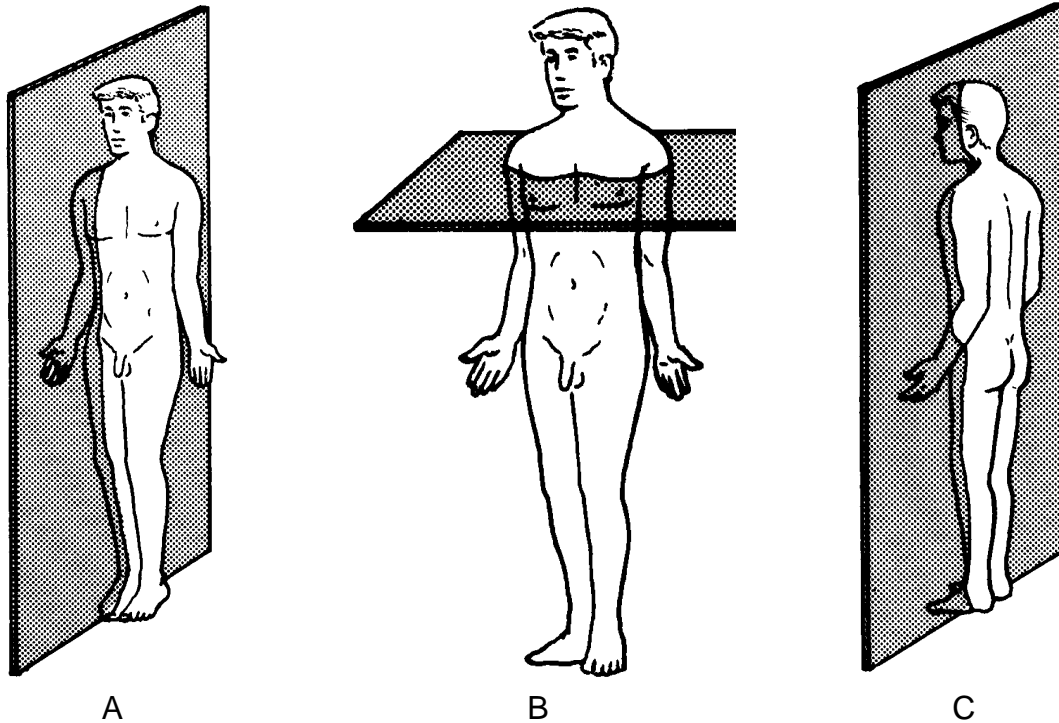


Figure 1-3, A. The sagittal plane. B. The horizontal plane. C. The frontal plane.

1-10. DIRECTIONS

- a. **Superior, Inferior.** Superior means above. Inferior means below.
- b. **Anterior, Posterior.**
 - (1) Anterior (or ventral) refers to the front of the body.
 - (2) Posterior (or dorsal) refers to the back of the body.
- c. **Medial, Lateral.** Medial means toward or nearer the midline of the body. Lateral means away from the midline or toward the side of the body.
- d. **Superficial, Deep.** Superficial means closer to the surface of the body. Deep means toward the center of the body or body part.
- e. **Proximal, Distal.** Proximal and distal are terms applied specifically to the limbs. Proximal means nearer to the shoulder joint or the hip joint. Distal means further away from the shoulder joint or the hip joint. Sometimes proximal and distal are used to identify the "beginning" and "end" of the gut tract--that portion closer to the stomach being proximal while that further away being distal.

1-11. NAMES

a. Names are chosen to describe the structure or process as much as possible. An international nomenclature was adopted for anatomy in Paris in 1955. It does not use the names of people for structures. (The single exception is the Achilles tendon at the back of the foot and ankle.)

b. Names are chosen to identify structures properly. Names identify structures according to shape, size, color, function, and/or location. Some examples are:

TRAPEZIUS MUSCLE

TRAPEZIUS = trapezoid (shape)

ADDUCTOR MAGNUS MUSCLE

AD = toward

DUCT = to carry (function)

MAGNUS = very large (size)

ERYTHROCYTE

ERYTHRO = red (color)

CYTE = cell

BICEPS BRACHII MUSCLE

BI = two

CEPS = head (shape)

BRACHII = of the arm (location)

Section III. CELLS

1-12. INTRODUCTION

A cell is the microscopic unit of body organization. The "typical animal cell" is illustrated in figure 1-4. A typical animal cell includes a cell membrane, a nucleus, a nuclear membrane, cytoplasm, ribosomes, endoplasmic reticulum, mitochondria, Golgi apparatus, centrioles, and lysosomes.

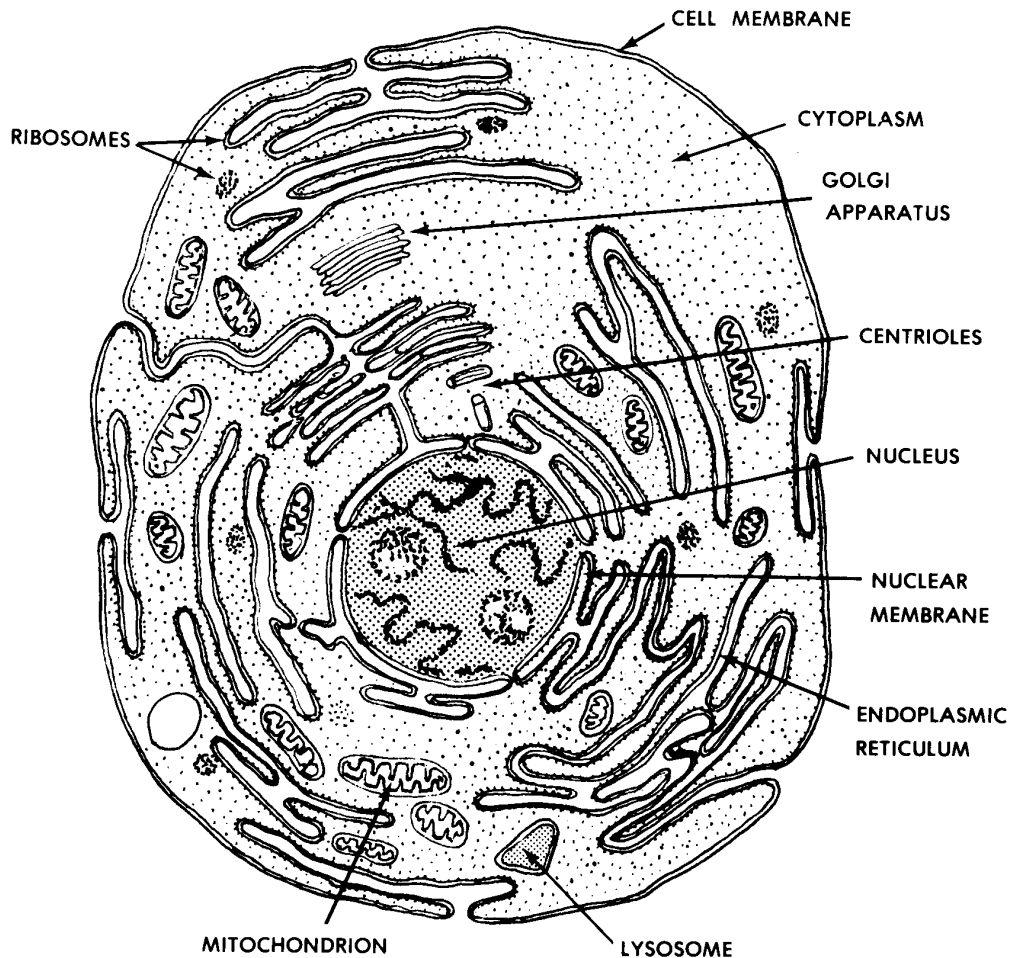


Figure 1-4. A "typical" animal cell (as seen in an electron microscope).

1-13. MAJOR COMPONENTS OF A "TYPICAL" ANIMAL CELL

a. **Nucleus.** The nucleus plays a central role in the cell. Information is stored in the nucleus and distributed to guide the life processes of the cell. This information is in a chemical form called nucleic acids. Two types of structures found in the nucleus are chromosomes and nucleoli. Chromosomes can be seen clearly only during cell divisions. Chromosomes are composed of both nucleic acid and protein. Chromosomes contain genes. Genes are the basic units of heredity which are passed from parents to their children. Genes guide the activities of each individual cell.

b. **Cell Membrane.** The cell membrane surrounds and separates the cell from its environment. The cell membrane allows certain materials to pass through it as they enter or leave the cell.

c. **Cytoplasm.** The semifluid found inside the cell, but outside the nucleus, is called the cytoplasm.

d. **Mitochondria (Plural).** Mitochondria are the "powerhouses" of the cell. The mitochondria provide the energy wherever it is needed for carrying on the cellular functions.

e. **Endoplasmic Reticulum.** The endoplasmic reticulum is a network of membranes, cavities, and canals. The endoplasmic reticulum helps in the transfer of materials from one part of the cell to the other.

f. **Ribosomes.** Ribosomes are "protein factories" in the cell. They are composed mainly of nucleic acids which help make proteins according to instructions provided by the genes.

g. **Centrioles.** Centrioles help in the process of cell division.

h. **Lysosomes.** Lysosomes are membrane bound spheres which contain enzymes that can digest intracellular structures or bacteria.

1-14. CELL MULTIPLICATION (MITOSIS)

Individual cells have fairly specific life spans. Some types of cells have longer life spans than others. During the processes of growth and repair, new cells are being formed. The usual process of cell multiplication is called mitosis. There are two important factors to consider:

a. From one cell, we get two new cells.

b. The genes of the new cells are identical (for all practical purposes) to the genes of the original cell.

1-15. HYPERTROPHY/HYPERPLASIA

Hypertrophy and hyperplasia are two ways by which the cell mass of the body increases.

a. With HYPERTROPHY, there is an increase in the size of the individual cells. No new cells are formed. An example is the enlargement of muscles due to exercise by the increased diameter of the individual striated muscle fibers.

b. With HYPERPLASIA, there is an increase in the total number of cells. An example of abnormal hyperplasia is cancer.

c. ATROPHY is seen when there is a loss of cellular mass.

Continue with Exercises

EXERCISES, LESSON 1

REQUIREMENT. The following exercises are to be answered by completing the incomplete statement or by writing the answer in the space provided at the end of the question. After you have completed all the exercises, turn to "Solutions to Exercises," at the end of the lesson and check your answers.

1. What is anatomy?

2. What is the body type for each of the following individuals?

A broad individual: _____.

A slim individual: _____.

A person with average build: _____.

3. What kind of anatomical study is described by each of the items below?

Study of structures that cannot be seen with the unaided eye:

_____.

Study of relationships between functions and structures:

_____.

Study of the nervous system: _____.

Study of organ systems: _____.

4. What are the five levels or systems into which the body is organized, in ascending order?

5. What is a cell?
6. What is a tissue?
7. What is an organ?
8. What is an organ system?
9. What is the total organism?
10. What are the parts of the upper member? _____, _____,
_____, _____, and _____.
11. What are the parts of the lower member? _____, _____,
_____, _____, and _____.
12. What is one reason for studying terminology?
13. Describe the anatomical position.
 - a. The body stands _____ with _____ together.
 - b. The upper members are along the _____ with palms facing _____.
 - c. The head faces _____.

14. Each plane in figure 1-5 is marked by a letter a, b, c, or d. Write the name of each plane in the appropriate space below.

a. _____ plane.

b. _____ plane.

c. _____ plane.

d. _____ plane.

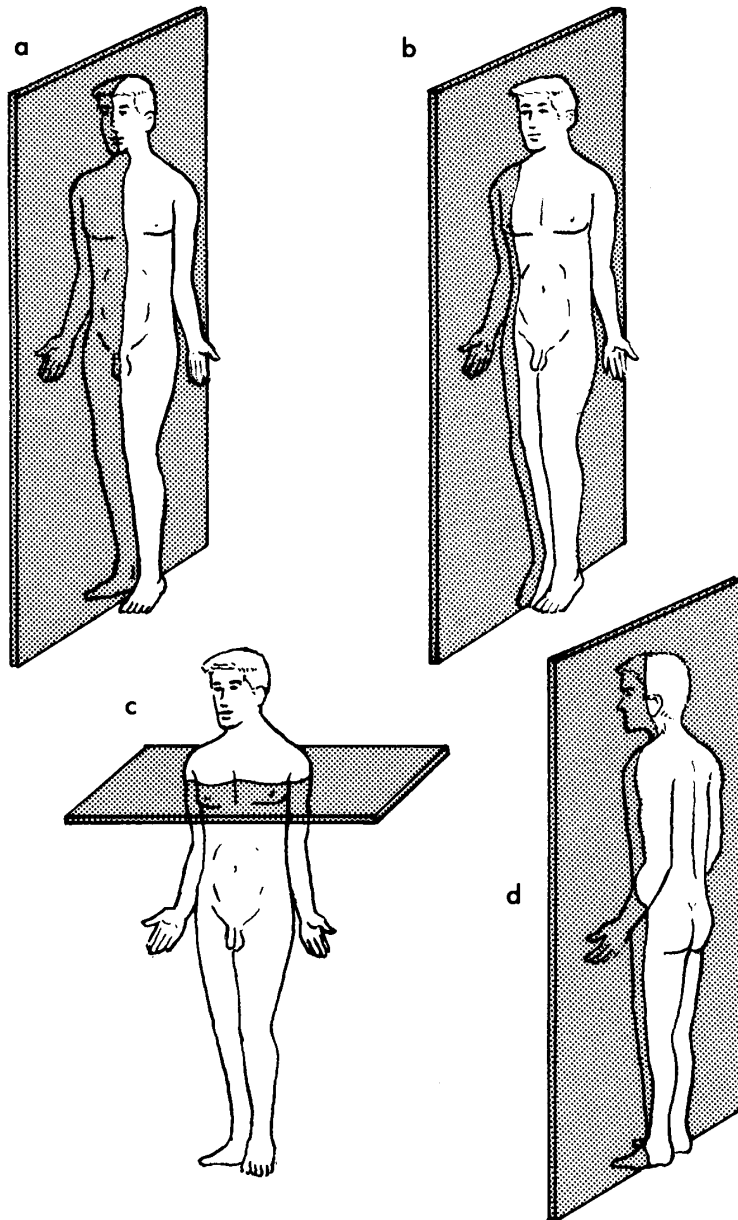


Figure 1-5. Planes of the body (exercise 14).

15. In figure 1-6, three points are labeled a, b, and c, and two borders are labeled d and e. It is correct to say that a is _____ to b and c, b is _____ to a and _____ to c, and c is _____ to a and b. We speak of d as the _____ border. We speak of e as the _____ border.

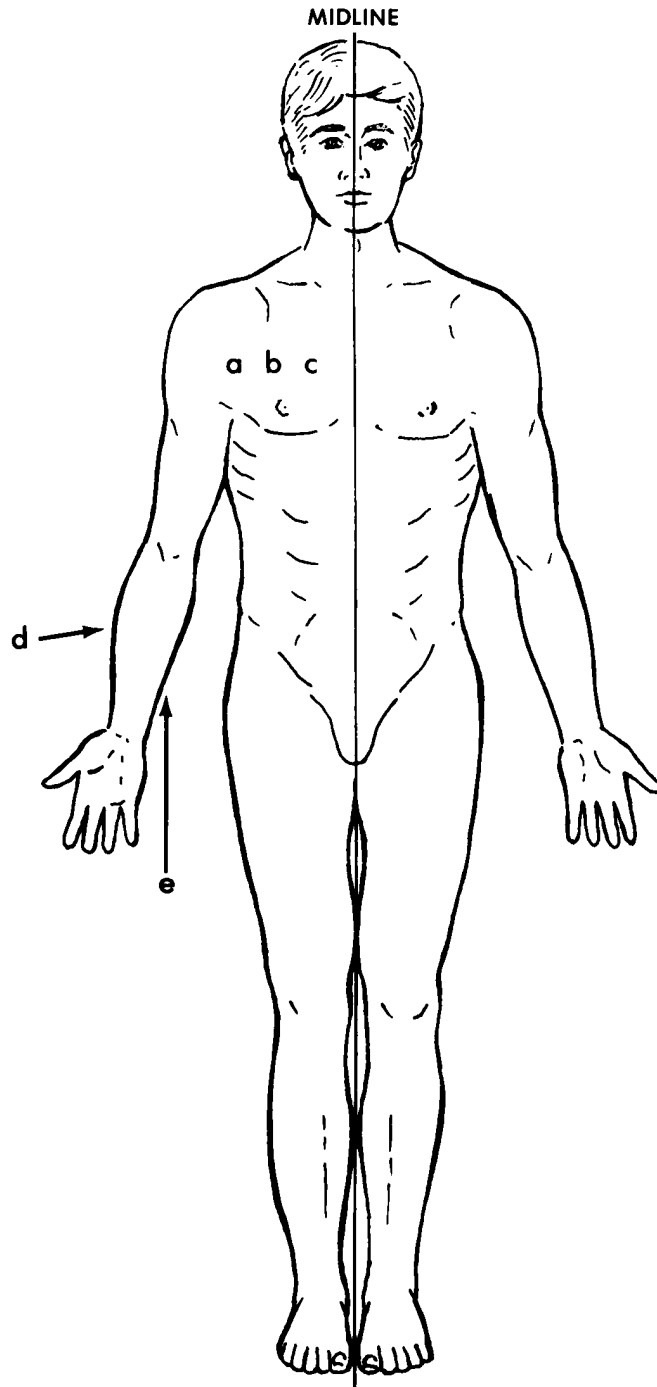


Figure 1-6. Directions (exercise 15).

16. In figure 1-7, three portions of the arm are marked a, b, and c. The two ends of the arm are marked d and e. The portion marked a is the _____ third. The portion marked c is the _____ third. The end marked d is the _____ end. The end marked e is the _____ end.

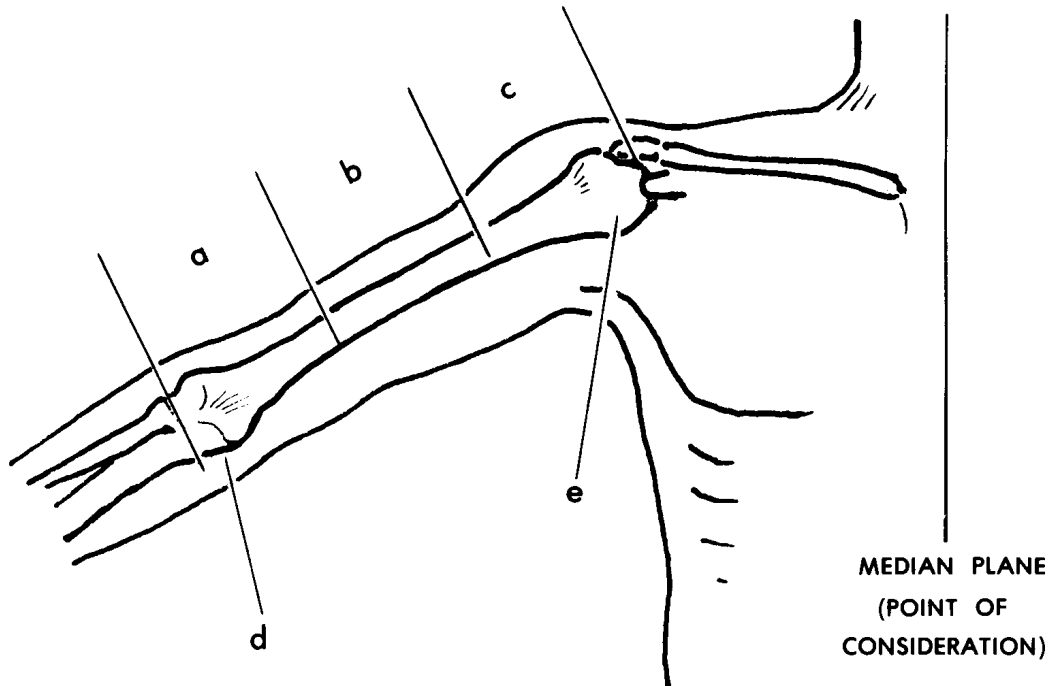


Figure 1-7. Directions upon members (exercise 16).

17. A cell is the _____ unit of body organization.

18. In figure 1-8, parts of a "typical animal cell" are marked with the letters a through g. In the spaces below, provide the name of each structure.

a. _____

e. _____

b. _____

f. _____

c. _____

g. _____

d. _____

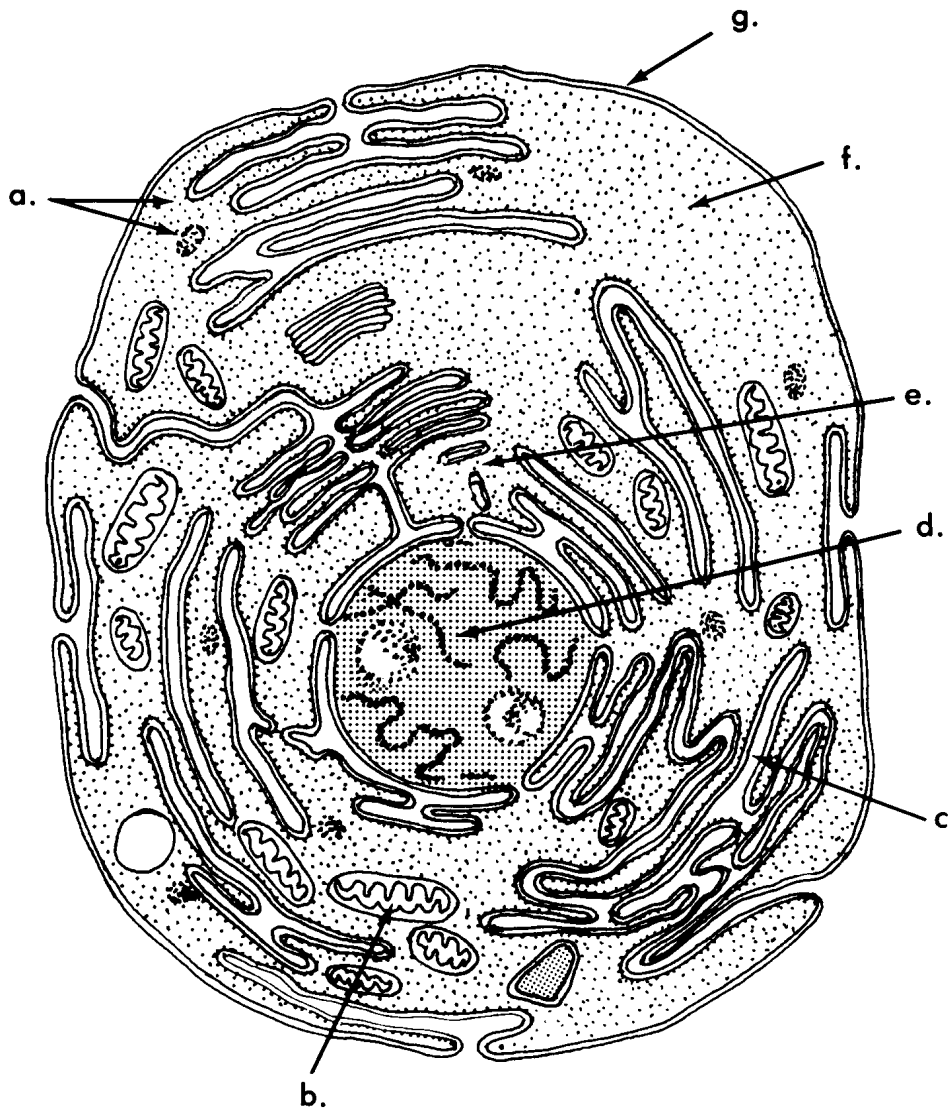


Figure 1-8. A "typical" animal cell (exercise 18).

Check Your Answers on Next Page

SOLUTIONS TO EXERCISES, LESSON 1

1. Anatomy is the study of the structure of the body. (para 1-1a)
2. A broad individual: endomorph.
A slim individual: ectomorph.
A person with average build: mesomorph. (para 1-2)
3. Study of structures that cannot be seen with the unaided eye: microscopic anatomy.
Study of relationships between functions and structures: functional anatomy.
Study of the nervous system: neuroanatomy.
Study of organ systems: gross anatomy by systems. (para 1-4)
4. The body is organized into cells, tissues, organs, organ systems, and the total organism. (para 1-5)
5. A cell is the smallest discrete living unit of the body construction. (para 1-5a)
6. A tissue is a grouping of like cells working together. (para 1-5b)
7. An organ is a structure composed of several different tissues performing a particular function. (para 1-5c)
8. An organ system is a group of organs performing an overall function together. (para 1-5d)
9. The total organism is the individual human being. (para 1-5e)
10. The parts of the upper member are the shoulder, arm, forearm, wrist, and hand. (para 1-6c(1))
11. The parts of the lower member are the hip, thigh, leg, ankle, and foot. (para 1-6c(2))
12. One reason for studying terminology is to be successful in a medical field.
Another reason is to be able to communicate well. (para 1-7a)
13. The anatomical position is described as follows:
 - a. The body stands erect, with heels together.
 - b. The upper members are along the sides, with palms facing forward.
 - c. The head faces forward. (para 1-8)

14.
 - a. Midsagittal or median plane.
 - b. Sagittal plane.
 - c. Horizontal or transverse plane.
 - d. Frontal or coronal plane. (para 1-9)

15. It is correct to say that a is lateral to b and c, b is medial to a and lateral to c, and c is medial to a and b. We speak of d as the lateral border. We speak of e as the medial border. (para 1-10c)

16. The portion marked a is the distal third. The portion marked c is the proximal third. The end marked d is the distal end. The end marked e is the proximal end. (para 1-10e)

17. A cell is the microscopic unit of body organization. (para 1-12)

18.
 - a. Ribosomes.
 - b. Mitochondrion.
 - c. Endoplasmic reticulum.
 - d. Nucleus.
 - e. Centrioles.
 - f. Cytoplasm.
 - g. Cell membrane. (fig 1-4)

End of Lesson 1

LESSON ASSIGNMENT

LESSON 2

Tissues of the Body.

TEXT ASSIGNMENT

Paragraphs 2-1 through 2-17.

LESSON OBJECTIVES

After completing this lesson, you should be able to:

2-1. Define tissue.

2-2. Name four major types of tissues.

2-3. Define epithelial tissue, connective tissue, muscle tissue, and nervous tissue.

2-4. Given a description of epithelial tissue, matrix, fibrous connective tissue, cartilage connective tissue, bone connective tissue, fat connective tissue, smooth muscle tissue, striated muscle tissue, cardiac muscle tissue, nervous tissue, neuron, or glia, name it.

2-5. Name four major types of connective tissue (CT); name the characteristic cells of fibrous CT, cartilage CT, and bone CT; and describe the matrix of fibrous CT, cartilage CT, and fat CT.

SUGGESTION

After completing the assignment, complete the exercises at the end of this lesson. These exercises will help you to achieve the lesson objectives.

LESSON 2

TISSUES OF THE BODY

Section I. GENERAL

2-1. DEFINITION

A tissue is a grouping of like cells working together.

2-2. TYPES OF TISSUES

There are several major types of tissues. The most common types are epithelial, connective, muscle, and nervous tissues. Later, this lesson will discuss each type.

2-3. TISSUES AND ORGANS

a. Tissues make up organs. An organ is a structure performing a particular function. An organ is composed of several different tissues. Examples of organs are the lungs and the heart.

b. In some cases, a term may be used to describe both a type of tissue and a kind of organ. For example, we speak of bone tissue and of bones. We speak of muscle tissue and of muscles.

Section II. EPITHELIAL TISSUES

2-4. DEFINITION

Epithelial tissue is tissue that covers surfaces and lines cavities. Here, it may protect, absorb, and/or secrete. Epithelial tissue covers the outer surface of the body. It lines the intestines, the lungs, and other hollow organs.

2-5. TYPES OF EPITHELIAL CELLS (BY SHAPE)

Figure 2-1 illustrates the basic types of epithelial cells by shape. The three basic shapes are squamous (flat), cuboidal (cubes), and columnar (columns).

d. **Functions.** According to its location, epithelial tissue has different functions. As the skin, epithelial tissue protects the tissues beneath. In the small intestines, the epithelial tissue absorbs. In the lungs, epithelial tissue is a membrane through which the gases pass easily. In the glands, epithelial tissue secretes.

Section III. CONNECTIVE TISSUES

2-7. DEFINITION

a. Connective tissue is tissue that supports other tissues, holds tissues together, or fills spaces.

b. Among and outside the cells of the connective tissues, there is a material called matrix. The matrix is manufactured by the connective tissue cells. Each type of connective tissue has its own particular type of matrix.

2-8. TYPES OF CONNECTIVE TISSUE

There are several major types of connective tissue (CT). These include fibrous CT (FCT), cartilage CT, bone CT, and fat CT. Blood is sometimes considered an additional type of CT.

2-9. FIBROUS CONNECTIVE TISSUE (FCT)

a. **Fibroblasts.** The characteristic cells of FCT are fibroblasts. Fibroblasts are able to form elongated fibers.

b. **Matrix.** These fibers make up the matrix of FCT.

c. **Fibers.** The fibers are either white or yellow.

(1) White fibers are made from a protein called collagen. White fibers tend to have a fixed length. White fibers are not very easily stretched.

(2) Yellow fibers are made from a protein called elastin. Yellow fibers are elastic. They can be stretched and then they can snap back (like a rubber band).

d. **Types of FCT.** The types of FCT are recognized by the arrangement of their fibers. These types include:

(1) Loose areolar FCT. Loose areolar FCT has an open irregular arrangement of its fibers.

AREOLAR = airy

Loose areolar FCT is found widely throughout the body. An example is the superficial fascia (subcutaneous layer). The superficial fascia is the connective tissue which lies beneath the skin. Loose areolar FCT is the filling substance around most organs and tissues of the body.

(2) Dense FCT. The fibers of dense FCT are closely packed and parallel. There are no significant spaces between the fibers. Examples of dense FCT are ligaments and tendons. A ligament is a band of dense FCT that holds the bones together at a joint. A tendon attaches a muscle to a bone.

2-10. CARTILAGE CONNECTIVE TISSUE

a. **Cartilage Cells**. Cartilage cells are also called chondroblasts. Cartilage cells are clustered in microscopic pockets within the cartilage matrix. The cartilage cells produce the material of the matrix.

b. **Matrix**. The matrix produced by the cartilage cells appears homogeneous (the same throughout). The matrix also appears amorphous (shapeless).

c. **Types of Cartilage CT.**

(1) Hyaline cartilage CT. Hyaline cartilage CT appears homogeneous and clear.

HYALINE = clear

This type of cartilage helps to cover bone surfaces at joints. Hyaline cartilage is found as incomplete rings which keep the trachea (windpipe) open.

(2) Fibrous cartilage CT. Fibrous cartilage CT includes dense masses of fibers (of FCT). It is more rigid than hyaline cartilage. The auricle of the external ear is stiffened with fibrous cartilage.

(3) Calcified cartilage CT. Calcified cartilage CT is cartilage that has been stiffened by the addition of calcium salts. This is not the same as bone tissue. An example is the cartilages of the larynx (the voice box) which become calcified with age.

2-11. BONE CONNECTIVE TISSUE

a. **Osteoblasts/Osteoclasts**. Osteoblasts are cells that make and repair bone. Osteoclasts are cells which tear down and remove bone. Bone is continually being remodeled as a person lives. Remodeling is in direct response to the stresses placed on the bone.

b. **Types of Bone Tissues.** There are two major types of bone tissue. One is compact bone CT, which is dense. The other is cancellous bone CT, which is spongy. Compact bone CT forms the hard outer layers of bones as organs. Cancellous bone CT forms the inner, lighter portion of bones.

2-12. FAT CONNECTIVE TISSUE

a. **Fat Cells.** A large fraction of the volume of a fat cell is occupied by a droplet of fat. This droplet has its own membrane, in addition to the outer membrane of the cell. The remaining components of the fat cell, including the nucleus, are found in an outer layer of cytoplasm surrounding the droplet of fat.

b. **Matrix.** Fat connective tissue has a matrix of lipid (oil or fat). There may be yellow fat CT or brown fat CT.

c. **Functions.** Fat CT acts as a packing material among the organs, nerves, and vessels. Fat CT also helps to insulate the body from both heat and cold. Some fat CT serves as a high-energy storage area.

2-13. BLOOD "CONNECTIVE TISSUE"

Some experts consider blood to be a type of connective tissue. Blood will be discussed in lesson 9.

Section IV. MUSCLE TISSUES

2-14. DEFINITION

There are muscle tissues and there are organs called muscles. Muscles are made up of muscle tissues. Muscle tissues and the muscles they make up are specialized to contract. Because of their ability to shorten (contract), muscles are able to produce motion.

2-15. TYPES OF MUSCLE TISSUES

See figure 2-3 for the three types of muscle tissue.

a. **Skeletal Muscle Tissue.** The cells (muscle fibers) of skeletal muscle tissue are long and cylindrical and have numerous nuclei. The arrangement of the cellular contents is very specific and results in a striated appearance when viewed with the microscope. This type of muscle tissue is found mainly in the skeletal muscles.

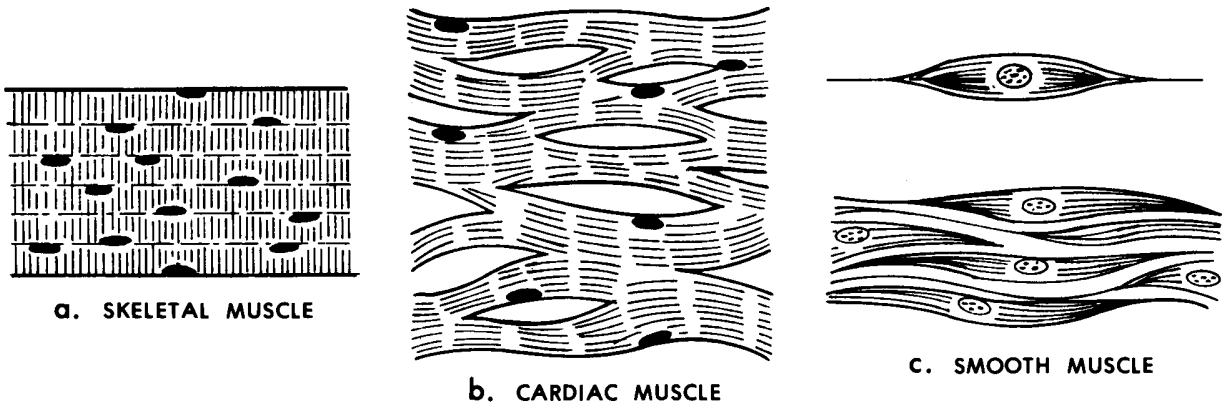


Figure 2-3. Types of muscle tissue.

b. **Cardiac Muscle Tissue.** The cells (muscle fibers) of cardiac muscle tissue are short, branched, contain one nucleus, and are striated. This tissue makes up the myocardium (wall) of the heart.

c. **Smooth Muscle Tissue.** The cells (muscle fibers) of smooth muscle tissue are spindle-shaped, contain one nucleus, and are not striated. Smooth muscle tissue is generally found in the walls of hollow organs such as the organs of the digestive and respiratory systems, the blood vessels, the ureters, urinary bladder, urethra, and reproductive ducts.

Section V. NERVOUS TISSUE

2-16. DEFINITION

Nervous tissue is a collection of cells that respond to stimuli and transmit information.

2-17. NERVOUS TISSUE CELLS

a. A neuron (figure 2-4), or nerve cell, is the cell of the nervous tissue that actually picks up and transmits a signal from one part of the body to another. A synapse (figure 2-5) is the point at which a signal passes from one neuron to the next.

b. The neuroglia (also known as glia) is made up of the supporting cells of the nervous system (glial cells).

c. The nervous tissues will be discussed in a later lesson.

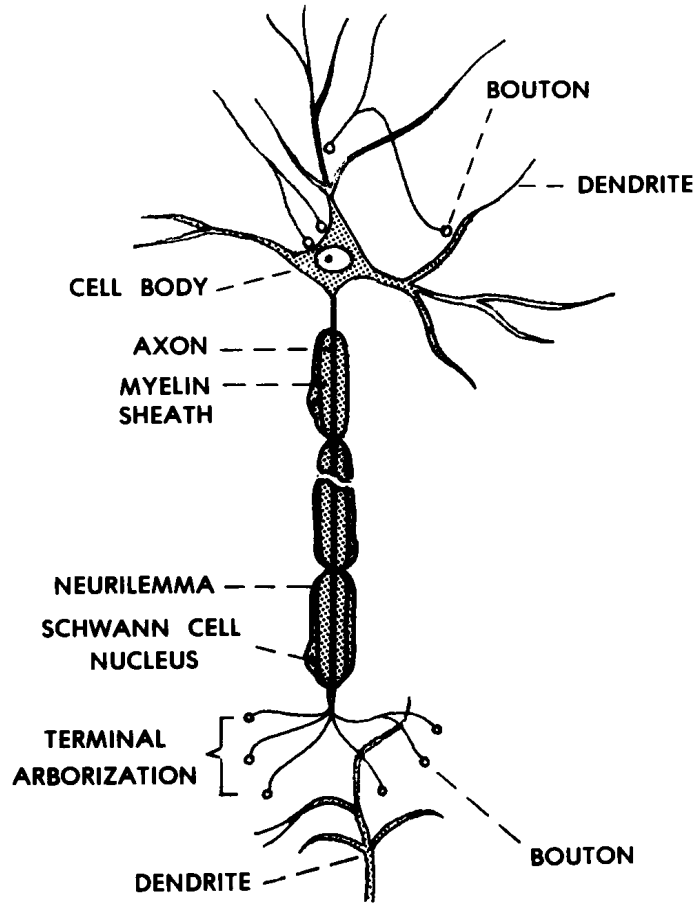


Figure 2-4. A neuron.

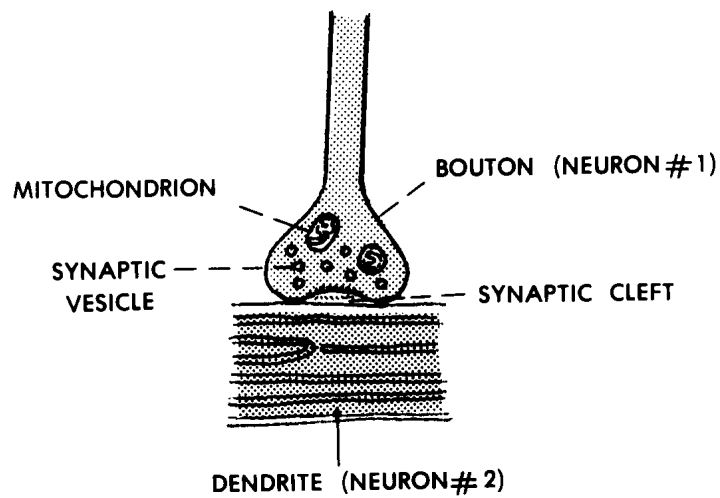


Figure 2-5. A synapse.

Continue with Exercises

8. Characteristic cells of fibrous CT are _____. Cartilage cells are also called _____. Cells that make and repair bone are _____. Cells that tear down and remove bone are _____.

9. The matrix of fibrous CT consists of _____. The matrix produced by cartilage cells appears h_____ and a _____. Fat CT has a matrix of _____.

10. Two major types of fibrous connective tissue (FCT) are _____ FCT, which is a filling substance around most organs and tissues of the body, and _____ FCT, which is found, for example, in ligaments and tendons.

11. What type of connective tissue has an amorphous, homogeneous matrix?

12. What type of connective tissue has a matrix of lipid (fat or oil)?

13. What are muscle tissues?

14. The cells of one type of muscle tissue are spindle-shaped, contain one nucleus, and are not striated. What is this tissue called?

15. Which type of muscle tissue has cells which have one nucleus and are short, branched, and striated?

16. Which type of muscle tissue has cells which have numerous nuclei and are long and cylindrical?

17. What is nervous tissue?

18. What type of tissue has cells that respond to stimuli and transmit information?

19. A nerve cell, which actually picks up and transmits a signal, is also known as a _____.

20. The supporting structure of the nervous system is known as the _____ or the _____.

Check Your Answers on Next Page

SOLUTIONS TO EXERCISES, LESSON 2

1. A tissue is a grouping of like cells working together. (para 2-1)
2.
 - a. Epithelial.
 - b. Connective.
 - c. Muscle.
 - d. Nervous. (para 2-2)
3. Epithelial tissue is tissue that covers surfaces and lines cavities. (para 2-4)
4. If there are several layers and if the outer layer consists of flat cells, then the tissue is called a stratified squamous epithelium. (para 2-6b)
5. Connective tissue is tissue that supports other tissues, holds tissues together, or fills spaces. (para 2-7a)
6. The term used for material found among and outside the cells of connective tissue is matrix. (para 2-7b)
7. The four major types of connective tissue (CT) are fibrous CT, cartilage CT, bone CT, and fat CT. (para 2-8)
8. Characteristic cells of fibrous CT are fibroblasts. Cartilage cells are also called chondroblasts. Cells that make and repair bone are osteoblasts. Cells that tear down and remove bone are osteoclasts. (paras 2-9a, 2-10a, 2-11a)
9. The matrix of fibrous CT consists of fibers. The matrix produced by cartilage cells appears homogeneous and amorphous. Fat CT has a matrix of lipid. (paras 2-9b, 2-10b, 2-12b)
10. Two major types of fibrous connective tissue (FCT) are loose areolar FCT, which is a filling substance around most organs and tissues of the body, and dense FCT, which is found, for example, in ligaments and tendons. (para 2-9d)
11. Cartilage CT. (para 2-10b)
12. Fat CT. (para 2-12b)
13. Muscle tissues are tissues whose contracting elements enable muscles to produce motion. (para 2-14)
14. Smooth muscle tissue. (para 2-15c)
15. Cardiac muscle tissue. (para 2-15b)

16. Skeletal muscle tissue. (para 2-15a)
17. Nervous tissue is a collection of cells that respond to stimuli and transmit information. (para 2-16)
18. Nervous tissue. (para 2-16)
19. A nerve cell, which actually picks up and transmits a signal, is also known as a neuron. (para 2-17a)
20. The supporting structure of the nervous system is known as the glia, or the neuroglia. (para 2-17b)

End of Lesson 2

LESSON ASSIGNMENT

LESSON 3

The Human Integumentary and Fascial Systems.

TEXT ASSIGNMENT

Paragraphs 3-1 through 3-14.

LESSON OBJECTIVES

After completing this lesson, you should be able to:

- 3-1. Define integumentary system, integument proper, integumentary derivatives, fascia, superficial fascia (subcutaneous layer), deep fasciae, and investing deep fascia.
- 3-2. Identify the three coverings, or envelopes, for the human body.
- 3-3. Name and describe the two layers of the skin.
- 3-4. Name and describe three types of integumentary derivatives--hairs, glands, and nails.
- 3-5. Define serous cavities, describe a bursa, and give examples of serous cavities in the body.

SUGGESTION

After completing the assignment, complete the exercises at the end of this lesson. These exercises will help you to achieve the lesson objectives.

LESSON 3

THE HUMAN INTEGUMENTARY AND FASCIAL SYSTEMS

Section I. GENERAL

3-1. DEFINITIONS

An organ system is a group of organs together performing an overall function. Portions of two organ systems, the integumentary and fascial systems, are represented in figure 3-1.

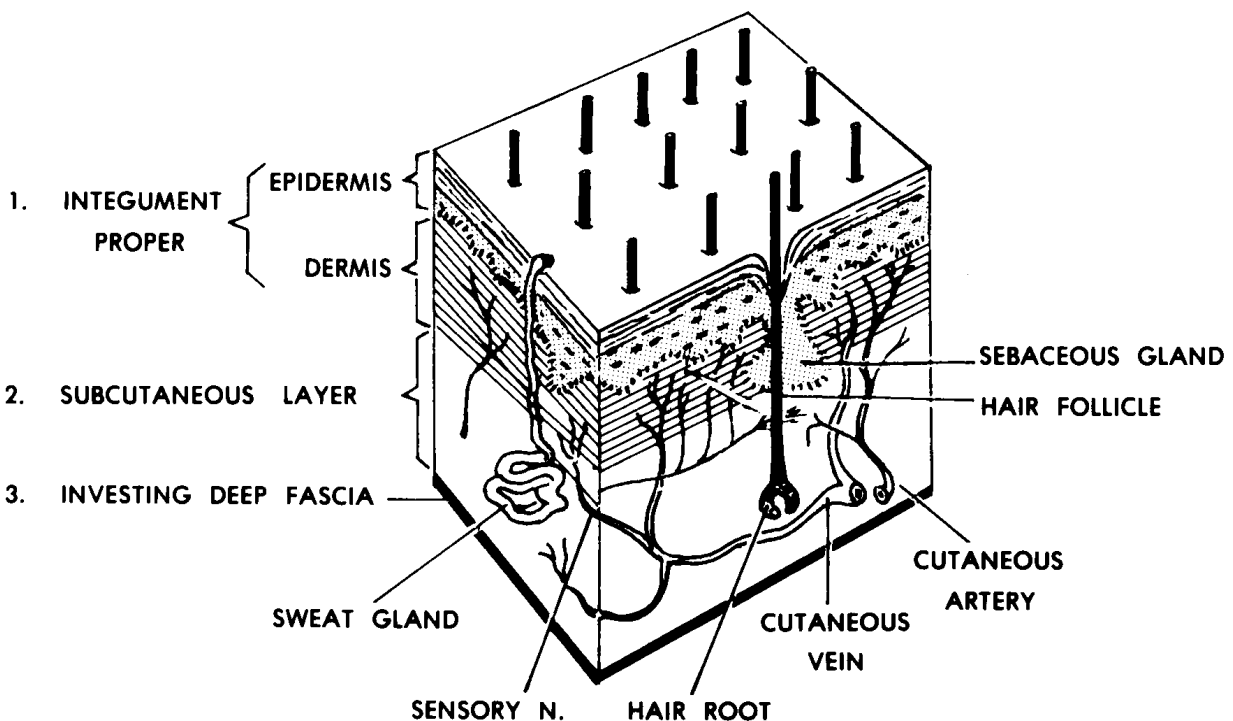


Figure 3-1. The integument and related structures.

a. **Integumentary System.** The integumentary system includes the integument proper and the integumentary derivatives. We know the integument proper as the skin. It is the outermost covering of the whole body. The integumentary derivatives include the hairs, nails, and various glands of the skin.

b. **Fascial System.** A fascia is a sheet or collection of fibrous connective tissue (FCT). The superficial fascia is the connective tissue which lies immediately beneath the skin and is often known as the subcutaneous layer. Deep fasciae (plural) form envelopes for muscles and other organs and fill spaces. One deep fascial membrane is the third envelope of the whole body, beneath the skin and the subcutaneous layer. It is known as the investing deep fascia.

3-2. COVERINGS OF THE HUMAN BODY

The entire body is surrounded by three layers or envelopes, one inside the other. These coverings separate the body from the external environment. These envelopes include (from outside inward)--the skin (the integument proper), the subcutaneous layer, and the investing deep fascia.

Section II. THE HUMAN INTEGUMENTARY SYSTEM

3-3. THE INTEGUMENT PROPER

The integument proper is the outermost layer of the human body. It is usually known as the skin. The skin has two layers--the superficial or outer layer called the epidermis and the deeper or inner layer called the dermis.

a. **The Epidermis.** The epidermis is a stratified squamous epithelium. This means that it is made up of several layers of cells, the outermost being flat-type epithelial cells.

(1) The outer layers of the epidermis include cells which are transparent, flattened, dead, and without nuclei. These hardened cells of the outermost layers are completely filled with keratin and are known as cornified cells. These dead flat cells in the outermost layers resemble scales. Day by day, these cells are scraped away or just fall away from the body. They are replaced by cells from the intermediate layers.

(2) In the intermediate layers of the epidermis, the cells change their shapes. As the cells move towards the surface, they gain granules, begin to manufacture a hardening material called keratin, and lose their nuclei.

(3) The innermost layer of the epidermis is especially important because it is the source of all the other layers of the epidermis. It is known as the basal or germinative layer. The cells of this layer are capable of multiplication (mitosis). Its basic structure is a single layer of columnar-type epithelial cells.

b. **The Dermis (Dermal Layer).** The dermis is the layer of the skin lying just beneath the epidermis. It is dense FCT consisting of white and yellow fibers. This layer in animal hides is used to make leather. The dermis has finger-like projections called papillae. These papillae extend into the epidermis and keep the dermis and epidermis from sliding on each other. The dermal layer includes blood vessels, lymph vessels, nerve endings, hair follicles, and glands.

3-4. INTRODUCTION TO INTEGUMENTARY DERIVATIVES

The integumentary derivatives include the glands, hairs, and nails associated with the skin. All integumentary derivatives are formed from the tissues of the integument proper (dermis and epidermis). All are appended (attached) to the integument proper and are often known as the appendages of the skin. See figure 3-2.

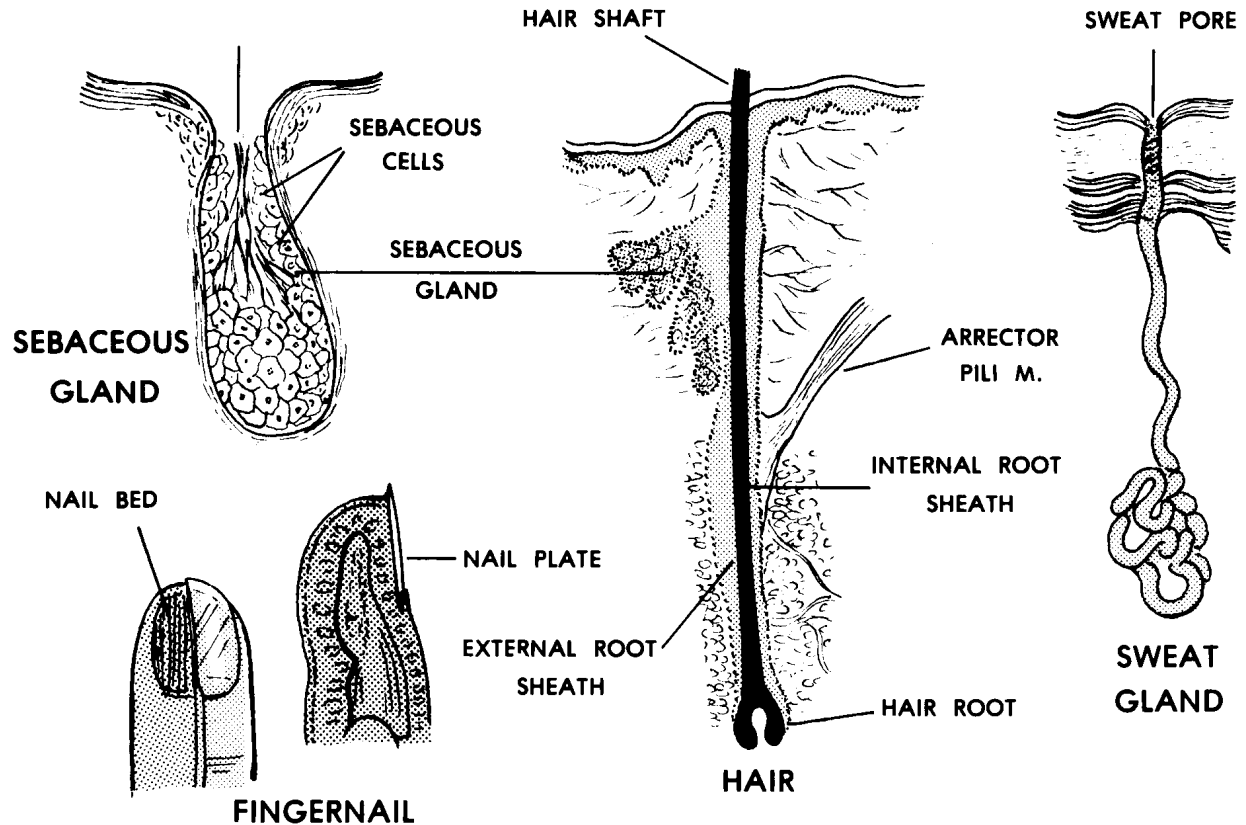


Figure 3-2. The integumentary derivatives (appendages).

3-5. HAIRS

- a. A hair follicle is formed by the extension of the skin (dermis and epidermis) deeper into the surface of the body. Follicles may extend into the subcutaneous layer.
- b. At the base of the hair follicle is the hair root. The hair shaft grows out from the root. The hair shaft is made of cells from the outermost layers of the epidermis.
- c. Scalp and facial hairs grow continuously. Other hairs of the body grow to fixed lengths. The types and patterns of hairs are determined for each individual by genetics, including his/her sex.

3-6. GLANDS

The types of glands included are the sweat glands, the sebaceous (fat/ oil) glands, and the mammary glands (breasts). The ducts and secretory parts of these glands are made of epithelial tissues. Backup or supporting tissue is of FCT.

a. **Sweat Glands.** Sweat glands consist of a coiled secretory portion and a wavy duct which leads to the surface of the skin. The coiled secretory portion is located in the dermis or deeper. Sweat glands are found everywhere on the body in association with the skin.

b. **Sebaceous Glands.** Sebaceous glands produce an oily substance which lubricates the skin and hairs. The oil keeps the skin and hairs flexible. The sebaceous glands are usually found as a part of the walls of hair follicles and their oil flows into the follicle. In a few places without hairs, they open directly to the skin surface.

c. **Mammary Glands.** In the adult human female, the mammary gland lies in the subcutaneous layer anterior to the chest muscle (pectoralis major M.). Its function is to nourish the newborn. A nipple is located near the center of each breast. Around each nipple is a darkened area known as the areola. The tip of the nipple has many small openings to allow the passage of the milk from the milk ducts. These ducts are connected to lobes of glandular tissue located throughout the breast. Fat and fibrous CT fill in the spaces among the lobes.

3-7. NAILS

Nails are found on the ends of the digits (thumbs, fingers, and toes). Nails help to protect the ends of these digits. Each nail bed is attached to the top of the terminal phalanx (bone) of each digit. The nail itself is made up of cornified (hardened) outer cell layers of the epidermis. The nails grow continuously from their roots.

3-8. SKIN COLORATION

a. The skin includes red, black, and yellow pigments. The proportion of these pigments determine the skin color. This proportion is determined by genetics. The absence of all pigments is called albinism. In albinism, white light is reflected and a pink hue results from the color of the blood shining through the transparent skin.

b. These pigments are the source of hair color as well as the skin color.

Section III. THE FASCIAL SYSTEM OF THE HUMAN BODY

3-9. GENERAL

Most of the fibrous connective tissues (FCT) are fascial. These may occur as sheets or masses. NOT included in this definition are the tendons, ligaments, or aponeuroses (wide flat tendons). The different fasciae have varying proportions of white fibers, yellow fibers, fat, and tissue fluid. Some serve as membranes to inclose the body and its parts. Fasciae also help to support some organs and allow motions between other organs to be easier.

3-10. SUPERFICIAL FASCIA

a. The superficial fascia is the second envelope of the body. It is the layer between the skin (integument proper) and the investing deep fascial envelope. It is often called the subcutaneous layer, but it is technically not a part of the integumentary system as such.

b. The superficial fascia is made up primarily of loose areolar FCT with the spaces filled by fatty tissue and tissue fluid. It contains the superficial or cutaneous branches of nerves, arteries, veins, and lymphatics (NAVL) of the skin.

3-11. DEEP FASCIAE

a. The deep fasciae include various membranes made of consolidated or dense FCT. A deep fascia envelops the entire body as the third envelope. This third envelope is known as the investing deep fascia. It is beneath the skin and subcutaneous layer.

b. Deep fasciae also include the envelopes of the muscles and other organs. Around individual organs (for example, the kidney), it is called a capsule.

c. Another form of deep fascia is found in the collections of loose areolar FCT and fat that are found as filling among the organs. Similar deep fasciae attach organs to the body wall.

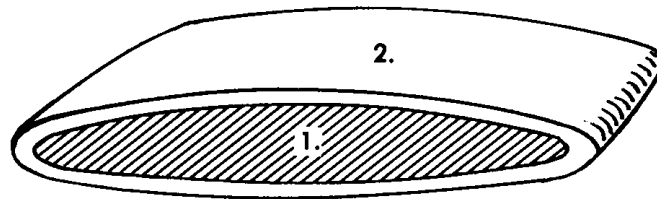
Section IV. SEROUS CAVITIES OF THE HUMAN BODY

3-12. GENERAL

The term serous refers to a watery- type fluid. Serous cavities are sacs lined with serous membranes. These cavities serve as lubricating devices. They reduce the friction during the motion between organs.

3-13. BURSA

a. A bursa (figure 3-3) is the simplest of serous cavities. Each bursa is a small sac located between two moving structures, usually a muscle moving over a bony surface. The bursa reduces the friction between the two structures. For example, a bursa prevents excessive friction between the skin and patella (knee cap). This bursa, called the prepatellar bursa, allows the skin to move freely over the patella. (When injured, it produces excessive amounts of the serous fluid and is known as "housemaid's knee.")



1. SEROUS (BURSAL) CAVITY:
 - a. SPACE CONTAINING JUST ENOUGH SEROUS FLUID TO MOISTEN INNER SURFACE.
 - b. SPACE ARTIFICIALLY WIDENED FOR DIAGRAMMATIC PURPOSES.
2. (BURSAL) CAPSULE:
 - a. BAG-LIKE — SURROUNDING THE SEROUS CAVITY.
 - b. FCT MEMBRANE MAIN STRUCTURAL ELEMENT.
 - c. A SEROUS MEMBRANE (SIMPLE SQUAMOUS EPITHELIAL TISSUE) AS AN INNER LINING OF THE CAPSULE. THE SEROUS MEMBRANE INCLOSES THE SEROUS CAVITY AND SECRETES THE SEROUS FLUID.

Figure 3-3. A bursa--the simplest serous cavity.

b. As a fibrous sac, each bursa has a central cavity which is lined with a serous membrane. This membrane is a simple squamous epithelium. The serous membrane secretes a serous fluid into the serous cavity. The serous fluid is the lubricant, minimizing friction.

3-14. OTHER SEROUS CAVITIES OF THE BODY

a. Other important serous cavities are associated with the major hollow organs, referred to as visceral organs. Each lung is encased in a serous cavity called the pleural cavity. The heart lies in a serous cavity called the pericardial cavity. The intestines are allowed to move freely during the digestive processes within the peritoneal cavity.

b. Each serous cavity has an inner and an outer membrane. The inner membrane is intimately associated with the surface of the visceral organ. The outer membrane forms the outer wall of the cavity. The serous lining of the cavity secretes the serous fluid into the cavity to act as a lubricant between the membranes, allowing freer motion for the organs.

Continue with Exercises

EXERCISES, LESSON 3

REQUIREMENT. The following exercises are to be answered by completing the incomplete statement or by writing the answer in the space provided at the end of the question.

After you have completed all the exercises, turn to "Solutions to Exercises," at the end of the lesson and check your answers.

1. What is included in the integumentary system?
2. What is another name for the integument proper?
3. What are three types of integumentary derivatives?
4. What is a fascia?
5. What is the subcutaneous layer (superficial fascia)?
6. Where are deep fasciae found in the body?
7. What is the investing deep fascia?
8. What is the outer layer of the skin?

What is the inner and deeper layer of the skin?

9. What type of tissue makes up the epidermis?

What is the basic structure of the innermost layer of the epidermis?

What are characteristics of cells found in the outermost layers of the epidermis?

10. What type of tissue makes up the dermis?

What are papillae and what is their function?

What other structures are found in the dermis?

11. A hair follicle is formed by the _____.
At the base of the hair follicle is the _____.
The hair shaft grows out from the _____.
The hair shaft is made of cells from the _____.

12. Sweat glands consist of _____.

13. Sebaceous glands produce _____.
Its function is to _____.
The sebaceous glands are usually found as a part of the walls of _____.

14. In mammary glands, milk ducts connect each nipple with _____.

What types of connective tissue fill in the spaces?

15. Nails are found on the ends of the _____.
Nails help to protect _____.
The nail itself is made up of _____.
The nails grow continuously from their _____.

16. The term serous refers to a _____.
Serous cavities are _____.
These cavities serve as _____.

17. Each bursa is a small sac located between _____,
usually a muscle moving over a _____. The bursa reduces the ____ between
two structures. The serous membrane lining the cavity within a bursa is a _____ and
it secretes a _____ into the serous cavity.

18. Each lung is encased in a serous cavity called the _____. The heart lies in
a serous cavity called the _____. The intestines move freely within the
_____ cavity.

Check Your Answers on Next Page

SOLUTIONS TO EXERCISES, LESSON 3

1. The integumentary system includes the integument proper (skin) and the integumentary derivatives (hairs, nails, and glands of the skin). (para 3-1a)
2. Another name for the integument proper is the skin. (para 3-1a)
3. Three types of integumentary derivatives are the hair, nails, and various glands of the skin. (para 3-1a)
4. A fascia is a sheet or collection of fibrous connective tissue (FCT). (para 3-1b)
5. The subcutaneous layer (superficial fascia) is the connective tissue which lies immediately beneath the skin. (para 3-1b)
6. Deep fasciae are found as envelopes for muscles and other organs and they fill spaces. (para 3-1b)
7. The investing deep fascia is the third envelope of the whole body beneath the skin and the subcutaneous layer. (para 3-1b)
8. The outer layer of the skin is the epidermis. The inner and deeper layer of skin is the dermis. (para 3-3)
9. The epidermis is a stratified squamous epithelium.
The basic structure of the innermost layer of the epidermis is a single layer of columnar-type epithelial cells.
The cells found in the outermost layers of the epidermis are transparent, flattened, dead, cornified, and without nuclei. (para 3-3a)
10. The dermis is dense FCT consisting of white and yellow fibers.
Papillae are finger-like projections of the dermis that extend into the epidermis.
Papillae prevent the dermis and epidermis from sliding on each other.
Other structures found in the dermis include blood vessels, lymph vessels, nerve endings, hair follicles, and glands. (para 3-3b)
11. A hair follicle is formed by the extension of the skin (dermis and epidermis) deeper into the surface of the body. At the base of the hair follicle is the hair root. The hair shaft grows out from the root. The hair shaft is made of cells from the outermost layers of the epidermis. (paras 3-5a, b)
12. Sweat glands consist of a coiled secretory portion and a wavy duct which leads to the surface of the skin. (para 3-6a)

13. Sebaceous glands produce an oily substance. Its function is to lubricate the skin and hairs and to keep them flexible. The sebaceous glands are usually found as a part of the walls of hair follicles. (para 3-6b)
14. In mammary glands, milk ducts connect each nipple with lobes of glandular tissue. Fat and fibrous CT fill in the spaces among the lobes. (para 3-6c)
15. Nails are found on the ends of the digits. Nails help to protect the ends of these digits. The nail itself is made up of cornified (hardened) outer cell layers of the epidermis. The nails grow continuously from their roots. (para 3-7)
16. The term serous refers to a watery-type fluid. Serous cavities are sacs lined with serous membranes. These cavities serve as lubricating devices. (para 3-12)
17. Each bursa is a small sac located between two moving structures, usually a muscle moving over a bony surface. The bursa reduces the friction between the two structures. The serous membrane lining the cavity within a bursa is a simple squamous epithelium and it secretes a serous fluid into the serous cavity. (para 3-13)
18. Each lung is encased in a serous cavity called the pleural cavity. The heart lies in a serous cavity called the pericardial cavity, the intestines move freely within the peritoneal cavity. (para 3-14a)

End of Lesson 3

LESSON ASSIGNMENT

LESSON 4

The Human Skeletal System.

TEXT ASSIGNMENT

Paragraphs 4-1 through 4-14.

LESSON OBJECTIVES

After completing this lesson, you should be able to:

- 4-1. Define skeleton.
- 4-2. Name four functions of the human skeleton.
- 4-3. Name the layers and describe the basic structure of an individual bone, name and describe the parts of an individual long bone, and describe the periosteum and the blood supply of an individual bone.
- 4-4. Describe the development of an individual bone.
- 4-5. Name four types of bones by shape.
- 4-6. Describe major categories used in classification of joints.
- 4-7. Name the major parts of a "typical" synovial joint.
- 4-8. Name and describe classifications of synovial joints according to the kind of motion and number of axes.
- 4-9. Name and define the two major subdivisions of the skeleton.
- 4-10. Describe a typical vertebra. Name the regions of the vertebral column and give the number of vertebrae in each region. Describe the intervertebral discs and ligaments that hold vertebrae together.
- 4-11. Describe the thoracic cage.
- 4-12. Describe the skull.

4-13. Describe the general pattern of the bones of the upper and lower members.

SUGGESTION

After completing the assignment, complete the exercises at the end of this lesson. These exercises will help you to achieve the lesson objectives.

LESSON 4

THE HUMAN SKELETAL SYSTEM

Section I. GENERAL

4-1. INTRODUCTION

The skeleton serves as a support or framework of the human body. It is a combination of bones joined together.

4-2. FUNCTIONS OF THE HUMAN SKELETON

The human skeleton serves the following functions:

- a. **Bodily Support.** The skeletal system provides a framework for the human body.
- b. **Protection.** The skeleton protects certain soft structures within the human body. An example is the skull, which surrounds the brain.
- c. **Motion.** Muscles are attached to and move the bones. Bones provide leverage for motion.
- d. **Formation of Blood Cells (Hematopoiesis).** Blood cells are manufactured in the red bone marrow, mainly found in flat bones.

4-3. PRIMARY STUDY AREAS

In this text, we study the skeletal system from four different viewpoints:

- a. **Bone As Tissues.** This aspect of the human skeletal system was discussed in [paragraph 2-11](#) and will not be further discussed here.
- b. **Bone As An Individual Organ.** Section II of this lesson discusses bone as an individual organ.
- c. **Articulations (Joints)--Arthrology.** Section III of this lesson introduces the study of joints, or arthrology.
- d. **The Human Skeleton.** Section IV of this lesson discusses the human skeleton as a whole in terms of its major subdivisions.

Section II. BONE AS AN INDIVIDUAL ORGAN

4-4. BASIC STRUCTURE OF AN INDIVIDUAL BONE

See figure 4-1 for the basic structure of an individual bone.

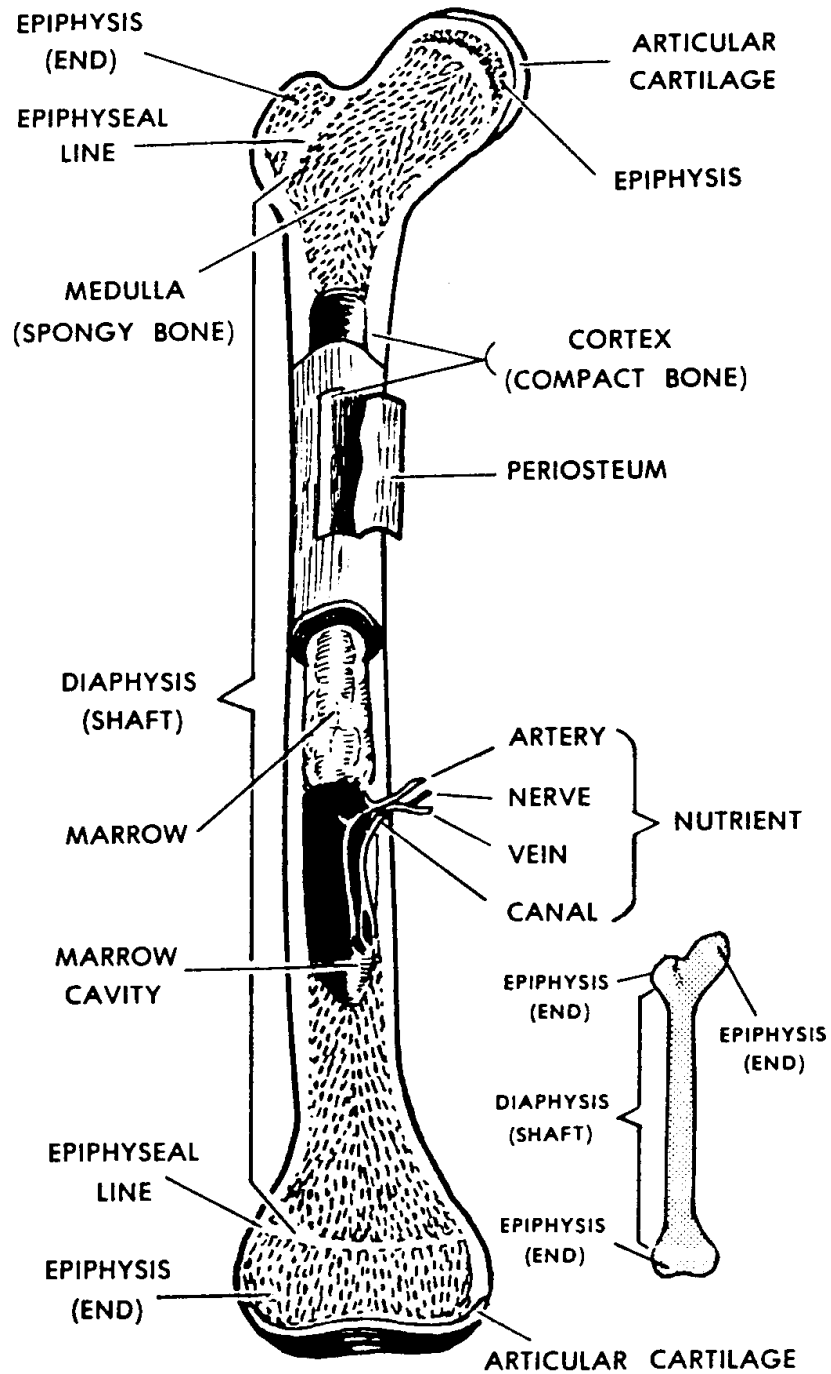


Figure 4-1. A mature long bone (femur).

a. Use of Bony Tissues to Form an Individual Bone.

(1) Cortex. The cortex is the outer layer of the individual bone. It is made up of compact (dense) bony tissue.

(2) Medulla. The medulla is the central portion of the individual bone. It generally consists of cancellous (spongy) bone tissue. In some bones, particularly long bones, the medulla may include a space without any bony tissue. This space is called the medullary or marrow cavity.

b. **Marrow**. Marrow serves as a filler of the inside of bones. There are two types of bone marrow--yellow bone marrow and red bone marrow. Yellow bone marrow is mostly yellow fat tissue. Red bone marrow is the only site in adults for the formation of red blood cells (hematopoiesis).

c. Named Parts of an Individual Long Bone.

(1) Shaft (diaphysis). The shaft is the central portion of a long bone. Here, the cortex is thickened as required by applied physical stresses.

(2) Ends (epiphyses). The ends of long bones are made up mainly of cancellous (spongy) bone tissue. An articular cartilage covers each area where a bone contacts another bone(s). This articular cartilage is made up of hyaline cartilage tissue and provides a smooth surface for motions.

d. **Periosteum**. The periosteum is a covering of the bone surface area not covered by articular cartilage. It has two layers--the innermost layer and the fibrous layer.

(1) The innermost layer, which lies against the outer surface of the bone, consists of bone-forming cells (osteoblasts). It is the osteogenic (bone-forming) layer.

(2) The outermost layer is a FCT (fibrous connective tissue) layer.

(3) The periosteum is well supplied with blood vessels and sensory-type nervous tissue.

e. **Blood Supply of an Individual Bone**. A system of blood vessels enters and spreads out through the periosteum. Additional blood vessels, called "nutrient vessels," penetrate the cortex of the bone and spread out through the marrow. The passageways for penetration of these vessels are called the nutrient canals.

4-5. DEVELOPMENT OF AN INDIVIDUAL BONE

a. **General.** The human skeleton is "preformed" in the early fetus, but the early form is not of bony material. There are two types of bones according to their preformed basis: membranous bones and cartilage bones. These are in the location and have the general shape of the adult bones they will later become.

(1) Membranous bones. The outer skull bones are an example of membranous bones. Osteoblasts invade a membrane to form a center of ossification (formation of bone). Bone-forming activity spreads out from this center until a full bone plate is formed.

(2) Cartilage bones. In the fetus, many bones, for example, long bones, exist first as models formed of cartilage.

b. **Sesamoid Bones.** Sesamoid bones are small masses of bone that develop in tendons at points where great forces are applied to the tendons. The most obvious and largest sesamoid bone is the patella, or kneecap.

c. **Ossification Centers.** An ossification center is a growing mass of actual bone within the preformed material, as noted above.

(1) Initial bone formation involves destruction of the preforming material and replacement with bony tissue.

(2) In the development of long bones, there are two types of ossification centers:

(a) Diaphyseal--in the shaft region.

(b) Epiphyseal--in the end(s).

(3) As a long bone grows in length, the preforming material grows faster than the ossification center can tear it down. Ultimately, with time, the preforming material is overcome and growth ceases.

d. **Growth in Bone Width.** A bone grows wider through the activity of the osteogenic layer of the periosteum. Remember, the periosteum covers most of the outer surface of the bone.

4-6. TYPES OF BONES

Bones of the skeleton can be grouped into the following major types: long, short, flat, and irregular. Each type has a somewhat different construction pattern.

a. **Long Bones.** The basic structure of a long bone is illustrated in figure 4-1 and discussed in paragraph 4-4. Example: femur.

b. **Short Bones.** The short bones, such as those of the wrist and feet, have a thin layer of compact bone surrounding an inner mass of spongy bone. Example: carpal bones.

c. **Flat Bones.** The flat bones are constructed with two plates of compact bone, which enclose between them a layer of spongy bone. The spongy bone is richly supplied with blood vessels and red marrow. Example: the cranial frontal bone.

d. **Irregular Bones.** The irregular bones are those that do not fit into the three categories above. Example: a vertebra.

Section III. ARTHROLOGY--THE STUDY OF JOINTS (ARTICULATIONS)

4-7. DEFINITION

A joint, or articulation, is the location where two or more bones meet.

4-8. TYPES OF JOINTS

Joints are classified according to the kind of material holding the bones together and the relative freedom and kind of motion at the particular joint.

a. **Fibrous Joints.** Varying degrees of motion, from none to some, are possible in fibrous joints.

(1) Syndesmosis. When the bones are held together by FCT (fibrous connective tissue), the joint is referred to as a syndesmosis.

SYN = together
DESMOS = fiber (a tying material)

Example: The inferior tibio-fibular joint.

(2) Suture. When the bones are quite close together with a minimum of FCT, the joint is known as a suture. Example: the joints between the cranial bones.

b. **Bony Joints.** Should the bones be united by bony material, the joint is referred to as a synostosis.

SYN = together
OSTEO = bone

Example: The frontal bone. (The frontal bone of the skull is actually a bony fusion of two bones. Approximately 10 percent of the time, this fusion fails to take place; the original suture between the bones remains and is called a metopic suture.)

c. **Cartilagenous Joints.** These are also nonmovable joints.

(1) Synchondrosis. A cartilagenous joint in which the bones are held together by hyaline cartilage.

SYN = together
CHONDRO = cartilage

Example: Epiphyseal plate.

(2) Symphysis. A cartilagenous joint in which the bones are held together by a disc of fibrocartilage.

Example: Pubic symphysis.

d. **Synovial Joints.** In the synovial type of joints, the bones move on one another so as to allow various motions of the body parts. The "ovial" part of the name refers to the fact that the fluid substance seen in this type of joint appeared to the old anatomists to be like raw egg white (ovum = egg).

4-9. A "TYPICAL" SYNOVIAL JOINT

A "typical" synovial joint is one which has parts common to all of the synovial joints. In a sense, it is imaginary. It is not actually a specific synovial joint. It is a composite. It is illustrated in figure 4-2. The "typical" synovial joint has the following parts:

a. **Bones.** Bones are the levers of motion. They are the site of attachment for skeletal muscles.

b. **Articular Cartilages.** The "contact" points of the bones are usually covered with a layer of lubricated cartilage. Where these cartilages end, the synovial membranes begin. Cartilages provide a smooth surface to reduce friction.

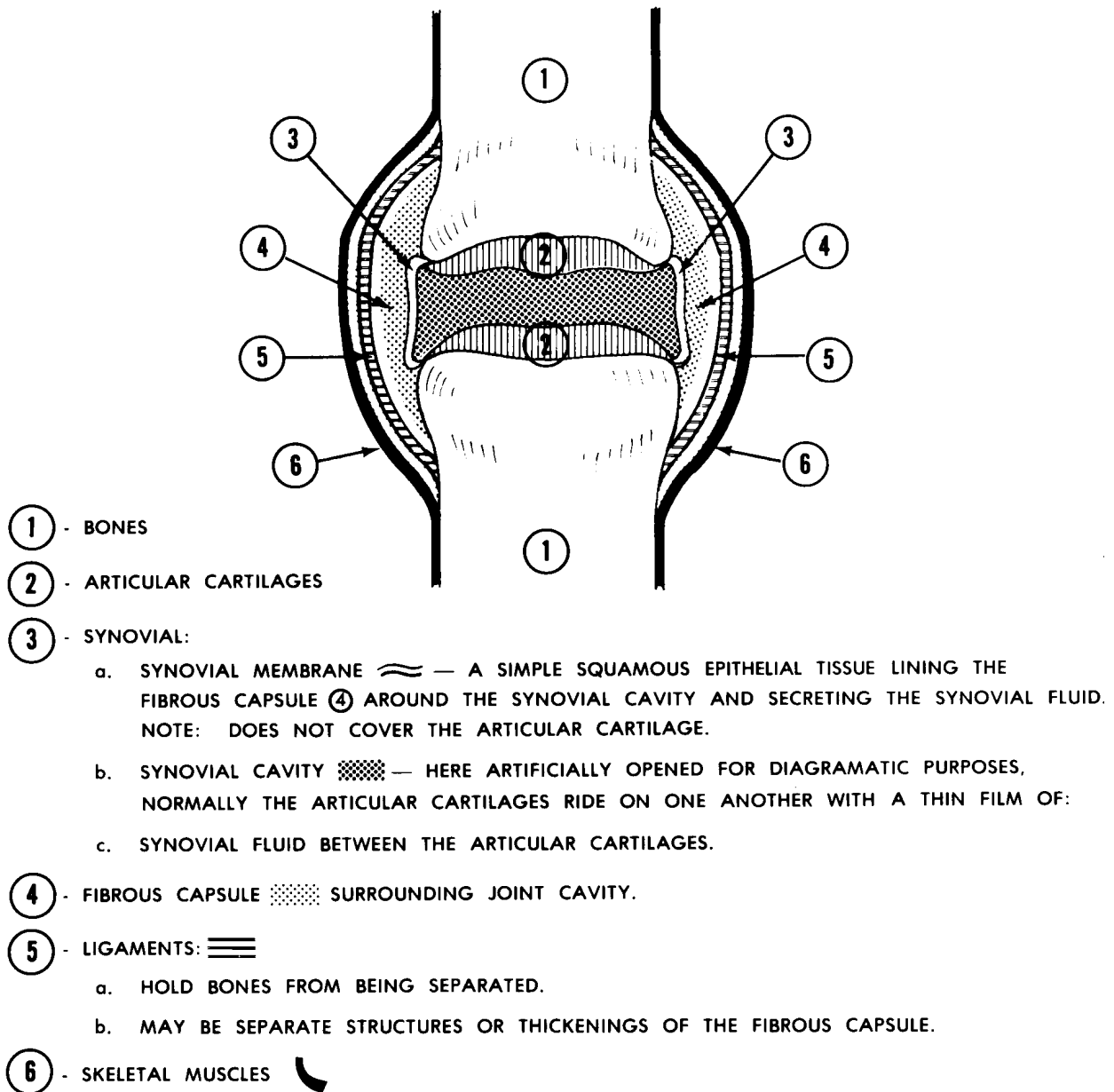


Figure 4-2. A "typical synovial joint:--diagrammatic.

c. **Synovial Membrane, Space, and Fluid.**

(1) Synovial membrane. The synovial membrane lines the inner surface of the capsule. It secretes synovial fluid into the synovial space.

(2) Synovial space. Figure 4-2 exaggerates the amount of space between the bones. The space within the capsule allows movement.

(3) Synovial fluid. Synovial fluid is a colorless, viscous fluid similar in consistency to raw egg white. It lubricates the articulation.

d. **Capsule.** The "typical" synovial articulation is surrounded by a sleeve of dense FCT known as the capsule. The capsule encloses the articulation.

e. **Ligaments.** Primarily, ligaments hold bones together. Ligaments also may help restrain motion in certain directions and stabilize the articulation.

f. **Muscles.** Skeletal muscles apply the forces to produce a given motion.

NOTE: See table 4-1 for a summary of the structures in a "typical" synovial articulation, the tissues composing each structure, and the actions attributed to each structure.

4-10. CLASSIFICATION OF SYNOVIAL JOINTS

Synovial joints are further classified according to the kind of motion and the number of axes of motions used.

a. Uni-Axial Synovial Joints.

(1) In uni-axial synovial joints, motion occurs in only one plane. The joints of the fingers (interphalangeal) flex and extend in the sagittal plane. These are commonly referred to as hinge joints.

(2) If a single rotatory (rotational) motion occurs around a post-like structure, the joint is a pivot joint. The atlas vertebra rotating around the dens (tooth like projection) of the axis vertebra at the top of the neck (base of the skull) is a pivot joint.

b. **Bi-Axial Synovial Joints.** In bi-axial synovial joints, motion between the bones occurs in two planes. Here the surface in contact is curved or rounded in two directions.

(1) The proximal phalanx of a finger can flex and extend and move from side to side on the rounded head of the metacarpal bone. This is the MP or metacarpophalangeal joint.

(2) When the two surfaces are curved in directions at right angles to each other, a shape similar to that of a cowboy's saddle is formed. This type of synovial joint is called a saddle joint. In the human body, the saddle joint is located at the base of the thumb.

STRUCTURE	TISSUE(S)	FUNCTION(S)
1. BONE	BONY	(a) Serves as site of attachment for the skeletal muscles. (b) Serves as lever of motion.
2. ARTICULAR CARTILAGE	HYALINE CARTILAGE	Serves as smooth surface, over which motion takes place.
3. FIBROUS CAPSULE	DENSE FCT	Encloses articulation.
4. SYNOVIAL MEMBRANE	SIMPLE SQUAMOUS EPITHELIUM	(a) Lines capsule. (b) Secretes synovial fluid into synovial space.
5. SYNOVIAL SPACE	-	Frees articulation for motion.
6. SYNOVIAL FLUID	SEROUS FLUID	Lubricates articulation.
7. LIGAMENT	(VERY) DENSE FCT	Holds the bones together.
8. SKELETAL MUSCLE	STRIATED MUSCLE FIBERS	Applies force to produce motion.

Table 4-1. The tissues and functions of structures of a "typical" synovial articulation.

c. **Multi-Axial Synovial Joints.** In multi-axial joints, motion is possible in all three planes of space.

(1) The ball-and-socket-type synovial joint has the freest motion in all directions. A spherically rounded head (ball-like) fits into a receiving concavity (socket). The hip joint is an example of the ball-and-socket type, with the spherical head of the femur fitting into the cup or socket (acetabulum) of the pelvic bone.

(2) In the plane joint, the contact surfaces of the bones are essentially flat. These flat surfaces slide on one another (also called translatory motion). The acromioclavicular joint of the shoulder region is an example of a plane joint.

4-11. THE ARTICULAR DISC

In three of the synovial joints of the human body, a special addition is seen. This addition is known as an articular disc. The joints with articular discs are the temporomandibular joint of the lower jaw, the sternoclavicular joint (at the sternum (breastbone)), and the ulnocarpal joint of the distal end of the forearm.

a. An articular disc is a fibrocartilage plate. It is inserted between the articular surfaces of the bones of a synovial joint. In this way, it divides the synovial space into two spaces.

b. Joints having an articular disc are capable of having several different motions occurring at the same time. Mechanically, there are really two joints together here.

Section IV. THE HUMAN SKELETON

4-12. GENERAL

a. The human skeleton (figures 4-3A and 4-3B) is a collection of individual bones articulated (joined) together.

b. The major subdivisions of the skeleton are the axial skeleton and the appendicular skeleton.

4-13. THE AXIAL SKELETON

The axial skeleton is the central framework of the human body. It includes the skull, the vertebral column (spine), and the thoracic cage (chest or rib cage).

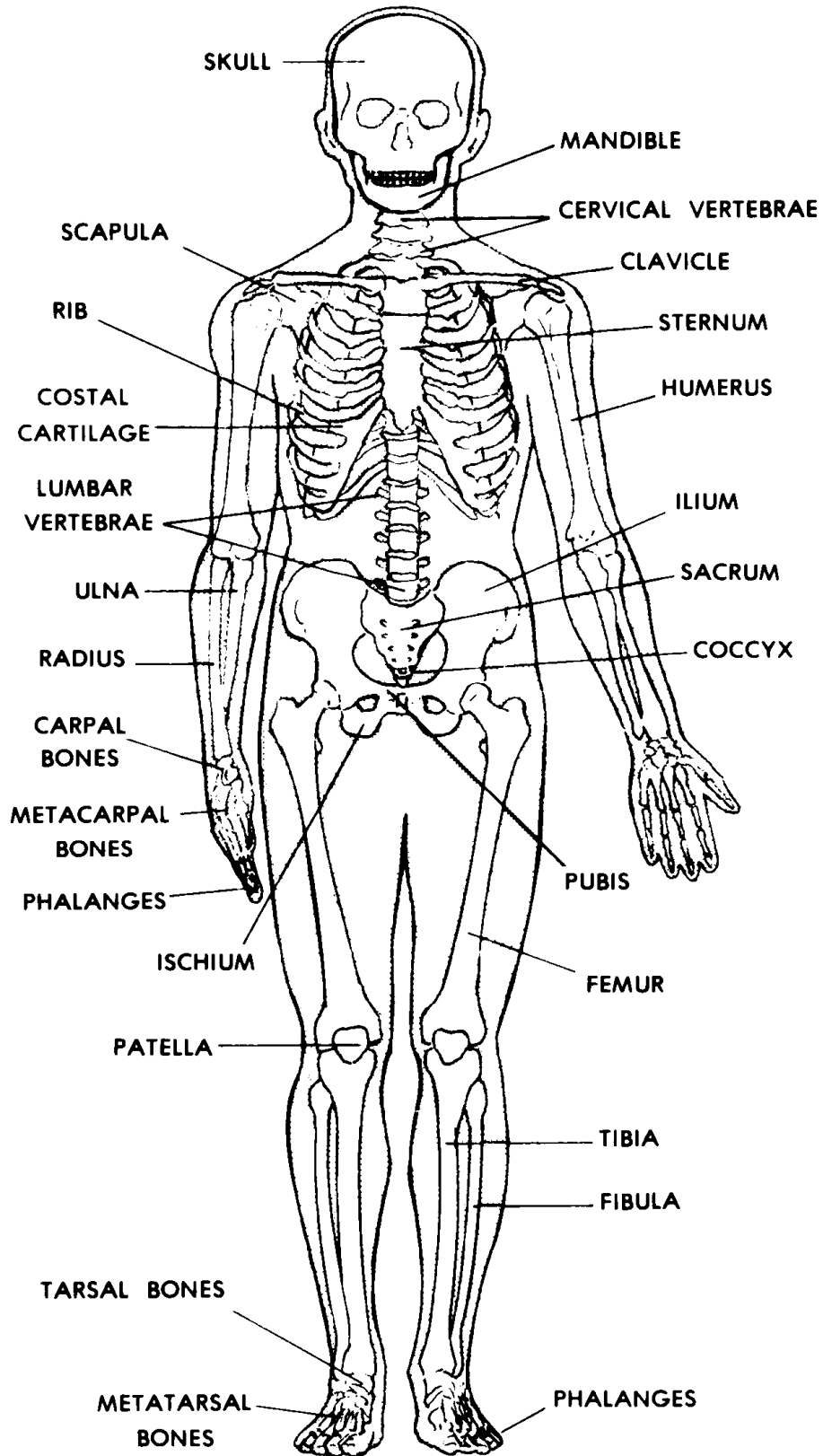


Figure 4-3A. Anterior view of the human skeleton.

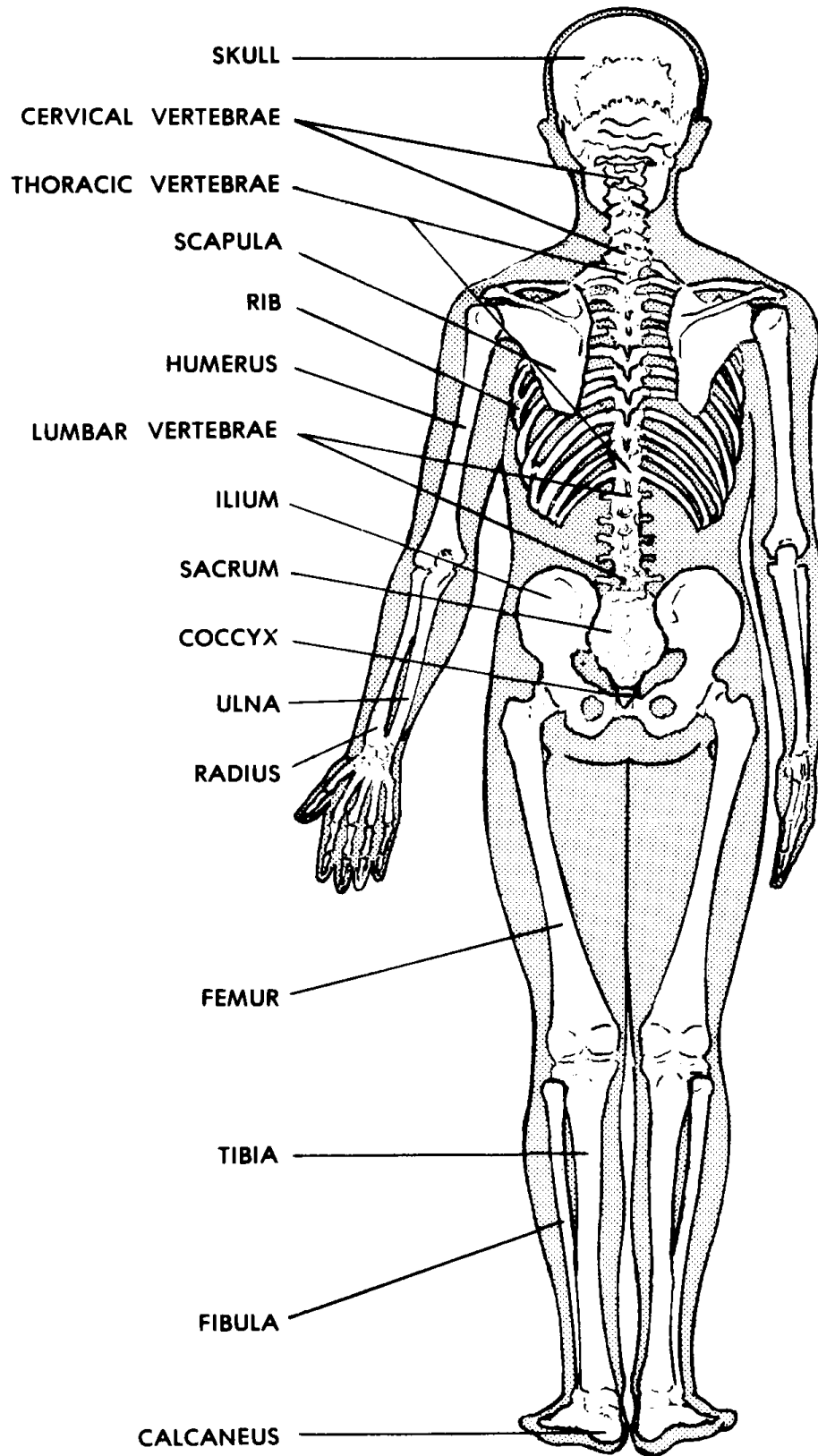


Figure 4-3B. Posterior view of the human skeleton.

a. **Vertebral Column (Spine).** The vertebral column, or spine, is made up of a vertical series of bony blocks called vertebrae. These vertebrae are joined together in such a way as to form a semiflexible rod. The spine is the central support for the trunk, yet allows trunk movements.

(1) Anatomically and functionally, a typical vertebra (figure 4-4) is constructed of two major parts:

(a) The vertebral body is a drum-shaped cylindrical mass. Its superior and inferior surfaces are flat. Its function is primarily weight-bearing.

(b) The neural arch extends posteriorly, arching over and protecting the spinal cord of the central nervous system. From the neural arch are several processes. These processes serve as attachment areas for the trunk muscles. They also act as levers during various trunk motions.

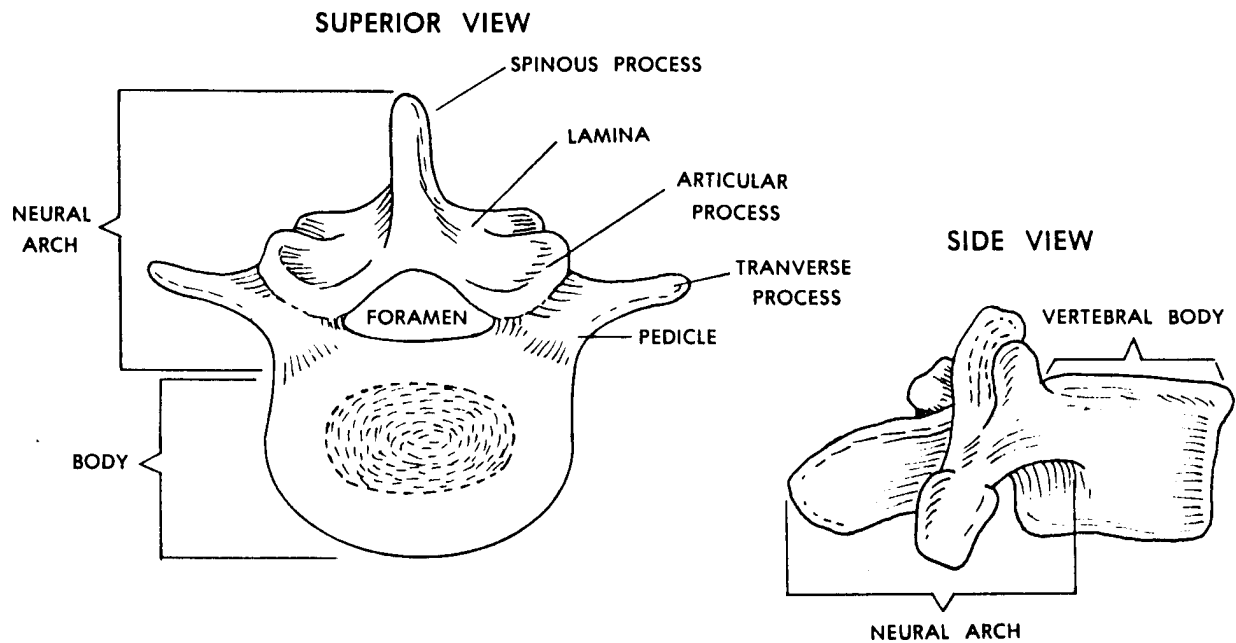


Figure 4-4. A typical vertebra (superior and side views).

(2) The vertebral column has 32-33 vertebrae, one on top of the other. These vertebrae are arranged in regions. The vertebrae of each region have a characteristic shape. The regions are as follows:

- (a) Cervical (neck) region, with seven cervical vertebrae.
- (b) Thoracic (chest) region, with 12 thoracic vertebrae.
- (c) Lumbar (low back) region with five lumbar vertebrae.

(d) The sacrum, which is a bony fusion of five sacral vertebrae.

(e) The coccyx (pronounced COCK-sicks, "tail"), with 3-4 coccygeal vertebrae together.

(3) The vertebrae are held together in two ways:

(a) The intervertebral disc holds the bodies of adjacent vertebrae together. The intervertebral disc is a fibrous ring with a soft center. This disc allows the vertebral bodies to move on one another. This joint between the vertebral bodies is a plane-type joint.

(b) The various parts of adjacent vertebrae are held together by ligaments. A ligament is a dense FCT structure which extends from bone to bone. These ligaments extend along the vertebral column from the base of the skull all the way down to the coccyx.

(4) The spine has four curvatures in the adult human. In the cervical (neck) region and the lumbar (low back) region, the spine curves forward. In the thoracic (chest) region and the sacro-coccygeal (pelvic- sacrum and coccyx) region, the spine curves backwards.

(5) When one examines the back of a person by sight and feel (palpation), certain landmarks are observed.

(a) At the upper shoulder region in the midline, a knob can be seen and felt. This is the tip of the spinous process of the seventh cervical vertebra. Since this is the first vertebra from the top that can be easily palpated, this bony landmark is called the vertebra prominens (the "prominent vertebra").

(b) From the vertebra prominens down to the beginning of the sacrum, one can feel the tip of the spinous process of each vertebra.

b. The Thoracic (Rib) Cage. The rib cage (figure 4-5) forms a protective enclosure for the vital organs contained within the thorax (chest) such as the heart and lungs. It also allows the movements of breathing to take place.

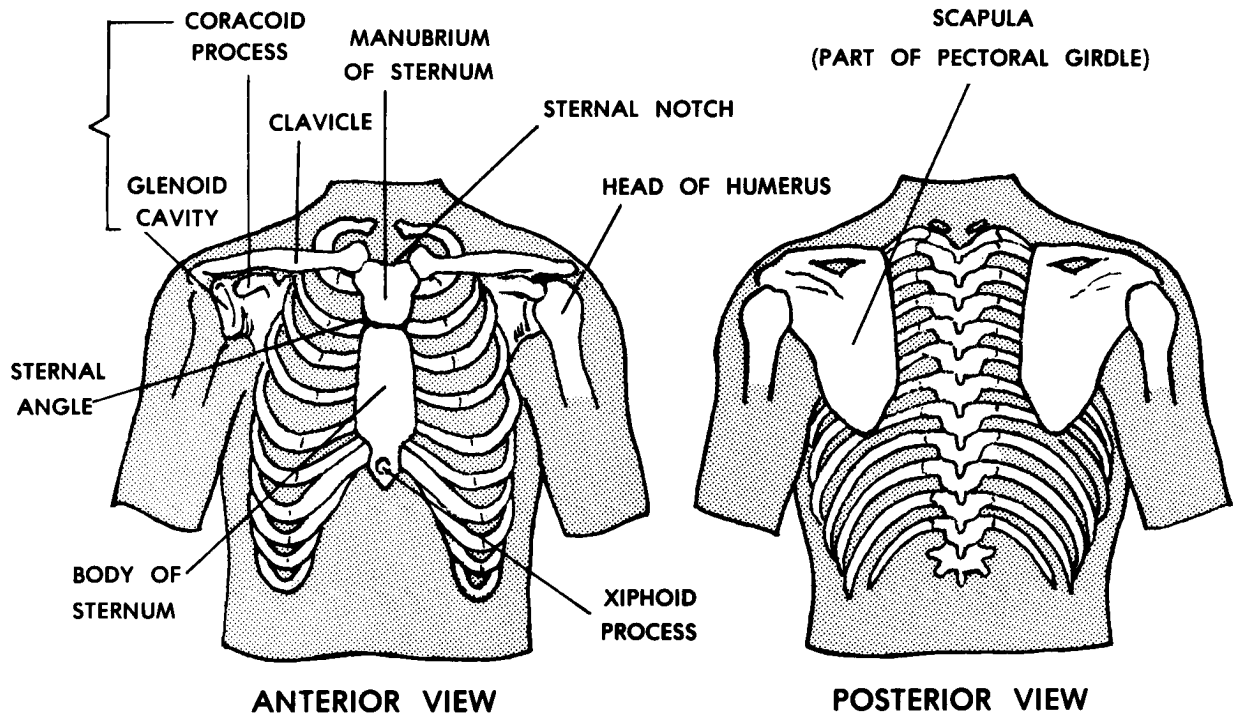


Figure 4-5. The human thorax with bones of the shoulder region.

(1) The sternum lies in the midline of the thorax anteriorly. It is made up of three parts: the manubrium at the top, the body as the main part, and the xiphoid process below. On the top of the manubrium is the jugular (sternal) notch, a common landmark. The junction between the manubrium and the body is a joint called the sternal angle. This sternal angle is an important landmark clinically because the second rib attaches to the sternum at this junction. It is just a matter of simple counting after identifying the second rib to know where you are on the thoracic wall.

(2) The rib cage consists of the 12 thoracic vertebrae, 12 pairs of ribs, and the sternum. Each rib is curved laterally from back to front. All 12 pairs of ribs are attached posteriorly to the thoracic vertebrae. The upper six pairs of ribs are attached directly to the sternum by their costal cartilages. The seventh through tenth pairs of ribs are attached indirectly to the sternum through their costal cartilages (by attaching to the costal cartilage of the rib above). Rib pairs 11 and 12 do not attach to the sternum. Instead, they are embedded in the trunk wall muscles.

c. **The Skull.** The skull (figure 4-6) is the bony framework (skeleton) of the head region. It has two major subdivisions: the cranium which encases and protects the brain and the facial skeleton which is involved with the beginnings of the digestive and respiratory systems. The special sense organs (eyes, ears, etc.) are included and protected within the skull.

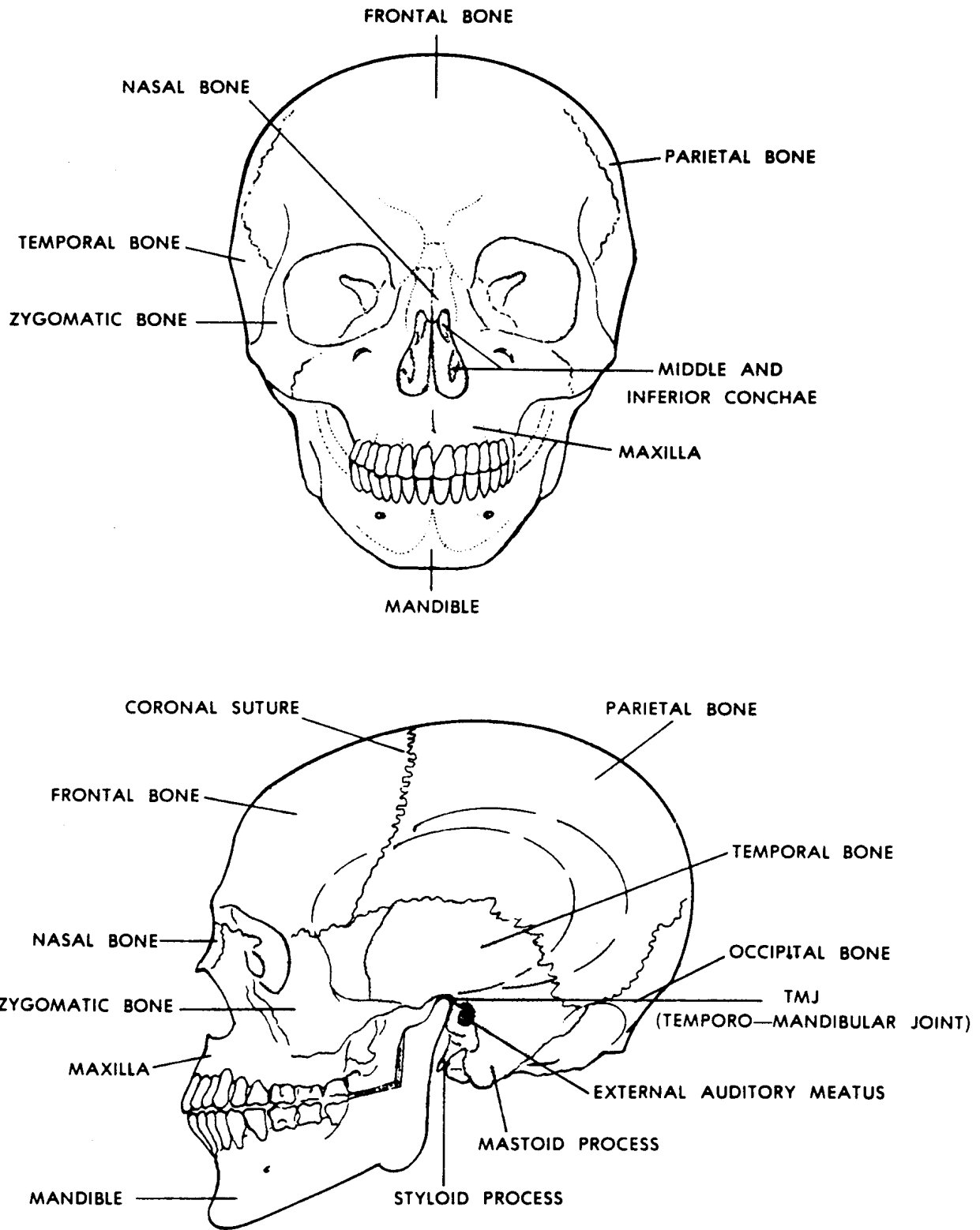


Figure 4-6. The human skull (front and side views).

(1) The bones of the cranium form a spherical case around the brain. With age, the sutures between the cranial bones become more solid. The cranium has a base with several openings for the passage of blood vessels and nerves. The vault (or calvaria) is made up of flat bones arching over and covering the brain.

(2) The facial skeleton consists of bones which surround the nose and the mouth. These are mainly flat and irregular bones. Bones of the facial skeleton also form part of the orbit of each eye.

(3) Certain bones of the skull have air-filled spaces called the paranasal sinuses.

(4) The upper jaw (maxilla) and the lower jaw (mandible) are parts of the facial skeleton which surround the mouth.

(5) The hyoid bone is located at the junction between the head and the neck. It is not articulated directly with the other bones. It is held in place--and moved around--by groups of muscles above and below. The root of the tongue is attached to its upper anterior surface. The larynx is suspended from its inferior surface. These three structures, together, form the hyoid complex. This complex is a functional unit for swallowing.

4-14. THE APPENDICULAR SKELETON

a. The appendicular skeleton is made up of the skeletal elements of the upper and lower members (often incorrectly referred to as the "extremities"). These members are appended (attached) to the axial skeleton.

b. The general pattern of construction of the upper and lower members is the same as follows:

(1) Girdle. The girdle is the actual attaching part. It attaches (appends) the limb (the member less the girdle) to the axial skeleton.

(2) Proximal limb segment. The proximal segment of the limb has a single long bone.

(3) Middle limb segment. The middle segment of the limb has two long bones parallel with each other.

(4) Distal limb segment. The distal segment of the limb is made up of many long and short bones. These bones are arranged into a five-rayed pattern--the digits.

c. See table 4-2 for the main bones of the upper and lower members. [Figures 4-7](#) through [4-13](#) give the main characteristics and details of the bones of the appendicular skeleton.

PART	UPPER MEMBER	LOWER MEMBER
GIRDLE	PECTORAL GIRDLE (CLAVICLE AND SCAPULA)	PELVIC GIRDLE(PELVIC BONE--A FUSION OF ILIUM, PUBIS, AND ISCHIUM)
PROXIMAL SEGMENT	HUMERUS	FEMUR
MIDDLE SEGMENT	RADIUS ULNA	TIBIA FIBULA
DISTAL SEGMENT	CARPUS (8 WRIST BONES) METACARPALS (5) PHALANGES (5 DIGITS)	TARSUS (7 ANKLE BONES) METATARSALS (5) PHALANGES (5 DIGITS)

Table 4-2. Bones of the upper and lower members.

Continue with Exercises

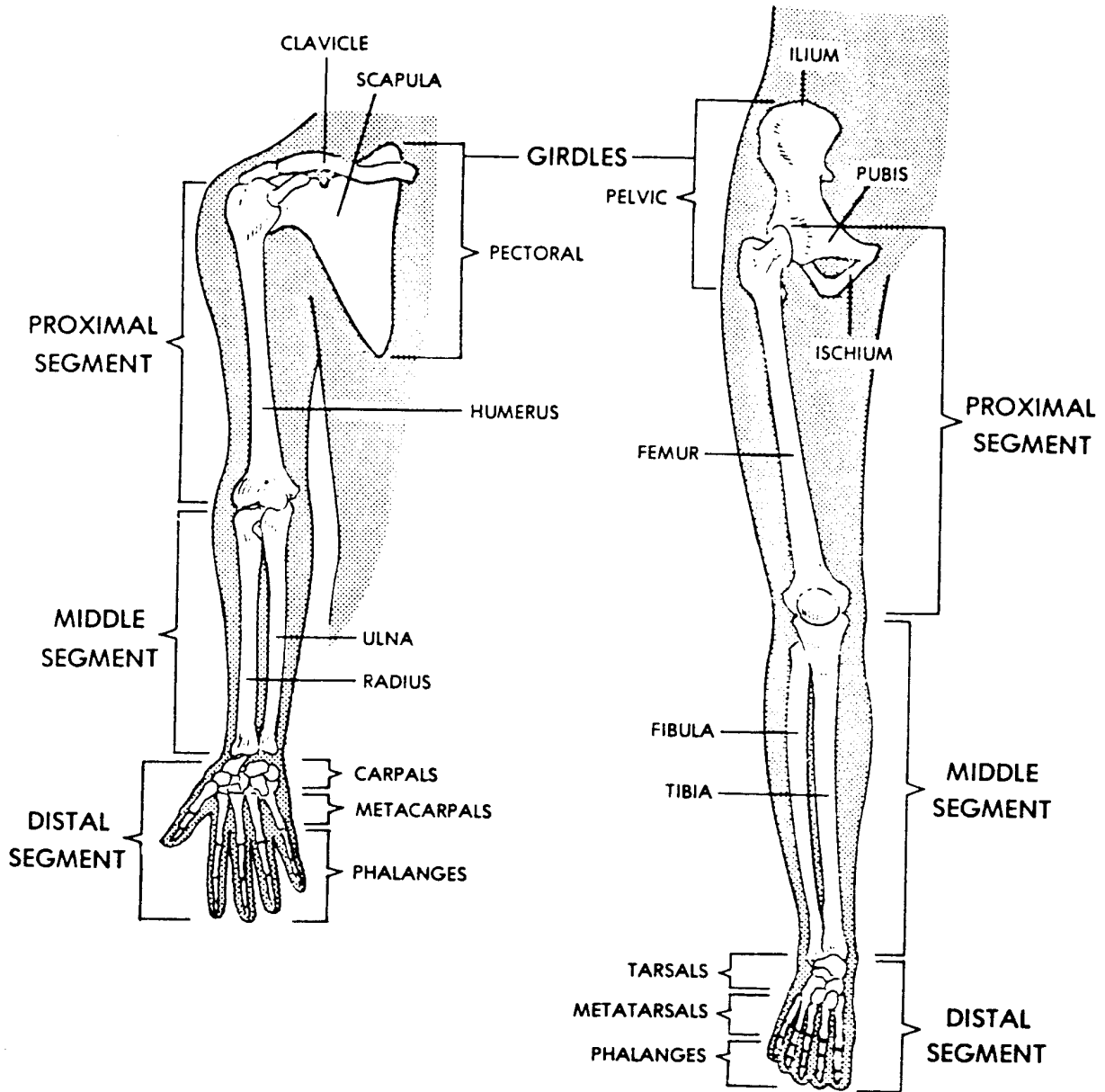


Figure 4-7. A general pattern of the upper and lower members.

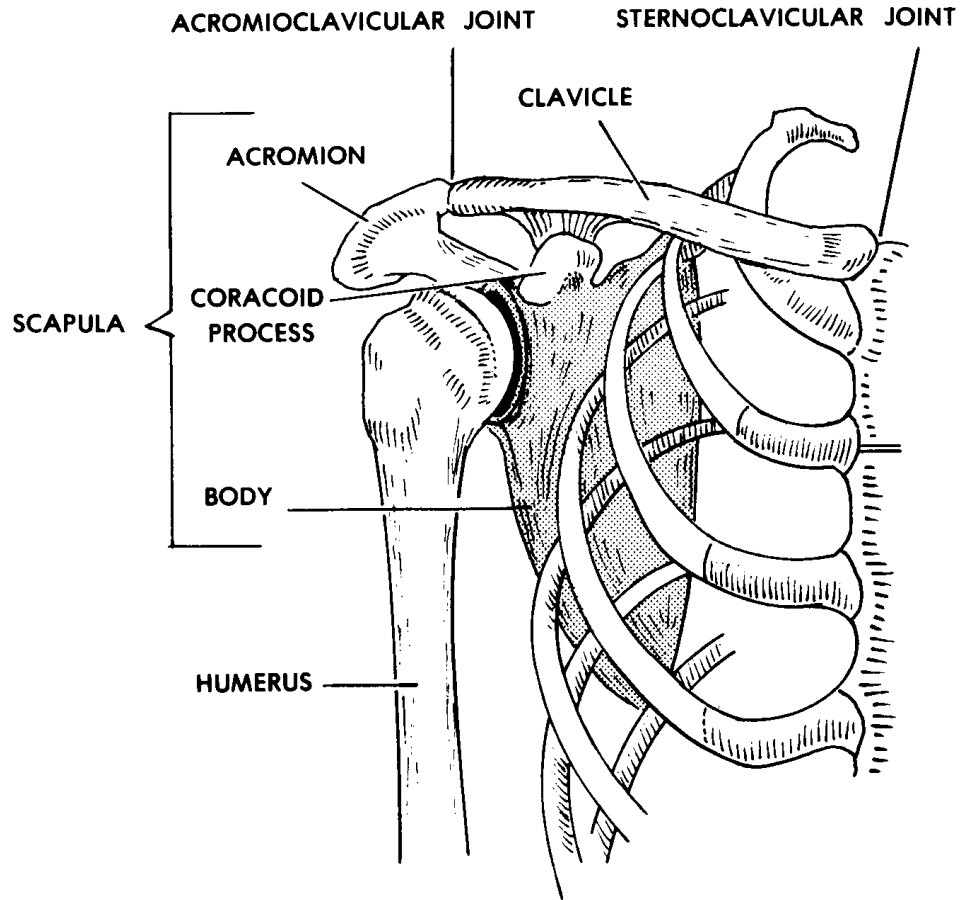


Figure 4-8. The human scapula and clavicle (pectoral girdle).

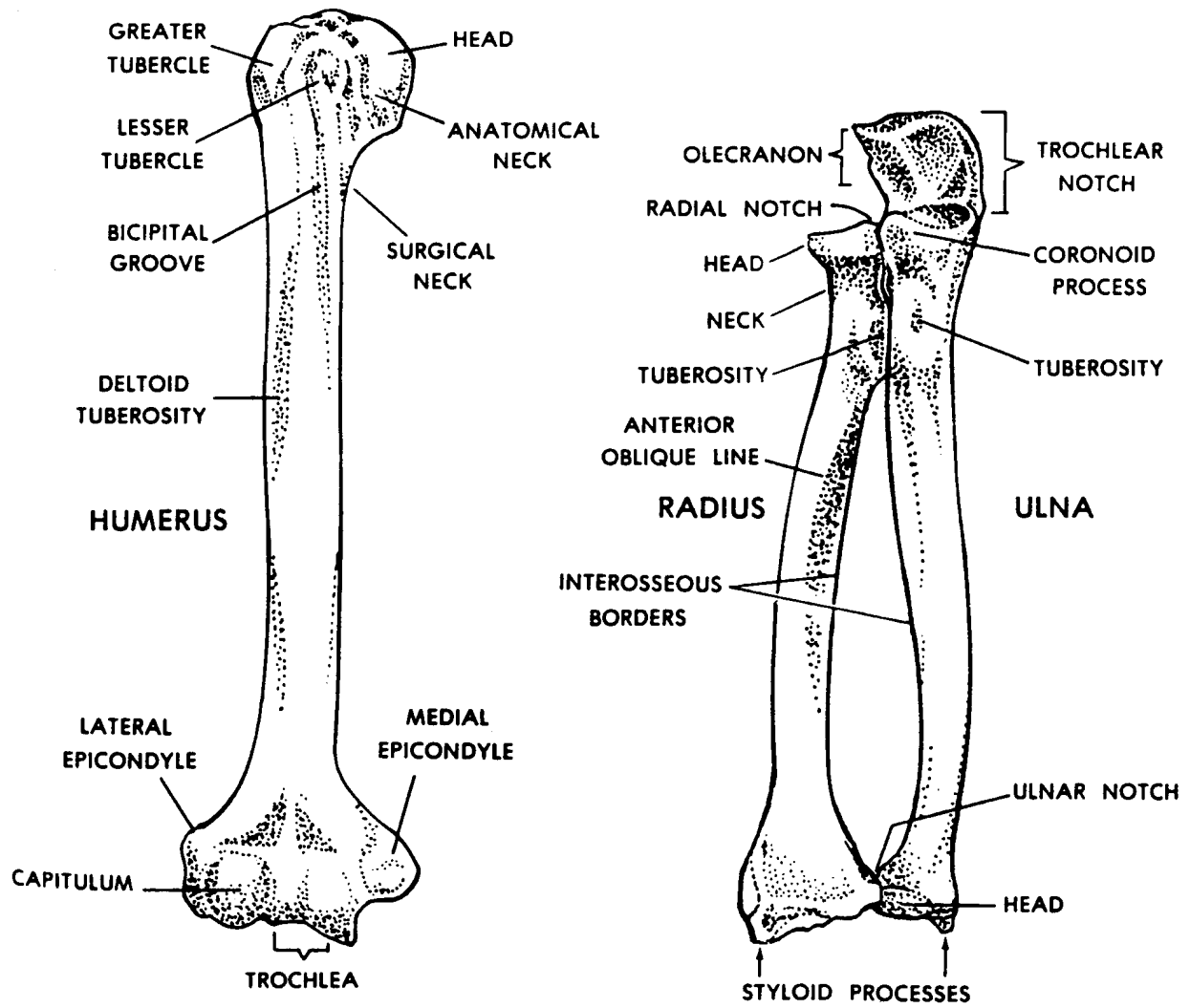


Figure 4-9. The humerus, radius, and ulna.

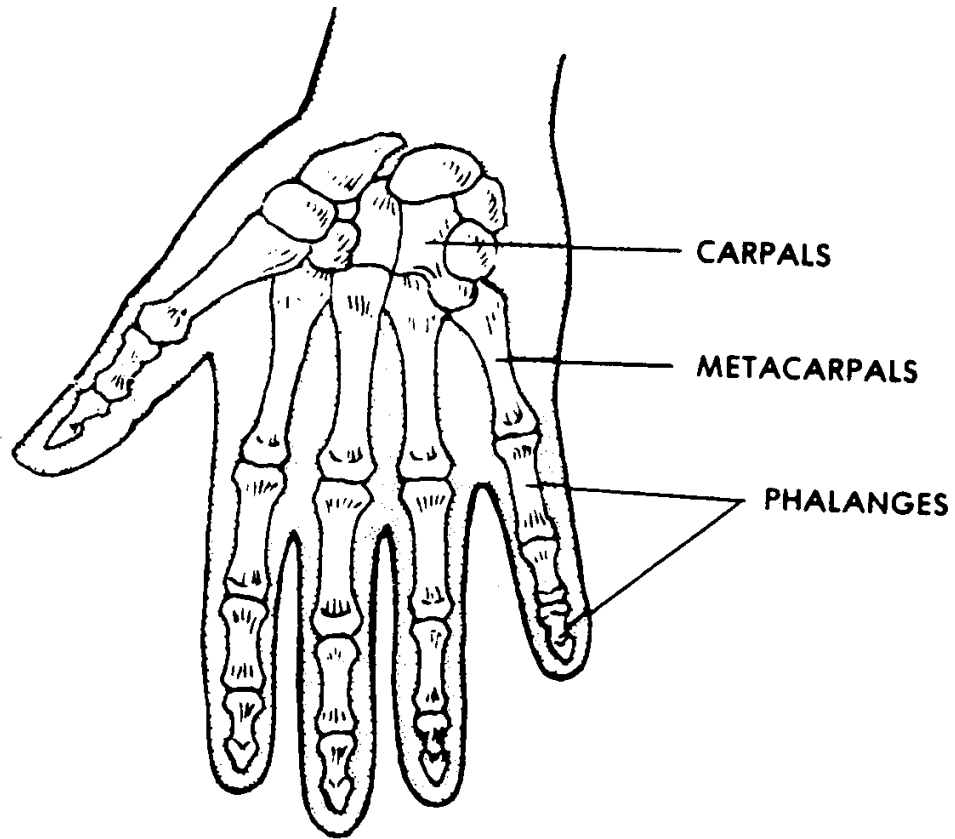


Figure 4-10. The human hand.

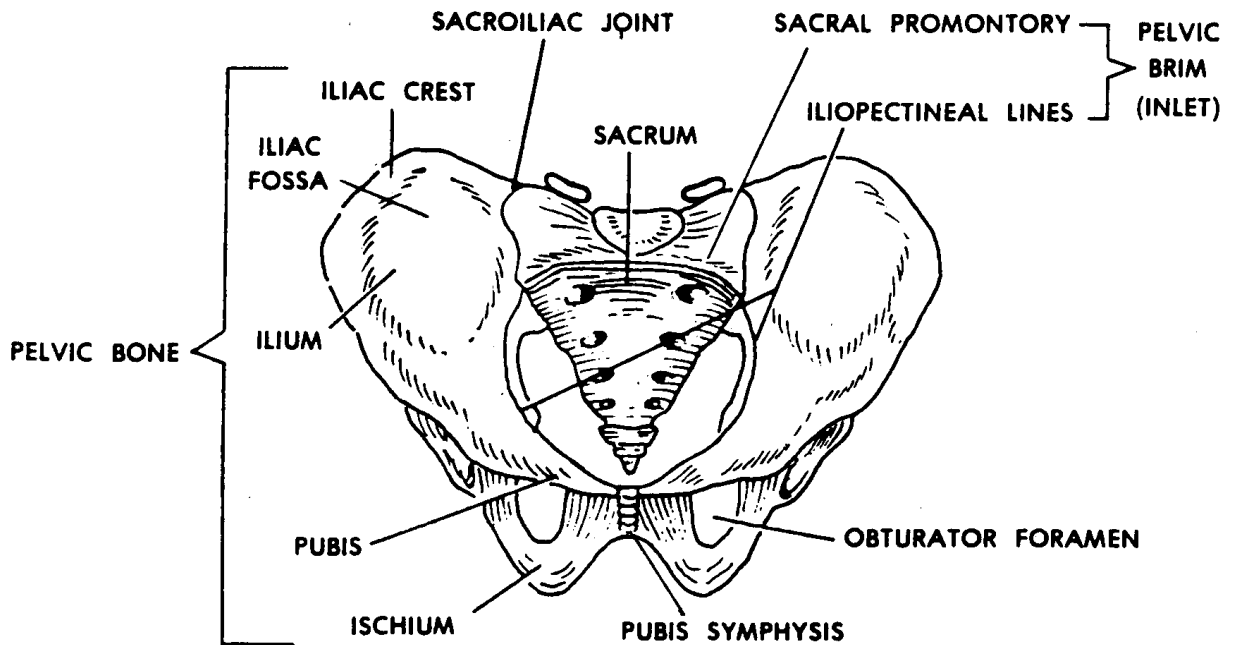


Figure 4-11. The bony pelvis (two pelvic bones and sacrum).

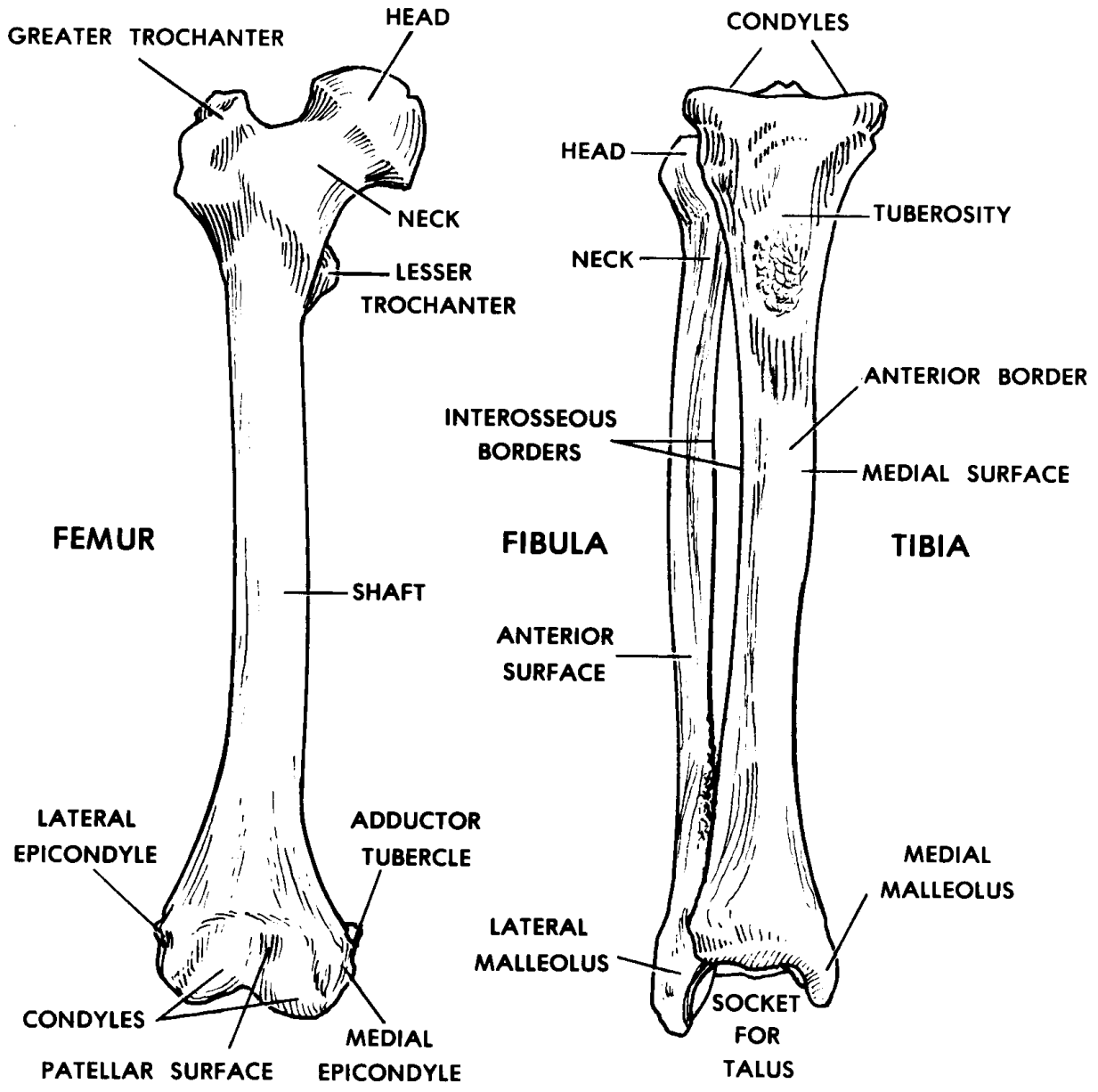


Figure 4-12. The femur, tibia, and fibula (anterior views).

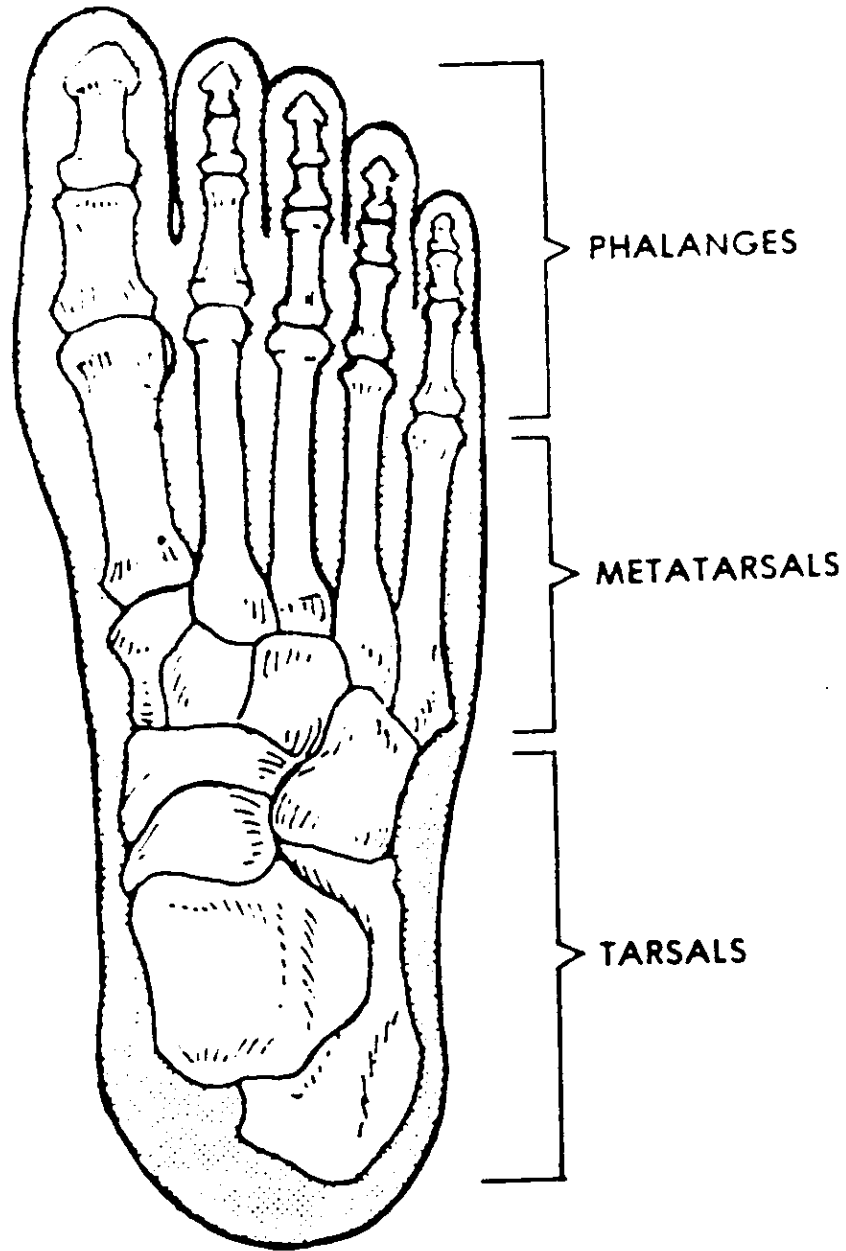


Figure 4-13. The human foot.

EXERCISES, LESSON 4

REQUIREMENT. The following exercises are to be answered by completing the incomplete statement or by writing the answer in the space provided at the end of the question.

After you have completed all the exercises, turn to "Solutions to Exercises," at the end of the lesson and check your answers.

1. What is a skeleton?

2. What are four functions of the human skeleton?
 - a. _____.
 - b. _____.
 - c. _____.
 - d. _____.

3. An individual bone consists of the outer _____ and the inner _____.

4. The two types of bone marrow are _____ and _____ bone marrow. Yellow bone marrow is mostly yellow _____ tissue. Red bone marrow is the only site in adults for the formation of _____.

5. The parts and portions of an individual long bone are the s____(d____s) and the _____ (e____s). The shaft is the _____ portion of the long bone. The ends are made up mainly of c____(s____) bone tissue. An articular cartilage covers each area where a bone _____s another bone.

6. The periosteum is a covering of bone surface area not covered by _____. The innermost layer is the o____(b____-f____) layer. The outermost layer is an _____layer.

7. In the early fetus, bones are preformed as _____s bones and _____e bones which have the shape and location of the _____t bones. Developing long bones have growing masses of actual bone called _____ centers. These centers are located in the _____ and in each _____. Preparing material surrounding these centers is destroyed and replaced with _____ tissue. A bone grows in width through the activity of the _____ layer of the _____.

8. What are four types of bones according to shape?

a. _____.

b. _____.

c. _____.

d. _____.

9. What is a syndesmosis?

10. What is a suture?

11. What is a synostosis?

12. What is a synchondrosis?

13. What is a symphysis?

14. What is a synovial joint?

15. What are the major parts of a "typical" synovial joint?

- a. B_____.
- b. Articular c_____.
- c. (1) Synovial m_____.
- (2) Synovial s_____.
- (3) Synovial f_____.
- d. C_____.
- e. L_____.
- f. M_____.

16. Name and describe three classifications of synovial joints. Along with each, name common subclassifications.

- a. U_____.
- (1) Hi_____.
- (2) Pi_____.
- b. B_____.
- Sa_____.
- c. M_____.
- (1) Ba_____.
- (2) Pl_____.

17. Name and define the two major subdivisions of the skeleton.

a. _____ skeleton--the _____ of the human body--including the _____, _____ column, and _____.

b. _____ skeleton--skeletal elements of the upper and _____.

18. Name and describe the two major parts of a typical vertebra.

a. Vertebral _____--_____ -shape cylinder. Its function is to _____.

b. _____ arch--arch over posterior of the _____. The arch has several _____. The _____ are sites of attachment of _____ and act as _____ for trunk motions.

19. Name the regions of the vertebral column and give the number of vertebrae in each region.

a. _____ (neck) region, _____.

b. _____ (chest) region, _____.

c. _____ (low back) region, _____.

d. _____, fusion of _____.

e. _____ ("tail"), _____ - _____ together.

20. Describe the two ways that vertebrae are held together.

a. Intervertebral discs:

b. Ligaments:

21. The thoracic cage consists of the s_____ (m_____, b_____, and x_____ p_____), 12 pairs of _____, and 12 t_____v_____. The thoracic cage provides p_____ for v_____ o_____ within the t_____. It also allows the m_____ of breathing.

22. What are the two major subdivisions of the skull and with which organs or systems is each subdivision involved?

a. _____: Encases and protects_____.

b. _____: Involved with beginning of _____; encases and protects the_____.

23. In the first column below, name a general segment or part of a member. In the second column, name bones or bone groups which are found in each segment of the upper member. In the third column, name bones or bone groups which are found in each segment of the lower member.

	<u>PART</u>	<u>UPPER MEMBER</u>	<u>LOWER MEMBER</u>
a.	G_____	_____GIRDLE	_____GIRDLE
b.	P_____ SEGMENT	_____S	_____R
c.	M_____ SEGMENT	_____S, _____A	_____A, _____A
d.	D_____ SEGMENT	C_____, M_____, P_____	T_____, M_____, P_____

Check Your Answers on Next Page

SOLUTIONS TO EXERCISES, LESSON 4

1. The skeleton is a combination of bones joined together that serves as a support or framework of the human body. (para 4-1)
2. The four functions of the human skeleton are:
 - a. Bodily support.
 - b. Protection.
 - c. Motion.
 - d. Formation of blood cells. (para 4-2)
3. An individual bone consists of the outer cortex and the inner medulla. (para 4-4a)
4. The two types of bone marrow are red bone marrow and yellow bone marrow. Yellow bone marrow is mostly yellow fat tissue. Red bone marrow is the only site in adults for the formation of red blood cells. (para 4-4b)
5. The parts or portions of an individual long bone are the shaft (diaphysis) and the ends (epiphyses). The shaft is the central portion of the long bone. The ends are made up mainly of cancellous (spongy) bone tissue. An articular or cartilage covers each area where a bone contacts another bone. (para 4-4c)
6. The periosteum is a covering of bone surface area not covered by articular cartilage. The innermost layer is the osteogenic (bone-forming) layer. The outermost layer is an FCT layer. (para 4-4d)
7. In the early fetus, bones are "preformed" as membranous bones and cartilage bones which have the shape and location of the adult bones. Developing long bones have growing masses of actual bone called ossification centers. These centers are located in the shaft and in each end. Preforming material surrounding these centers is destroyed and replaced with bony tissue. A bone grows in width through the activity of the osteogenic layer of the periosteum. (paras 4-5a, c, d)
8. Four types of bones according to shape are:
 - a. Long bones.
 - b. Short bones.
 - c. Flat bones.
 - d. Irregular bones. (para 4-6)
9. A syndesmosis is a joint in which the bones are held together by FCT (fibrous connective tissue). (para 4-8a(1))
10. A suture is a joint in which the bones are very close together with a minimum of FCT. (para 4-8a(2))

11. A synostosis is a joint in which the bones are united by bony material. (para 4-8b)

12. A synchondrosis is a joint in which the bones are held together by hyaline cartilage. (para 4-8c(1))

13. A symphysis is a joint in which the bones are held together by a disc of fibrocartilage. (para 4-8c(2))

14. A synovial joint is a joint in which the bones are able to move freely upon one another. (para 4-8d)

15. The major parts of a synovial joint are:

- a. Bones.
- b. Articular cartilages.
- c. (1) Synovial membrane.
(2) Synovial space.
(3) Synovial fluid.
- d. Capsule.
- e. Ligaments.
- f. Muscles. (para 4-9)

16. Synovial joints may be classified as follows:

- a. Uni-axial--motion in one plane.
(1) Hinge joint.
(2) Pivot joint.
- b. Bi-axial--motion in two planes.
Saddle joint.
- c. Multi-axial--motion in all three planes.
(1) Ball-and-socket joint.
(2) Plane joint. (para 4-10)

17. The major subdivisions of the skeleton are the:

- a. Axial skeleton--the central framework of the human body--including the skull, vertebral column, and thoracic cage.
- b. Appendicular skeleton--skeletal elements of the upper and lower members. (paras 4-12, 4-13, 4-14)

18. The two major parts of a typical vertebra are the:

- a. Vertebral body--drum-shape cylinder. Its function is to bear weight.
- b. Neural arch--arch over posterior of the spinal cord. The neural arch has several processes. The processes are sites for attachment of trunk muscles and act as levers for trunk motions. (para 4-13a(1))

19. The regions of the vertebral column and the number of vertebrae in each are as follows:

- a. Cervical (neck) region, 7.
- b. Thoracic (chest) region, 12.
- c. Lumbar (low back) region, 5.
- d. Sacrum, fusion of 5.
- e. Coccyx ("tail"), 3-4 together. (para 4-13a(2))

20. a. Intervertebral discs hold the bodies of adjacent vertebrae together, are fibrous rings with soft centers, allow adjacent vertebral bodies to move on one another, and are part of plane-type joints between vertebrae.

b. Ligaments are dense FCT structures extending from bone to bone (along the vertebral column from the base of the skull to the coccyx). (para 4-13a(3))

21. The thoracic (rib) cage consists of the sternum (manubrium, body, and xiphoid process), 12 pairs of ribs, and 12 thoracic vertebrae. The thoracic cage provides protection for vital organs within the thorax. It also allows the movements of breathing. (para 4-13b)

22. The two major subdivisions of the skull are as follows:

- a. Cranium: Encases and protects brain.
- b. Facial skeleton: Involved with beginning of digestive and respiratory tracts; encases and protects the special sense organs (eyes, ears, etc.). (para 4-13c)

23.	<u>PART</u>	<u>UPPER MEMBER</u>	<u>LOWER MEMBER</u>
a.	<u>GIRDLE</u>	<u>PECTORAL GIRDLE</u>	<u>PELVIC GIRDLE</u>
b.	<u>PROXIMAL SEGMENT</u>	<u>HUMERUS</u>	<u>FEMUR</u>
c.	<u>MIDDLE SEGMENT</u>	<u>RADIUS,</u> <u>ULNA</u>	<u>TIBIA,</u> <u>FIBULA</u>
d.	<u>DISTAL SEGMENT</u>	<u>CARPUS,</u> <u>METACARPALS,</u> <u>PHALANGES</u>	<u>TARSUS,</u> <u>METATARSALS,</u> <u>PHALANGES</u>

(table 4-2)

End of Lesson 4

LESSON ASSIGNMENT

LESSON 5

The Human Muscular System.

TEXT ASSIGNMENT

Paragraphs 5-1 through 5-8.

LESSON OBJECTIVES

After completing this lesson, you should be able to:

- 5-1. Describe the general features of the skeletal muscles.
- 5-2. Describe the general arrangement of the trunk and limb musculature.
- 5-3. Given a sample drawing, identify the class of lever.
- 5-4. Name the components of a skeleto-muscular unit. Given a description of a muscle's role in a motion, name that role.

SUGGESTION

After completing the assignment, complete the exercises at the end of this lesson. These exercises will help you to achieve the lesson objectives.

LESSON 5

THE HUMAN MUSCULAR SYSTEM

Section I. THE SKELETAL MUSCLE

5-1. MUSCLE TISSUES

The cellular elements of muscle tissues are specialized to produce motion by contraction. They also produce body heat. (See [paragraphs 2-14](#) and 2-15 of lesson 2 for a discussion of muscle tissues.)

- a. Smooth muscle tissue is utilized to make up the muscular portion of the various visceral organs (stomach, blood vessels, etc.).
- b. Cardiac muscle tissue makes up the muscular wall of the heart--the myocardium.
- c. Striated muscle tissue is used in the makeup of several types of muscles. The main type of muscle is the skeletal muscle. Other types of muscles made with striated muscle tissue are the facial or integumentary muscles and muscles of the jaw apparatus.

5-2. THE SKELETAL MUSCLE

Each skeletal muscle is an individual organ of the human body. Each is made up of several types of tissues--mainly, striated muscle fibers and FCT (fibrous connective tissue). Each is attached to and moves bones. Bones are parts of the skeleton serving as levers.

a. **General Construction of a Skeletal Muscle.** The large portion of a muscle is known as its belly or fleshy belly. This muscle is attached to bones by tendons or aponeuroses. Tendons and aponeuroses are similar to each other. However, tendons are cord-like and aponeuroses are broad and flat. The fleshy portion may be directly connected to the bone. If so, it is called a "fleshy attachment."

b. **Muscular NAVL (Nerves, Arteries, Veins, Lymphatics).**

(1) From the main NAVL (nerve, artery, vein, lymphatic), there are branches going to each muscle. These muscular branches are bound together by an FCT sheath to form a neurovascular bundle.

(2) The motor point is that specific location on the surface of the muscle where the neurovascular bundle enters.

(3) A motor unit is the single motor neuron and the number of striated muscle fibers activated by it (innervation). The importance of the motor unit is that its fibers work in unison. Either all fibers within a unit contract or none contract. When a certain amount of force is needed, one unit after another is recruited until just enough units are available to produce the desired action.

5-3. NAMING SKELETAL MUSCLES

The name of a muscle may appear with the abbreviation M., meaning Musculus or muscle. We abbreviate muscles (plural) with the symbol Mm. Skeletal muscles are named according to their physical attributes (shape, size, length, etc.), their location, or their function. For example:

SHAPE:	deltoid M. DELTA = Δ , Greek letter D
	biceps M. BICEPS = two-head BI = two CEPS = head
SIZE:	adductor magnus M. MAGNUS = great, large
LENGTH:	adductor longus M. LONGUS = long
LOCATION:	biceps brachii M. BRACHII = of the arm
	biceps femoris M. FEMORIS = of the thigh
FUNCTION:	rotatores Mm. ROTATORES = rotators (They turn/rotate the vertebral column.)

5-4. ARRANGEMENT OF HUMAN SKELETAL MUSCLES

See figures 5-1 and 5-2 for some of the skeletal muscles.

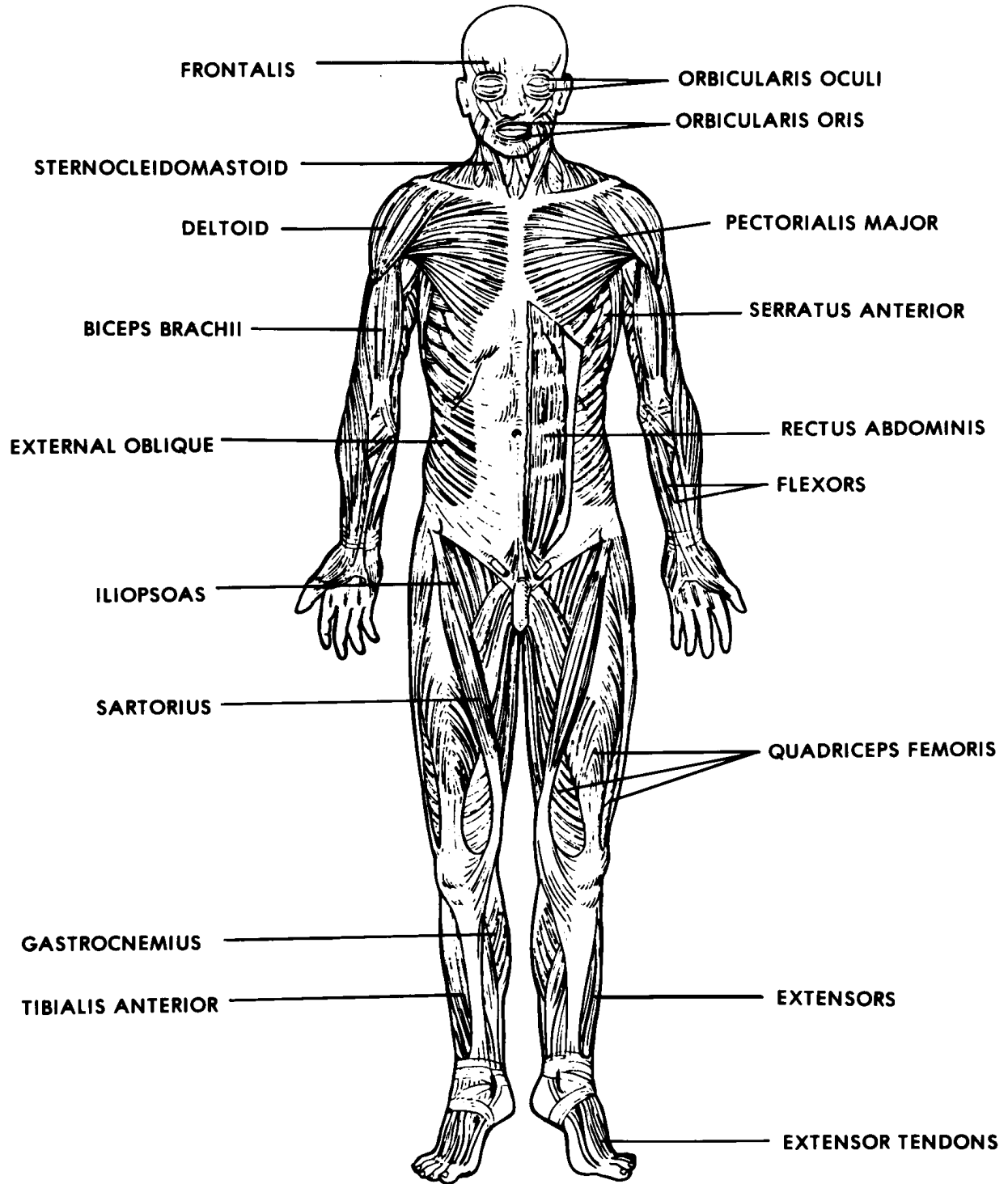


Figure 5-1. Skeletal and facial muscles, anterior view.

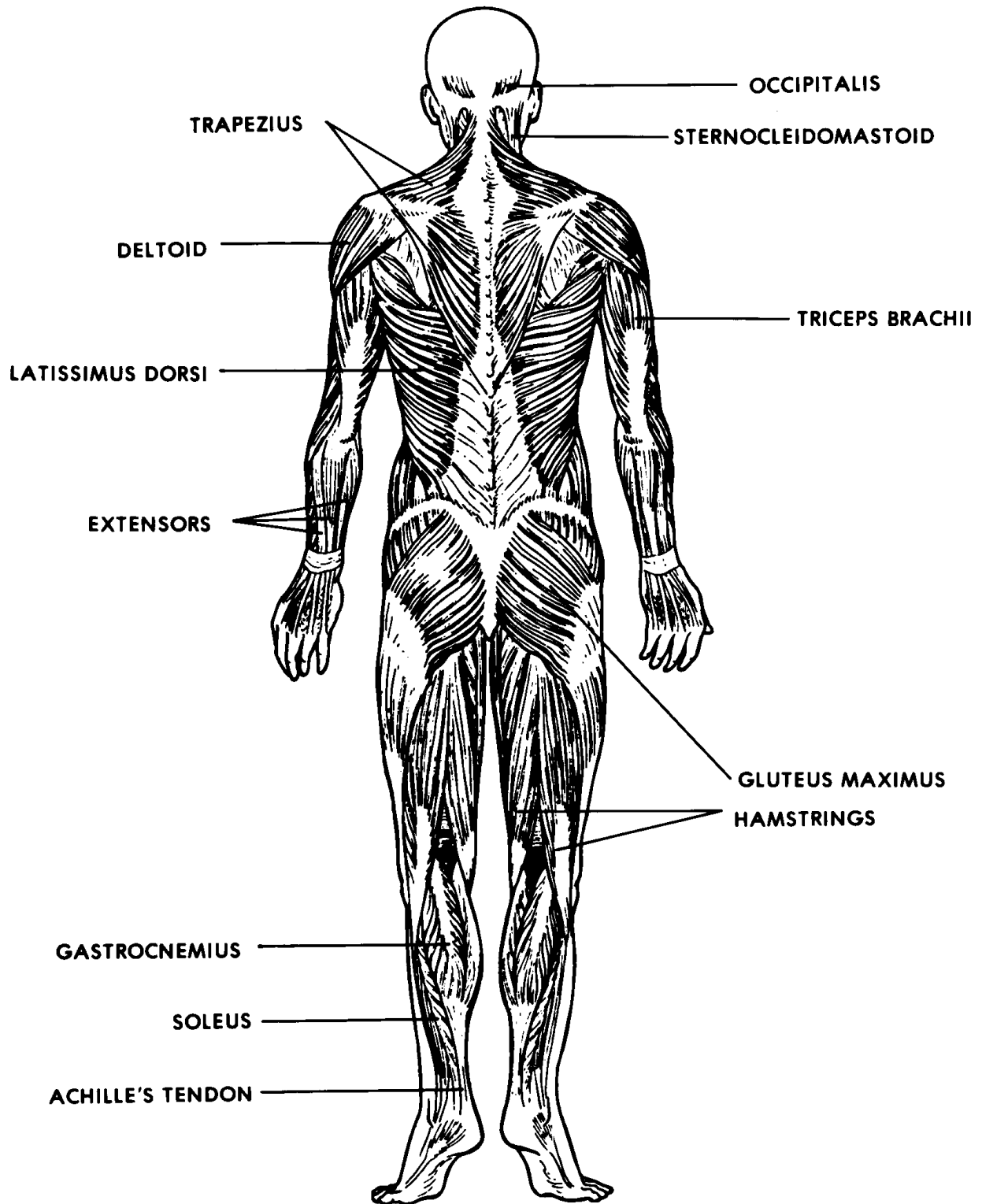


Figure 5-2. Skeletal and facial muscles, posterior view.

a. **Trunk Musculature.** The trunk musculature is arranged in two ways--longitudinal muscles and oblique muscles. Together, they:

- (1) Maintain trunk posture.
- (2) Move the parts of the trunk.
- (3) Adjust the internal pressures of the trunk to perform certain functions such as breathing.

b. **Limb Musculature.** The limb musculature is arranged around the joints to produce the appropriate motions of the limbs. Elementary mechanics are described in the next section to help you to understand typical arrangements of limb musculature.

Section II. SOME ELEMENTARY SKELETO-MUSCULAR MECHANICS

5-5. GENERAL

Muscles and bones together work like machines within the laws of physics and chemistry. Lever and pulley systems are examples of simple machines found commonly in the human body.

5-6. LEVER SYSTEMS

See figure 5-3 for an illustration of the three classes of levers.

a. **First Class.** In a first class lever, the weight to be moved is at one end of the lever, the applied force is at the other end, and the fulcrum (the pivot or turning point) is between the two.

b. **Second Class.** In a second class lever, the weight to be moved is between the applied force and the fulcrum. This type of lever enables a weight to be moved with less force than would be required without a lever. (Many feel that there are no second class levers in the human body.)

c. **Third Class.** In a third class lever, the weight to be moved is at one end of the lever, the fulcrum is at the other end, and the applied force is between the weight and the fulcrum. This type of lever provides speed, but a greater amount of force is required for a given weight. This is the most common type of lever in the human body.

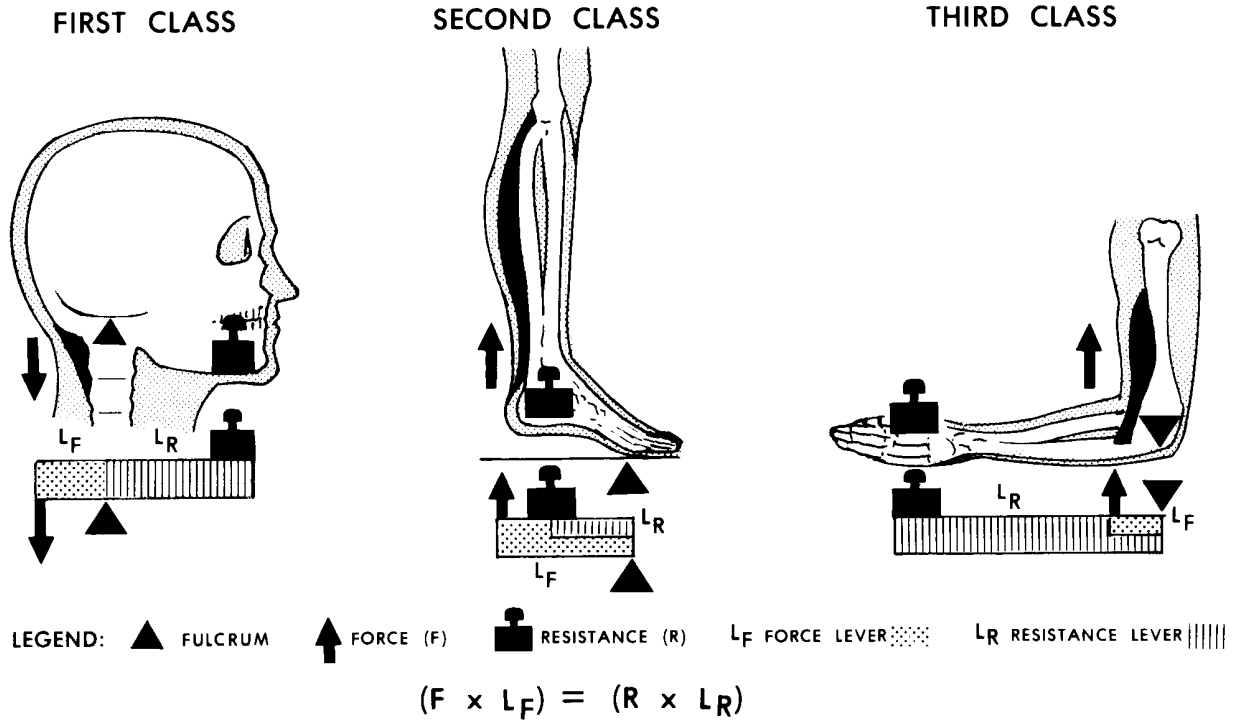


Figure 5-3. Types of lever systems.

5-7. SIMPLE PULLEY SYSTEM

a. In the human body when the tendon of a skeletal muscle slides over a round bony surface, the "system" acts like a simple pulley (figure 5-4). A simple pulley provides a change in the direction of the force or muscle pull. There is no change in the amount of force produced by the muscle. For example, the knee acts as a simple pulley by which the quadriceps femoris M. extends the leg.

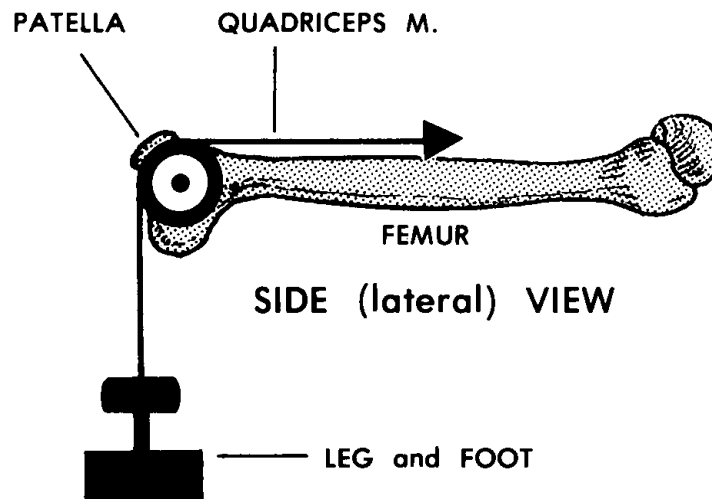


Figure 5-4. A simple pulley (the human knee mechanism).

b. Sesamoid bones, such as the patella (kneecap), develop in tendons where pressure is applied to the tendon.

5-8. THE SKELETO-MUSCULAR UNIT

The skeleto-muscular unit (figure 5-5) is a working concept of muscle and skeleton producing motion. The components of an S-M unit are bones, a joint, and skeletal muscle(s).

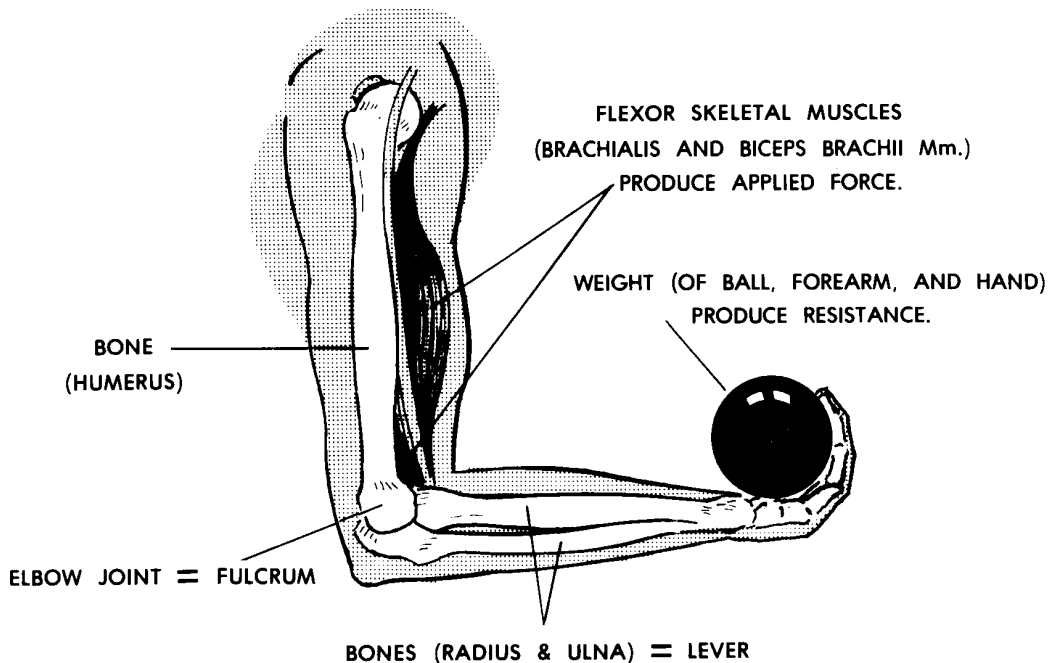


Figure 5-5. The skeleto-muscular unit (arm-forearm flexion (3rd class lever system)).

- a. **Bones.** Bones act as levers and as attachment sites for skeletal muscles.
- b. **Joint (Articulation).** The joint is the center, fulcrum, point, or axis of motion.
- c. **Skeletal Muscle(s).** Skeletal muscles apply the forces for motion. Any given motion utilizes a group of muscles working together. A skeletal muscle may serve only one of the three following major roles during a particular motion:
 - (1) Prime mover. The muscle which makes the main effort for a given motion is called the prime mover, or agonist.
 - (2) Synergist. A synergist is a muscle which assists the prime mover.

SYN = together
ERG = unit of effort

- (3) Antagonist. An antagonist applies a force opposite to that of the prime mover.
- (a) By opposing the prime mover, the antagonist helps control the motion.
- (b) The antagonist also brings the limb or other part back to its original position.

Continue with Exercises

EXERCISES, LESSON 5

REQUIREMENT. The following exercises are to be answered by completing the incomplete statements or by writing the answer in the space provided at the end of the question.

After you have completed all the exercises, turn to "Solutions to Exercises," at the end of the lesson and check your answers.

1. The main types of tissues in skeletal muscles are _____ and _____.

2. The large portion of a skeletal muscle is known as its _____ or its _____. Generally, a skeletal muscle is attached to bone by a _____ or _____. If the fleshy portion is directly connected to the bone, it is called a _____.

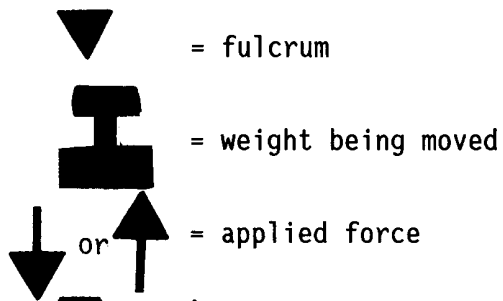
3. What is a neurovascular bundle?

What is a motor point?

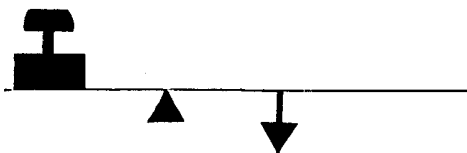
What is a motor unit?


4. The trunk musculature is arranged in two ways--_____muscles and _____muscles. The limb musculature is arranged around the _____ to provide the appropriate motions of the _____.

5. Label the drawings below according to class of lever.



a.  _____ class

b.  _____ class

c.  _____ class

6. The components of a skeleto-muscular unit are:

a. _____.

b. _____.

c. _____.

7. The muscle which makes the main effort for a given motion is called the _____. A muscle which assists the first is called a _____. A muscle which applies a force opposite to that of the first is called an _____.

Check Your Answers on Next Page

SOLUTIONS TO EXERCISES, LESSON 5

1. The main types of tissues in skeletal muscles are striated muscle fibers and fibrous connective tissue. (para 5-2)
2. The large portion of skeletal muscle is known as its belly or fleshy belly. Generally, a skeletal muscle is attached to bone by a tendon or aponeurosis. If the fleshy portion is directly connected to the bone, it is called a fleshy attachment. (para 5-2a)
3. A neurovascular bundle is a branch from the main NAVL, sheathed in fibrous connective tissue. The motor point is the specific location on the surface of the muscle where the neurovascular bundle enters. A motor unit is a single motor neuron and the striated muscle fibers activated by the neuron. All fibers of a motor unit contract or none contract. (para 5-2b)
4. The trunk musculature is arranged in two ways--longitudinal muscles and oblique muscles. The limb musculature is arranged around the joints to produce the appropriate motions of the limbs. (para 5-4)
5.
 - a. Third class.
 - b. First class.
 - c. Second class. (para 5-6; figure 5-3)
6. The components of a skeleto-muscular unit are:
 - a. Bones.
 - b. Joint (articulation).
 - c. Skeletal muscles. (para 5-8)
7. The muscle which makes the main effort for a given motion is called the prime mover (agonist). A muscle which assists the first is called a synergist. A muscle which applies a force opposite to that of the first is called an antagonist. (para 5-8c)

End of Lesson 5

LESSON ASSIGNMENT

LESSON 6

The Human Digestive System.

TEXT ASSIGNMENT

Paragraphs 6-1 through 6-16.

LESSON OBJECTIVES

After completing this lesson, you should be able to:

- 6-1. Define the human digestive system.
- 6-2. Name six major organs of the human digestive system.
- 6-3. Name and describe six structures of the oral complex.
- 6-4. Describe the pharynx, the esophagus, the stomach, the small intestines, the liver and gallbladder, the pancreas, and the large intestines.

SUGGESTION

After completing the assignment, complete the exercises at the end of this lesson. These exercises will help you to achieve the lesson objectives.

LESSON 6

THE HUMAN DIGESTIVE SYSTEM

Section I. INTRODUCTION

6-1. GENERAL

a. **Definition.** The human digestive system is a group of organs designed to take in foods, initially process foods, digest the foods, and eliminate unused materials of food items. It is a hollow tubular system from one end of the body to the other end. See figure 6-1.

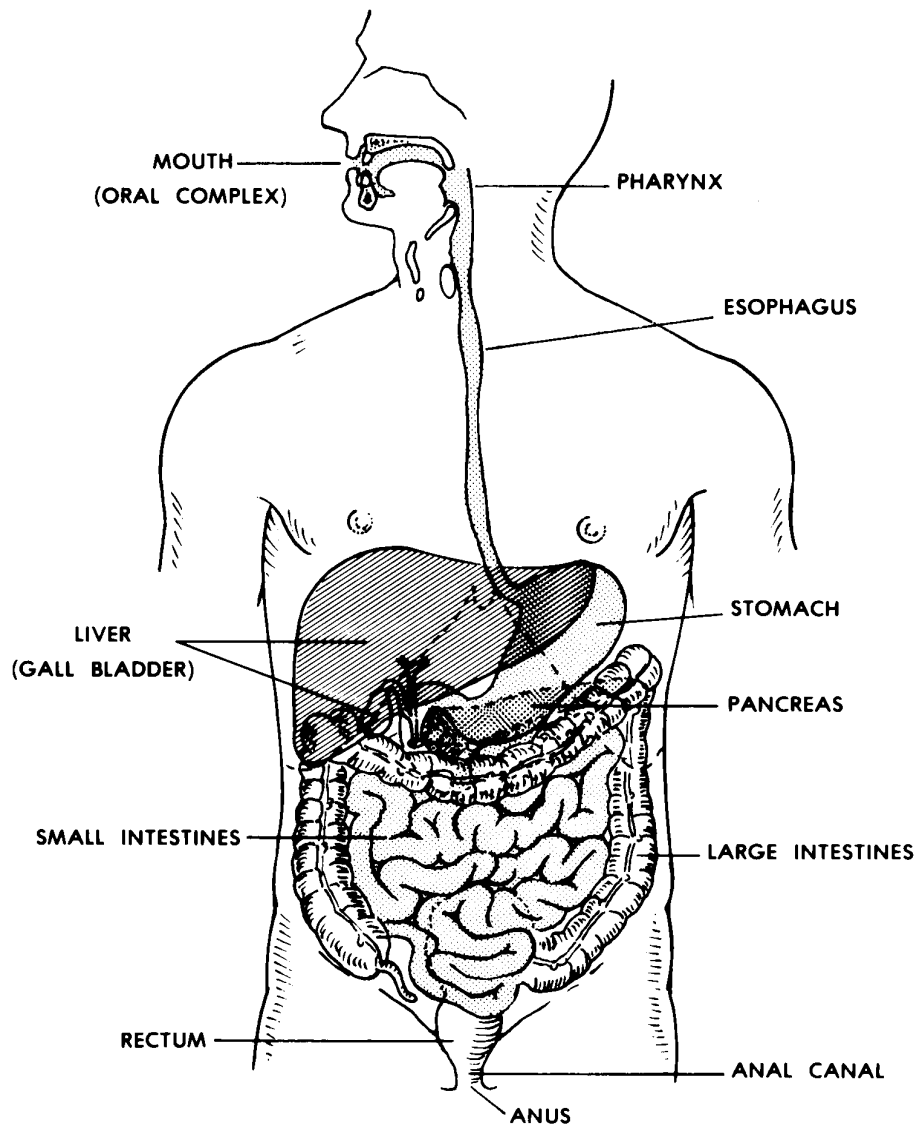


Figure 6-1. The human digestive system.

b. **Major Organs.** The major organs involved in the human digestive system are listed below. They are each discussed later in this lesson.

- (1) Mouth or oral complex.
- (2) Pharynx.
- (3) Esophagus.
- (4) Stomach.
- (5) Small intestines and associated glands.
- (6) Large intestines.
- (7) Rectum.
- (8) Anal canal and anus.

c. **Digestive Enzymes.** A catalyst is a substance that accelerates (speeds up) a chemical reaction without being permanently changed or consumed itself. A digestive enzyme serves as a catalyst, aiding in digestion. Digestion is a chemical process by which food is converted into simpler substances that can be absorbed or assimilated by the body. Enzymes are manufactured in the salivary glands of the mouth, in the lining of the stomach, in the pancreas, and in the walls of the small intestine.

6-2. FOODS AND FOODSTUFFS

Examples of food items are a piece of bread, a pork chop, and a tomato. Food items contain varying proportions of foodstuffs. Foodstuffs are the classes of chemical compounds which make up food items. The three major types of foodstuffs are carbohydrates, lipids (fats and oils), and proteins. Food items also contain water, minerals, and vitamins.

Section II. THE SUPRAGASTRIC STRUCTURES

6-3. ORAL COMPLEX

The oral complex consists of the structures commonly known together as the mouth. It takes in and initially processes food items. See figure 6-2.

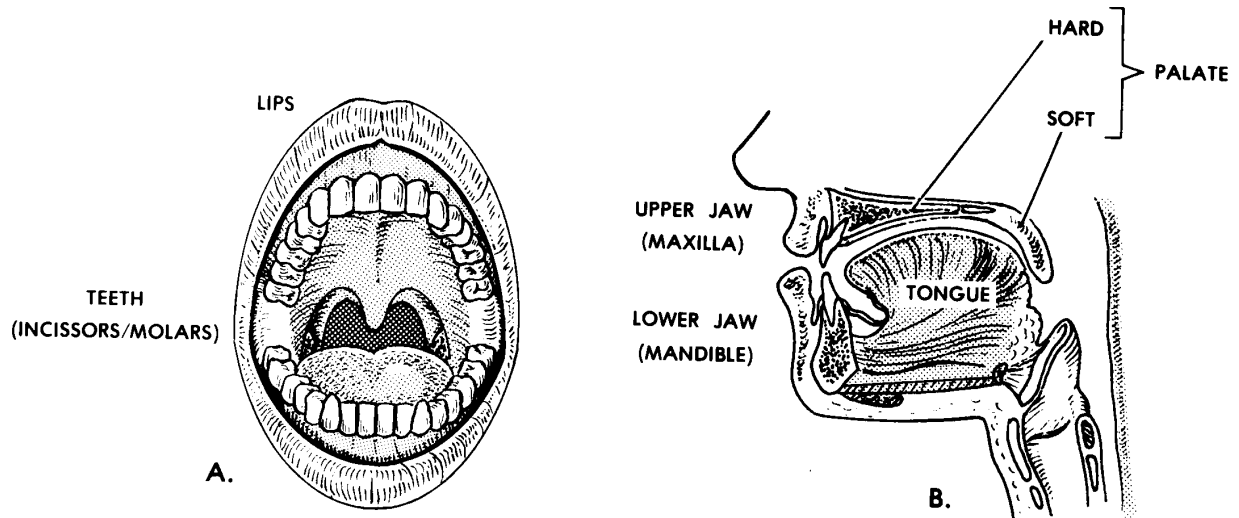


Figure 6-2. Anatomy of the oral complex.

a. **Teeth.**

(1) A tooth (figure 6-3) has two main parts--the crown and the root. A root canal passes up through the central part of the tooth. The root is suspended within a socket (called the alveolus) of one of the jaws of the mouth. The crown extends up above the surface of the jaw. The root and inner part of the crown are made of a substance called dentin. The outer portion of the crown is covered with a substance known as enamel. Enamel is the hardest substance of the human body. The nerves and blood vessels of the tooth pass up into the root canal from the jaw substance.

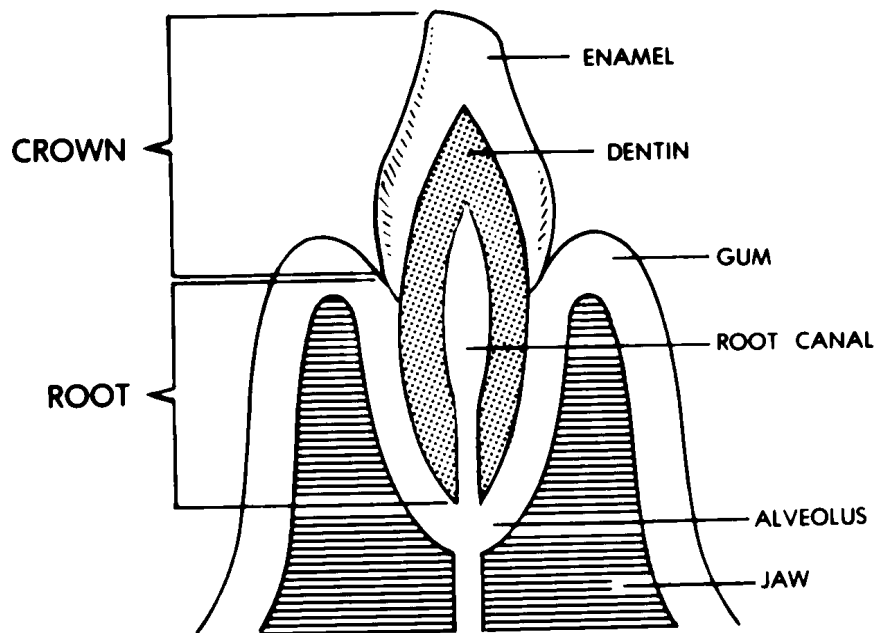


Figure 6-3. Section of a tooth and jaw.

(2) There are two kinds of teeth-- anterior and posterior. The anterior teeth are also known as incisors and canine teeth. The anterior teeth serve as choppers. They chop off mouth-size bites of food items. The posterior teeth are called molars. They are grinders. They increase the surface area of food materials by breaking them into smaller and smaller particles.

(3) Humans have two sets of teeth--deciduous and permanent. Initially, the deciduous set includes 20 baby teeth.

DECIDUOUS = to be shed

These are eventually replaced by a permanent set of 32.

b. **Jaws.** There are two jaws--the upper and the lower. The upper is called the maxilla. The lower is called the mandible.

(1) In each jaw, there are sockets for the teeth. These sockets are known as alveoli. The bony parts of the jaws holding the teeth are known as alveolar ridges.

(2) The upper jaw is fixed to the base of the cranium. The lower jaw is movable. There is a special articulation (T-MJ--temporo-mandibular joint) with muscles to bring the upper and lower teeth together to perform their functions.

c. **Palate.** The palate serves as the roof of the mouth and the floor of the nasal chamber above. Since the anterior two-thirds is bony, it is called the hard palate. The posterior one-third is musculo-membranous and is called the soft palate. The soft palate serves as a trap door to close off the upper respiratory passageway during swallowing.

d. **Lips and Cheeks.** The oral cavity is closed by a fleshy structure around the opening. Forming the opening are the lips. On the sides are the cheeks.

e. **Tongue.** The tongue is a muscular organ. The tongue is capable of internal movement to shape its body. It is moved as a whole by muscles outside the tongue. Interaction between the tongue and cheeks keeps the food between the molar teeth during the chewing process. When the food is properly processed, the tongue also initiates the swallowing process.

f. **Salivary Glands.** Digestion is a chemical process which takes place at the wet surfaces of food materials. The chewing process has greatly increased the surface area available. The surfaces are wetted by saliva produced by glands in the oral cavity. Of these glands, three pairs are known as the salivary glands proper.

g. **Taste Buds.** Associated with the tongue and the back of the mouth are special clumps of cells known as taste buds. These taste buds literally taste the food. That is, they check its quality and acceptability.

6-4. PHARYNX

The pharynx (pronounced "FAIR -inks") is a continuation of the rear of the mouth region, just anterior to the vertebral column (spine). It is a common passageway for both the respiratory and digestive systems.

6-5. ESOPHAGUS

The esophagus is a muscular, tubular structure extending from the pharynx, down through the neck and the thorax (chest), and to the stomach. During swallowing, the esophagus serves as a passageway for the food from the pharynx to the stomach.

Section III. THE STOMACH

6-6. STORAGE FUNCTION

The stomach is a sac-like enlargement of the digestive tract specialized for the storage of food. Since food is stored, a person does not have to eat continuously all day. One is freed to do other things. The presence of valves at each end prevents the stored food from leaving the stomach before it is ready. The pyloric valve prevents the food from going further. The inner lining of the stomach is in folds to allow expansion.

6-7. DIGESTIVE FUNCTION

a. While the food is in the stomach, the digestive processes are initiated by juices from the wall of the stomach. The musculature of the walls thoroughly mixes the food and juices while the food is being held in the stomach. In fact, the stomach has an extra layer of muscle fibers for this purpose.

b. When the pyloric valve of the stomach opens, a portion of the stomach contents moves into the small intestine.

Section IV. THE SMALL INTESTINES AND ASSOCIATED GLANDS

6-8. GENERAL

a. Digestion is a chemical process. This process is facilitated by special chemicals called digestive enzymes. The end products of digestion are absorbed through the wall of the gut into the blood vessels. These end products are then distributed to body parts that need them for growth, repair, or energy.

b. There are associated glands--the liver and the pancreas--which produce additional enzymes to further the process.

c. Most digestion and absorption takes place in the small intestines.

6-9. ANATOMY OF THE SMALL INTESTINES

a. The small intestines are classically divided into three areas-- the duodenum, the jejunum, and the ileum. The duodenum is C-shaped, about 10 inches long in the adult. The duodenum is looped around the pancreas.

DUODENUM = 12 fingers (length equal to width of 12 fingers)

The jejunum is approximately eight feet long and connects the duodenum and ileum. The ileum is about 12 feet long. The jejunum and ileum are attached to the rear wall of the abdomen with a membrane called a mesentery. This membrane allows mobility and serves as a passageway for nerves and vessels (NAVL) to the small intestines.

JEJUNUM = empty

ILEUM = lying next to the ilium (bone of the pelvic girdle; PELVIS = basin)

b. The small intestine is tubular. It has muscular walls which produce a wave-like motion called peristalsis moving the contents along. The small intestine is just the right length to allow the processes of digestion and absorption to take place completely.

c. The inner surface of the small intestine is NOT smooth like the inside of new plumbing pipes. Rather, the inner surface has folds (plicae). On the surface of these plicae are finger-like projections called villi (villus, singular). This folding and the presence of villi increase the surface area available for absorption.

6-10. LIVER AND GALLBLADDER

a. **Liver Anatomy.** The liver is a large and complex organ. Most of its mass is on the right side of the body and within the lower portion of the rib cage. Its upper surface is in contact with the diaphragm.

b. **Liver Functions.** The liver is a complex chemical factory with many functions. These include aspects of carbohydrate, protein, lipid, and vitamin metabolism and processes related to blood clotting and red blood cell destruction. Its digestive function is to produce a fluid called bile or gall.

c. **Gallbladder.** Until needed, the bile is stored and concentrated in the gallbladder, a sac on the inferior surface of the liver. Fluid from the gallbladder flows through the cystic duct, which joins the common hepatic duct from the liver to form the

common bile duct. The common bile duct then usually joins with the duct of the pancreas as the fluid enters the duodenum.

6-11. PANCREAS

The pancreas is a soft, pliable organ stretched across the posterior wall of the abdomen. When called upon, it secretes its powerful digestive fluid, known as pancreatic juice, into the duodenum. Its duct joins the common bile duct.

Section V. THE LARGE INTESTINES

6-12. GENERAL FUNCTION

The primary function of the large intestines is the salvaging of water and electrolytes (salts). Most of the end products of digestion have already been absorbed in the small intestines. Within the large intestines, the contents are first a watery fluid. Thus, the large intestines are important in the conservation of water for use by the body. The large intestines remove water until a nearly solid mass is formed before defecation, the evacuation of feces.

6-13. MAJOR SUBDIVISIONS

The major subdivisions of the large intestines are the cecum (with vermiform or "worm-shaped" appendix), the ascending colon, the transverse colon, the descending colon, and the sigmoid colon. The fecal mass is stored in the sigmoid colon until passed into the rectum.

6-14. RECTUM, ANAL CANAL, AND ANUS

Rectum means "straight." However, this six-inch tubular structure would actually look a bit wave-like from the front. From the side, one would see that it was curved to conform the sacrum (at the lower end of the spinal column). The final storage of feces is in the rectum. The rectum terminates in the narrow anal canal, which is about one and one-half inches long in the adult. At the end of the anal canal is the opening called the anus. Muscles called the anal sphincters aid in the retention of feces until defecation.

Section VI. ASSOCIATED PROTECTIVE STRUCTURES

6-15. GENERAL

Within the body, there are many structures that aid in protection from bacteria, viruses, and other foreign substances. These structures include cells that can phagocytize (engulf) foreign particles or manufacture antibodies (which help to inactivate foreign substances). Collectively, such cells make up the reticuloendothelial system (RES). Such cells are found in bone marrow, the spleen, the liver, and lymph nodes.

6-16. STRUCTURES WITHIN THE DIGESTIVE SYSTEM

Lymphoid structures make up the largest part of the RES. Lymphoid structures are collections of cells associated with circulatory systems (to be discussed in lesson 9).

- a. Tonsils are associated with the posterior portions of the respiratory and digestive areas in the head, primarily in the region of the pharynx. The tonsils are masses of lymphoid tissue.
- b. Other lymphoid aggregations are found in the walls of the small intestines.
- c. The vermiform appendix, attached to the cecum of the large intestine, is also a mass of lymphoid tissue. It is the "tonsil" of the intestines.

Continue with Exercises

4. The anterior teeth, called incisors and canine teeth, serve as _____. The posterior teeth, called molars, serve as _____.
5. The palate serves as the roof of the _____ and the floor of the _____. The soft palate serves as a _____ to close off the upper respiratory passageway during swallowing.
6. The tongue aids in _____ and _____.
7. The pharynx is a common passageway for both the _____ and _____ systems.
8. The esophagus serves as a passageway for food from the _____ to the _____.
9. What is the stomach?
10. The process of digestion is facilitated by special chemicals called _____. Most digestion and absorption take place in the _____.
11. In order after the stomach, the three areas of the small intestines are the _____, the _____, and the _____. The jejunum and ileum are attached to the rear wall of the abdomen with a membrane called the _____.
12. Folds on the inner surfaces of the small intestines are known as _____. Finger-like projections from these folds are known as _____.
13. The digestive function of the liver is to produce a fluid called _____. The common bile duct joins with the duct of the pancreas as the fluid enters the _____.

14. The texture of the pancreas is _____ and _____. Pertaining to location, the pancreas is stretched across the _____ of the abdomen.

15. The primary function of the large intestine is to _____ water and electrolytes. The large intestines remove water until a nearly solid mass is formed before _____.

16. In order, the major subdivisions of the large intestines are the _____, the _____ colon, the _____ colon, the _____ colon, and the _____ colon.

17. The rectum terminates in the narrow _____, at the end of which is an opening called the _____. Muscles called _____ aid in the retention of feces until defecation.

18. Attached to the cecum is a mass of lymphoid tissue called the _____.

Check Your Answers on Next Page

SOLUTIONS TO EXERCISES, LESSON 6

1. The human digestive system is a group of organs designed to take in foods, initially process foods, digest the foods, and eliminate unused materials of food items. It is a hollow tubular system from one end of the body to the other end. (para 6-1a)
2. Six major organs of the human digestive system are the:
 - a. Mouth (oral complex).
 - b. Pharynx.
 - c. Esophagus.
 - d. Stomach.
 - e. Small intestines.
 - f. Large intestines. (para 6-1b)
3. Seven important structures associated with the oral cavity are the:
 - a. Teeth.
 - b. Jaws (maxilla and mandible).
 - c. Palate.
 - d. Lips and cheeks.
 - e. Tongue.
 - f. Salivary glands.
 - g. Taste buds. (para 6-3)
4. The anterior teeth, called incisors and canine teeth, serve as choppers. The posterior teeth, called molars, serve as grinders. (para 6-3a(2))
5. The palate serves as the roof of the mouth and the floor of the nasal chamber. The soft palate serves as a trap door to close off the respiratory passageway during swallowing. (para 6-3c)
6. The tongue aids in chewing and swallowing. (para 6-3e)
7. The pharynx is a common passageway for both the respiratory and digestive systems. (para 6-4)
8. The esophagus serves as a passageway for food from the pharynx to the stomach. (para 6-5)
9. The stomach is a sac-like enlargement of the digestive tract specialized for the storage of food. (para 6-6)

10. The process of digestion is facilitated by special chemicals called digestive enzymes. Most digestion and absorption take place in the small intestines. (paras 6-8a, c)
11. In order after the stomach, the three areas of the small intestines are the duodenum, the jejunum, and the ileum. The jejunum and the ileum are attached to the rear wall of the abdomen with a membrane called the mesentery. (para 6-9a)
12. Folds on the inner surfaces of the small intestines are known as plicae. Finger-like projections from these folds are known as villi. (para 6-9c)
13. The digestive function of the liver is to produce a fluid called bile (gall). The common bile duct joins with the duct of the pancreas as the fluid enters the duodenum. (para 6-10)
14. The texture of the pancreas is soft and pliable. Pertaining to location, the pancreas is stretched across the posterior wall of the abdomen. (para 6-11)
15. The primary function of the large intestine is to salvage water and electrolytes. The large intestines remove water until a nearly solid mass is formed before defecation. (para 6-12)
16. In order, the major subdivisions of the large intestines are the cecum, the ascending colon, the transverse colon, the descending colon, and the sigmoid colon. (para 6-13)
17. The rectum terminates in the narrow anal canal, at the end of which is an opening called the anus. Muscles called anal sphincters aid in the retention of feces until defecation. (para 6-14)
18. Attached to the cecum is a mass of lymphoid tissue called the vermiform appendix. (para 6-16c)

End of Lesson 6

LESSON ASSIGNMENT

LESSON 7

The Human Respiratory System and Breathing.

TEXT ASSIGNMENT

Paragraphs 7-1 through 7-8.

LESSON OBJECTIVES

After completing this lesson, you should be able to:

- 7-1. Define respiration, external respiration, internal respiration, and breathing.
- 7-2. Identify the main subdivisions of the respiratory system and their functions.
- 7-3. Describe the external nose, nasal chambers, pharynx, larynx, trachea, bronchi, alveoli, lungs, and pleural cavities.
- 7-4. Describe breathing and breathing mechanisms.

SUGGESTION

After completing the assignment, complete the exercises at the end of this lesson. These exercises will help you to achieve the lesson objectives.

LESSON 7

THE HUMAN RESPIRATORY SYSTEM AND BREATHING

Section I. THE RESPIRATORY SYSTEM

7-1. INTRODUCTION

a. **Respiration.** Respiration is the exchange of gases between the atmosphere and the cells of the body. It is a physiological process. There are two types of respiration--external and internal. External respiration is the exchange of gases between the air in the lungs and blood. Internal respiration is the exchange of gases between the blood and the individual cells of the body.

b. **Breathing.** Breathing is the process that moves air into and out of the lungs. It is a mechanical process. There are two types of breathing in humans--costal (thoracic) and diaphragmatic (abdominal). In costal breathing, the major structure causing the movement of the air is the rib cage. In diaphragmatic breathing, interaction between the diaphragm and the abdominal wall causes the air to move into and out of the lungs.

7-2. COMPONENTS AND SUBDIVISIONS OF THE HUMAN RESPIRATORY SYSTEM

See figure 7-1 for an illustration of the human respiratory system.

a. **Components.** The components of the human respiratory system consist of air passageways and two lungs. Air moves from the outside of the body into tiny sacs in the lungs called alveoli (pronounced al-VE-oh-lie).

b. **Main Subdivisions.** The main subdivisions of the respiratory system may be identified by their relationship to the voice box or larynx. Thus, the main subdivisions are as listed in [table 7-1](#).

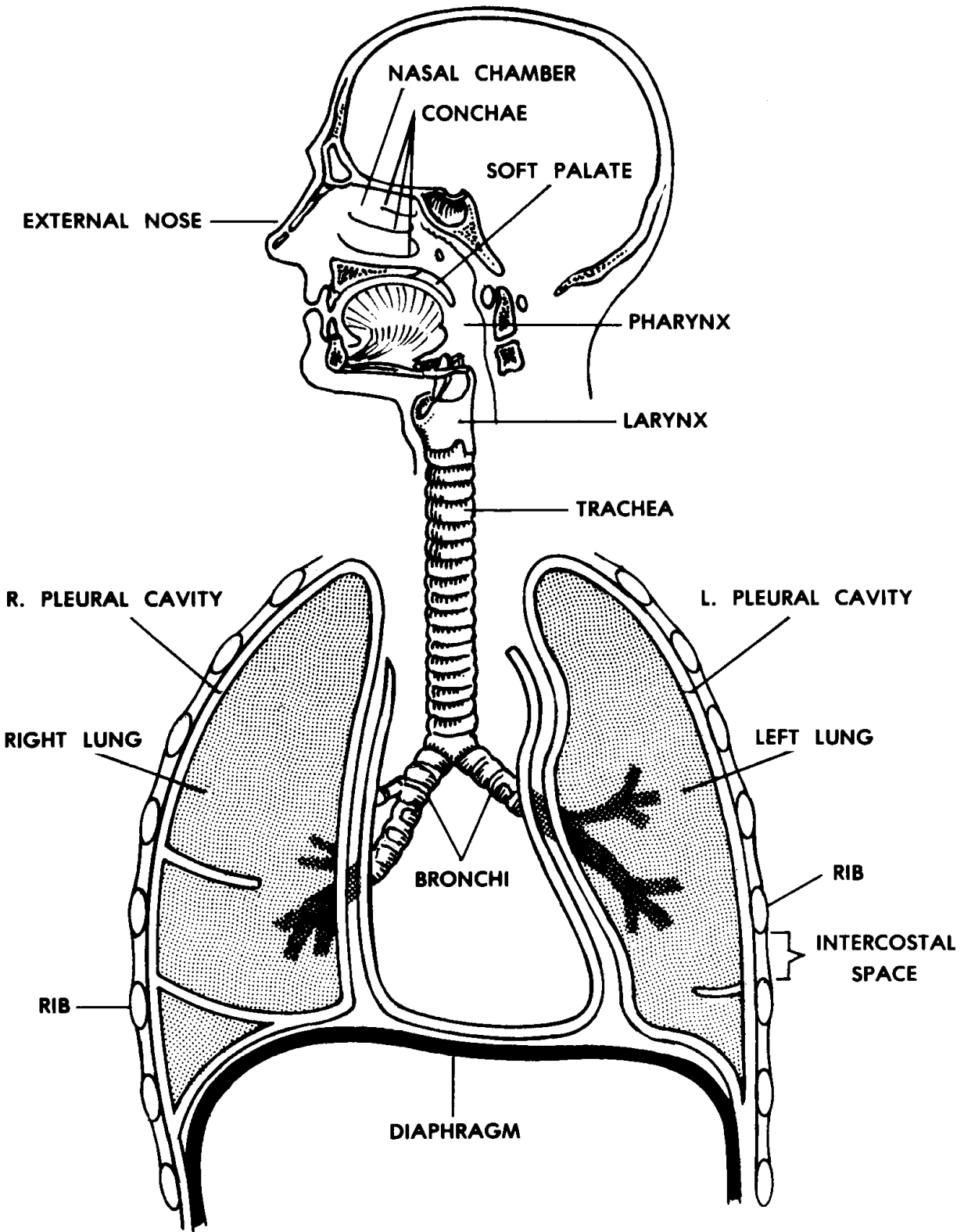


Figure 7-1. The human respiratory system.

SUBDIVISION	FUNCTION
(1) SUPRALARYNGEAL STRUCTURES (su-prah-lah-RIN-je-al)	Cleanse, warm, moisten, and test inflowing air
(2) LARYNX (voice box) (LARE-inks)	Controls the volume of inflowing air; produces selected pitch(vibration frequency) in the moving column of air
(3) INFRALARYNGEAL STRUCTURES (in-frah-lah-RIN-je-al)	Distribute air to the alveoli of the lung where the actual external respiration takes place

Table 7-1. The main subdivisions of the respiratory system.

7-3. SUPRALARYNGEAL STRUCTURES

See figure 7-2.

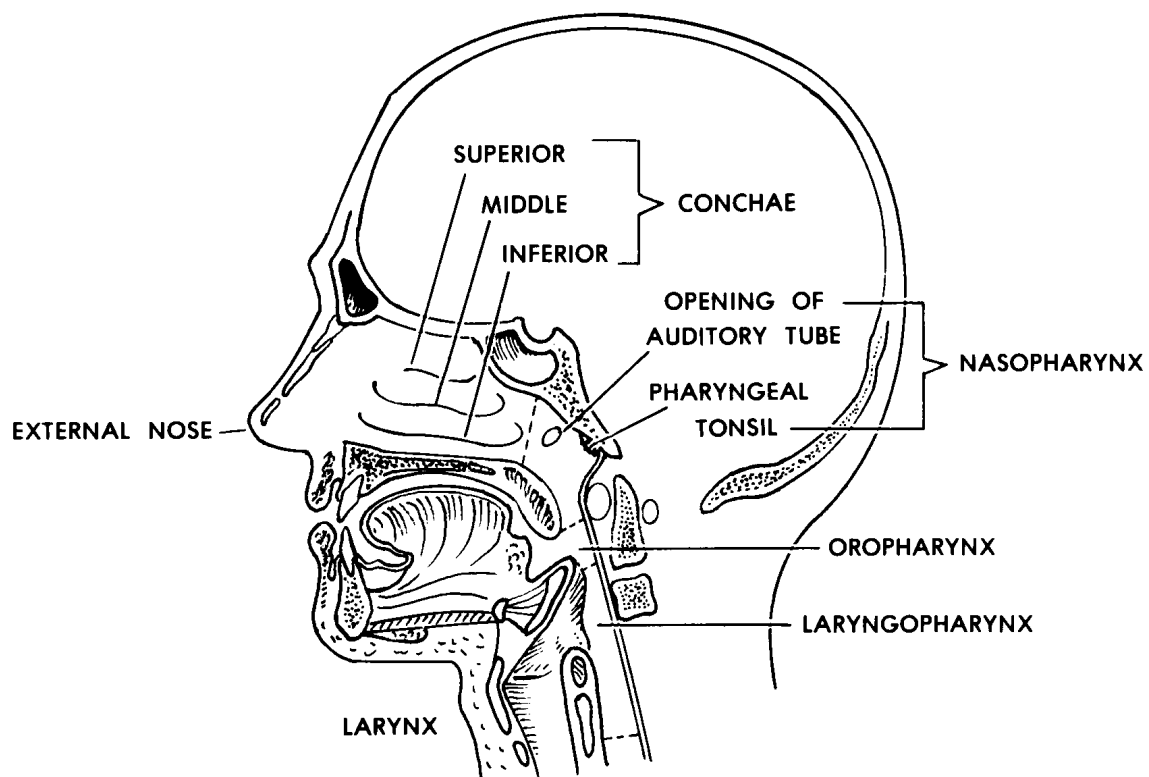


Figure 7-2. Supralaryngeal structures.

a. **External Nose.** The external nose is the portion projecting from the face. It is supported primarily by cartilages. It has a midline divider called the nasal septum, which extends from the internal nose. Paired openings (nostrils) lead to paired spaces (vestibules). Guard hairs in the nostrils filter inflowing air.

b. **Nasal Chambers (Internal Nose).** Behind each vestibule of the external nose is a nasal chamber. The two nasal chambers together form the internal nose. These chambers too are separated by the nasal septum.

(1) Mucoperiosteum. The walls of the nasal chambers are lined with a thick mucous-type membrane known as the mucoperiosteum. It has a ciliated epithelial surface and a rich blood supply, which provides warmth and moisture. At times, it may become quite swollen.

CILIATED = provided with cilia (hairlike projections which move fluids to the rear)

(2) Conchae. The lateral wall of each chamber has three scroll-like extensions into the nasal chamber which help to increase the surface area exposed to the inflowing air. These scroll-like extensions are known as conchae.

CONCHA (pronounced KON-kah) = sea shell

CONCHA (singular), CONCHAE (plural)

(3) Olfactory epithelium. The sense of smell is due to special nerve endings located in the upper areas of the nasal chambers. The epithelium containing the sensory endings is known as the olfactory epithelium.

(4) Paranasal sinuses. There are air "cells" or cavities in the skull known as paranasal sinuses. The paranasal sinuses are connected with the nasal chambers and are lined with the same ciliated mucoperiosteum. Thus, these sinuses are extensions of the nasal chambers into the skull bones. For this reason, they are known as paranasal sinuses.

c. **Pharynx.** The pharynx (FAIR-inks) is the common posterior space for the respiratory and digestive systems.

(1) Nasopharynx. That portion of the pharynx specifically related to the respiratory system is the nasopharynx. It is the portion of the pharynx above the soft palate. The two posterior openings (nares) of the nasal chambers lead into the single space of the nasopharynx. The auditory (eustachian) tubes also open into the nasopharynx. The auditory tubes connect the nasopharynx with the middle ears (to equalize the pressure between the outside and inside of the eardrum). Lying in the upper posterior wall of the nasopharynx are the pharyngeal tonsils (adenoids). The soft palate floor of the nasopharynx is a trapdoor which closes off the upper respiratory passageways during swallowing.

(2) Oropharynx. The portion of the pharynx closely related to the digestive system is the oropharynx. It is the portion of the pharynx below the soft palate and above the upper edge of the epiglottis. (The epiglottis is the flap that prevents food from entering the larynx (discussed below) during swallowing.)

(3) Laryngopharynx. That portion of the pharynx which is common to the respiratory and digestive systems is the laryngopharynx. It is the portion of the pharynx below the upper edge of the epiglottis. Thus, the digestive and respiratory systems lead into it from above and lead off from it below.

7-4. LARYNX

The larynx, also called the Adam's apple or voice box, connects the pharynx with the trachea. The larynx, located in the anterior neck region, has a box-like shape. See figure 7-3 for an illustration. Since the voice box of the male becomes larger and heavier during puberty, the voice deepens. The adult male's voice box tends to be located lower in the neck; in the female, the larynx remains higher and smaller and the voice is of a higher pitch.

a. **Parts and Spaces.** The larynx has a vestibule ("entrance hallway") which can be covered over by the epiglottis. The glottis itself is the hole between the vocal cords. Through the glottis, air passes from the vestibule into the main chamber of the larynx (below the cords) and then into the trachea. The skeleton of the larynx is made up of a series of cartilages.

b. **Muscles.** The larynx serves two functions and there are two sets of muscles--one for each function.

(1) One set controls the size of the glottis. Thus, it regulates the volume of air passing through the trachea.

(2) The other set controls the tension of the vocal cords. Thus, it produces vibrations of selected frequencies (variations in pitch) of the moving air to be used in the process of speaking.

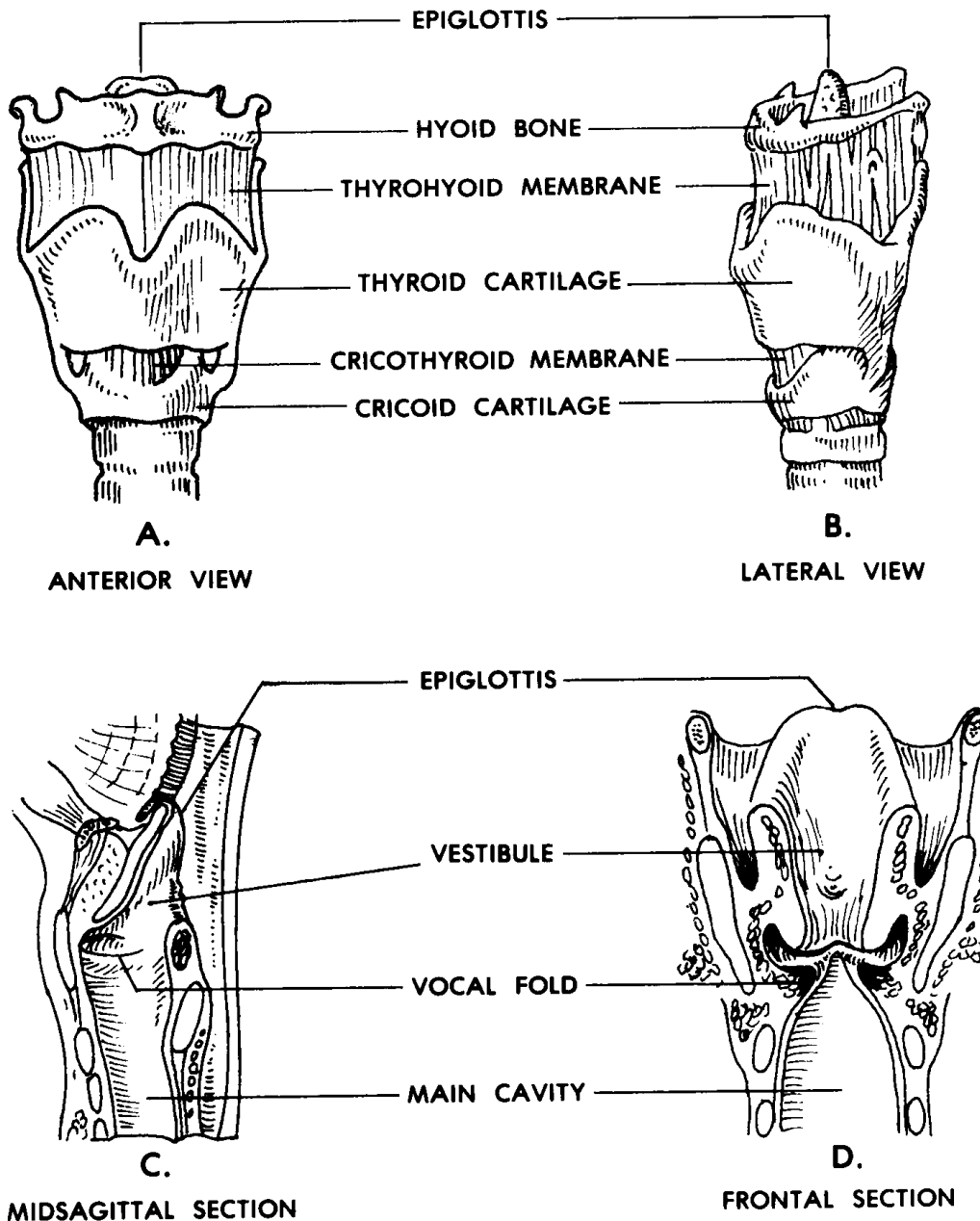


Figure 7-3. The larynx.

7-5. INFRALARYNGEAL STRUCTURES

a. **Trachea and Bronchi.** The respiratory tree (figure 7-4) is the set of tubular structures which carry the air from the larynx to the alveoli of the lungs. Looking at a person **UPSIDE DOWN**, the trachea is the trunk of the tree and the bronchi are the branches. These tubular parts are held open (made patent) by rings of cartilage. Their lining is ciliated to remove mucus and other materials that get into the passageway.

A. "RESPIRATORY TREE"

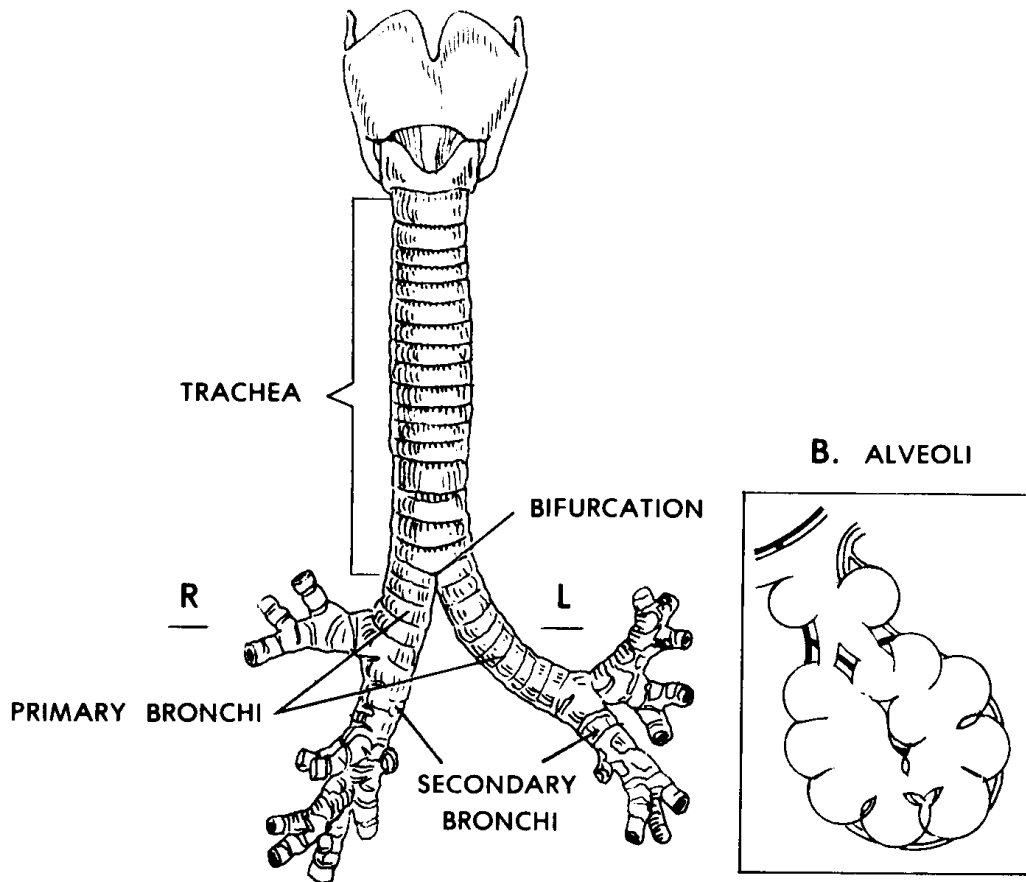


Figure 7-4. Infralaryngeal structures ("respiratory tree").

b. **Alveoli.** The alveoli (alveolus, singular) are tiny spherical (balloon-like) sacs which are connected to the larger tubes of the lungs by tiny tubes known as alveolar ducts and bronchioles. The alveoli are so small that there are billions in the adult lungs. This very small size produces a maximum surface area through which external respiration takes place. External respiration is the actual exchange of gases between the air in the alveolar spaces and the adjacent blood capillaries through their walls.

c. **Lungs.** A lung is an individual organ composed of tubular structures and alveoli bound together by fibrous connective tissue (FCT). In the human, there are two lungs--right and left. Each lung is supplied by a primary or mainstem bronchus leading off of the trachea. The right lung is larger in volume than the left lung. The left lung must leave room for the heart. The right lung is divided into three pulmonary lobes (upper, middle, and lower) and 10 bronchopulmonary segments (2 + 3 + 5). The left lung is divided into two pulmonary lobes (upper and lower) and eight bronchopulmonary segments (4 + 4). A pulmonary lobe is a major subdivision of a lung marked by fissures (deep folds). Each lobe is further partitioned into bronchopulmonary segments. Each

lobe is supplied by a secondary or lobar bronchus. Each segment is supplied by a tertiary or segmental bronchus, a branch of the lobar bronchus.

d. **Pleural Cavities.** See [paragraph 3-14](#) to review a description of pleural cavities. That paragraph indicates that each serous cavity has inner and outer membranes. In the case of the lungs, the inner membrane is known as the visceral pleura which very closely covers the surface of the lungs. The outer membrane is known as the parietal pleura, forming the outer wall of the cavity. The pleural cavities are the potential spaces between the inner and outer membranes. The pleural cavities allow the lungs to move freely with a minimum of friction during the expansion and contraction of breathing.

Section II. BREATHING AND BREATHING MECHANISMS IN HUMANS

7-6. INTRODUCTION

a. Boyle's law tells us that as the volume (V) of a gas-filled container increases, the pressure (P) inside decreases; as the volume (V) of a closed container decreases, the pressure (P) inside increases. When two connected spaces of air have different pressures, the air moves from the space with greater pressure to the one with lesser pressure. In regard to breathing, we can consider the air pressure around the human body to be constant. The pressure inside the lungs may be greater or less than the pressure outside the body. Thus, a greater internal pressure causes air to flow out; a greater external pressure causes air to flow in.

b. We can compare the human trunk to a hollow cylinder. This cylinder is divided into upper and lower cavities by the diaphragm. The upper is the thoracic cavity and is essentially gas-filled. The lower is the abdominopelvic cavity and is essentially water-filled.

7-7. COSTAL (THORACIC) BREATHING

a. **Inhalation.** Muscles attached to the thoracic cage raise the rib cage. A typical rib might be compared to a bucket handle, attached at one end to the sternum (breastbone) and at the other end to the vertebral column. The "bucket handle" is lifted by the overall movement upward and outward of the rib cage. These movements increase the thoracic diameters from right to left (transverse) and from front to back (A-P). Thus, the intrathoracic volume increases. Recalling Boyle's law, the increase in volume leads to a decrease in pressure. The air pressure outside the body then forces air into the lungs and inflates them.

b. **Exhalation.** The rib cage movements and pressure relationships are reversed for exhalation. Thus, intrathoracic volume decreases. The intrathoracic pressure increases and forces air outside the body.

7-8. DIAPHRAGMATIC (ABDOMINAL) BREATHING

The diaphragm is a thin, but strong, dome-shaped muscular membrane that separates the abdominal and thoracic cavities. The abdominal wall is elastic in nature. The abdominal cavity is filled with soft, watery tissues.

a. **Inhalation.** As the diaphragm contracts, the dome flattens and the diaphragm descends. This increases the depth (vertical diameter) of the thoracic cavity and thus increases its volume. This decreases air pressure within the thoracic cavity. The greater air pressure outside the body then forces air into the lungs.

b. **Exhalation.** As the diaphragm relaxes, the elastic abdominal wall forces the diaphragm back up by pushing the watery tissues of the abdomen against the underside of the relaxed diaphragm. The dome extends upward. The process of inhalation is thus reversed.

Continue with Exercises

EXERCISES, LESSON 7

REQUIREMENT. The following exercises are to be answered by completing the incomplete statement or by writing the answer in the space provided at the end of the question.

After you have completed all the exercises, turn to "Solutions to Exercises," at the end of the lesson and check your answers.

1. What is respiration?
2. What is external respiration?
3. What is internal respiration?
4. What is breathing?
5. In costal breathing, the major structure causing movement of the air is the _____.
6. In diaphragmatic breathing, air movement is caused by interaction between the _____ and the _____.
7. The components of the human respiratory system consist of air _____ and two _____. Air moves from the outside of the body into tiny sacs in the lungs called _____.
8. The main subdivisions of the respiratory system may be identified by their relationship to the _____ (v _____ b _____). The subdivisions are as follows: _____ structures, the _____, and _____ structures.

9. The functions of the supralaryngeal structures are to c_____, w_____, m_____, and t_____ inflowing air.
10. The functions of the larynx are to control the _____ of the inflowing air and to produce selected _____ (_____).
11. The function of the infralaryngeal structures is to distribute air to the _____ of the _____. Here, actual external respiration takes place.
12. The external nose is supported primarily by _____.
13. The two nasal chambers are separated by the _____. The walls of the nasal chambers are lined with a membrane known as the _____. Scroll-like extensions, which increase the surface area of the lateral walls, are known as _____. Sensory endings for the sense of smell are found in the _____ epithelium. Air "cells" or cavities in the skull are known as _____.
14. That portion of the pharynx specifically related to the respiratory system is the _____. It is the portion of the pharynx above the _____.
15. During swallowing, food is prevented from entering the larynx by the _____.
16. In the larynx, one set of muscles regulates the volume of air passing through the trachea by controlling the _____. Another set of muscles produces selected frequencies (variations in pitch) by controlling the _____.
17. The trunk of the respiratory tree is called the _____. The branches are called the _____.
18. What are alveoli?
19. A lung is an individual organ composed of _____ structures and _____ bound together by _____ tissue.

20. The pleural cavities allow the lungs to move freely with a minimum of _____ during the expansion and contraction of breathing.

21. In both costal and diaphragmatic breathing, inhalation depends upon an increase in lung volume. The diameters increased in costal breathing are from _____ and from _____. The diameter increased in diaphragmatic breathing is _____.

Check Your Answers on Next Page

SOLUTIONS TO EXERCISES, LESSON 7

1. Respiration is the exchange of gases between the atmosphere and the cells of the body. (para 7-1a)
2. External respiration is the exchange of gases between the air in the lungs and blood. (para 7-1a)
3. Internal respiration is the exchange of gases between the blood and the individual cells of the body. (para 7-1a)
4. Breathing is the process that moves air into and out of the lungs. It is a mechanical process. (para 7-1b)
5. In costal breathing, the major structure causing movement of the air is the rib cage. (para 7-1b)
6. In diaphragmatic breathing, air movement is caused by interaction between the diaphragm and the abdominal wall. (para 7-1b)
7. The components of the human respiratory system consist of air passageways and two lungs. Air moves from the outside of the body into tiny sacs in the lungs called alveoli. (para 7-2a)
8. The main subdivisions of the respiratory system may be identified by their relationship to the larynx (voice box). The subdivisions are as follows: supralaryngeal structures, the larynx, and infralaryngeal structures. (para 7-2b)
9. The functions of the supralaryngeal structures are to cleanse, warm, moisten, and test inflowing air. (para 7-2b)
10. The functions of the larynx are to control the volume of the inflowing air and to produce selected pitch (vibration frequency). (para 7-2b)
11. The function of the infralaryngeal structures is to distribute air to the alveoli of the lung. Here, actual external respiration takes place. (para 7-2b)
12. The external nose is supported primarily by cartilages. (para 7-3a)
13. The two nasal chambers are separated by the nasal septum. The walls of the nasal chambers are lined with a membrane known as the mucoperiosteum. Scroll-like extensions, which increase the surface area of the lateral walls, are known as conchae. Sensory endings for the sense of smell are found in the olfactory epithelium. Air "cells" or cavities in the skull are known as paranasal sinuses. (para 7-3b)

14. That portion of the pharynx specifically related to the respiratory system is the nasopharynx. It is the portion of the pharynx above the soft palate. (para 7-3c(1))
15. During swallowing, food is prevented from entering the larynx by the epiglottis. (para 7-3c(2))
16. In the larynx, one set of muscles regulates the volume of air passing through the trachea by controlling the size of the glottis. Another set of muscles produces selected frequencies (variations in pitch) by controlling the tension of the vocal cords. (para 7-4b)
17. The trunk of the respiratory tree is called the trachea. The branches are called the bronchi. (para 7-5a)
18. Alveoli are tiny spherical sacs in the lungs. They are the site of external respiration. (para 7-5b)
19. A lung is an individual organ composed of tubular structures and alveoli bound together by fibrous connective tissue. (para 7-5c)
20. The pleural cavities allow the lungs to move freely with a minimum of friction during the expansion and contraction of breathing. (para 7-5d)
21. In both costal and diaphragmatic breathing, inhalation depends upon an increase in lung volume. The diameters increased in costal breathing are from right to left (transverse) and from front to back (A-P). The diameter increased in diaphragmatic breathing is vertical (depth). (paras 7-7a, 7-8a)

End of Lesson 7

LESSON ASSIGNMENT

LESSON 8

The Human Urogenital Systems.

TEXT ASSIGNMENT

Paragraphs 8-1 through 8-16.

LESSON OBJECTIVES

After completing this lesson, you should be able to:

- 8-1. Define urogenital systems.
- 8-2. Identify the function and major parts of the human urinary system.
- 8-3. Describe the kidney, including its gross internal structure and the structure of the nephron.
- 8-4. Describe the ureters, the urinary bladder, and the urethra.
- 8-5. Identify general characteristics of both the male and female genital systems.
- 8-6. Describe the ovaries, the uterine tubes, the uterus, the vagina, the external genitalia, and secondary sexual characteristics of human females.
- 8-7. Describe the testes, the epididymis, the ductus deferens, the seminal vesicles, the ejaculatory duct, the prostate gland, the penis, and the secondary sexual characteristics of human males.

SUGGESTION

After completing the assignment, complete the exercises at the end of this lesson. These exercises will help you to achieve the lesson objectives.

LESSON 8

THE HUMAN UROGENITAL SYSTEMS

Section I. THE HUMAN URINARY SYSTEM

8-1. DEFINITION

The human urogenital systems are made up of the urinary organs, which produce the fluid called urine, and the genital, or reproductive, organs of male and female humans, which together can produce a new human being.

8-2. INTRODUCTION TO THE HUMAN URINARY SYSTEM

a. Proteins are one of the basic foodstuffs that humans consume. When proteins are used by the body, there are residue or waste products which can be poisonous (toxic) if allowed to accumulate in large amounts. The urinary system of the human body is specialized to remove these nitrogenous waste products from the circulating blood.

b. **Major Parts.** See figure 8-1 for the major parts of the human urinary system. This system includes two kidneys, two ureters (one connecting each kidney to the urinary bladder), the urinary bladder, and the urethra.

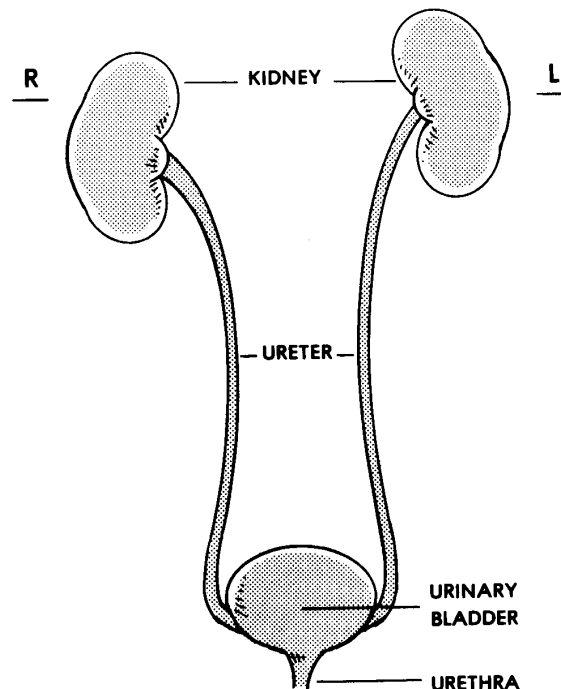


Figure 8-1. The human urinary system.

8-3. THE KIDNEY

a. General.

(1) The kidneys have the same shape and color as kidney beans, but are about 8-10 centimeters (3-3 1/2 inches) in length.

(2) Each kidney has a fibrous capsule. On the concave, medial side of each kidney, there is a notch called the hilus. Through this hilus pass the ureter and the NAVL (nerve, artery, vein, and lymphatic) which service the kidney.

(3) Each kidney is attached to the posterior wall of the abdominal cavity, just above the waistline level. Each is held in place by special fascia and fat.

b. **Gross Internal Structure.** If we compare the structure of the kidney with that of a cantaloupe (muskmelon), the renal cortex would correspond to the hard rind, the renal medulla would correspond with the edible flesh of the melon, while the renal sinus would correspond to the hollow center (after the seeds have been removed). The medulla consists of pyramids with their bases at the cortex and forming peaks, papillae, which empty into the sinus.

PAPILLA = pimple, nipple

See figure 8-2 for a section of the kidney showing the inner structure.

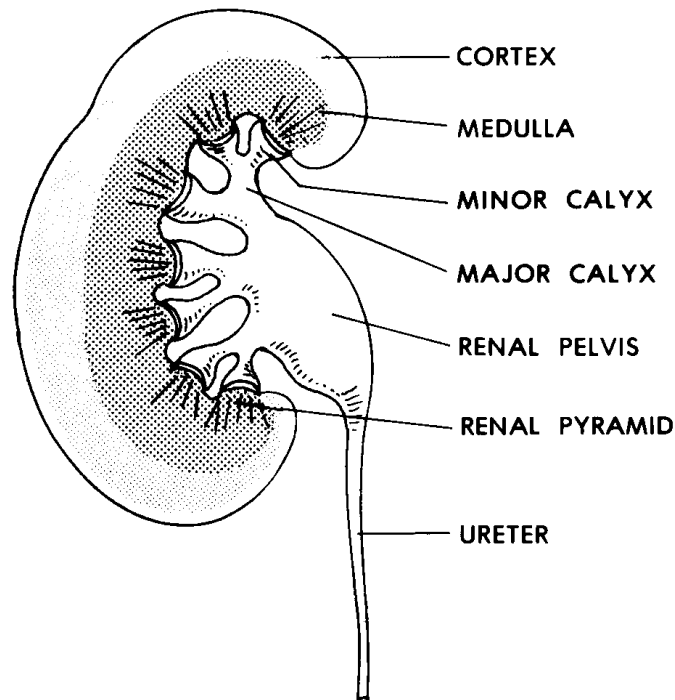


Figure 8-2. A section of a human kidney.

c. **The Nephron.** See figure 8-3 for an illustration of a nephron. Nephrons are the functional units of the human kidney. Their primary function is to remove the wastes of protein usage from the blood. In addition, they serve to conserve water and other materials for continued use by the body. The end result of nephron function is a more or less concentrated fluid called urine. The kidneys contain great numbers of nephrons, about a million for each kidney. The main subdivisions of a nephron are the renal corpuscle and a tubular system.

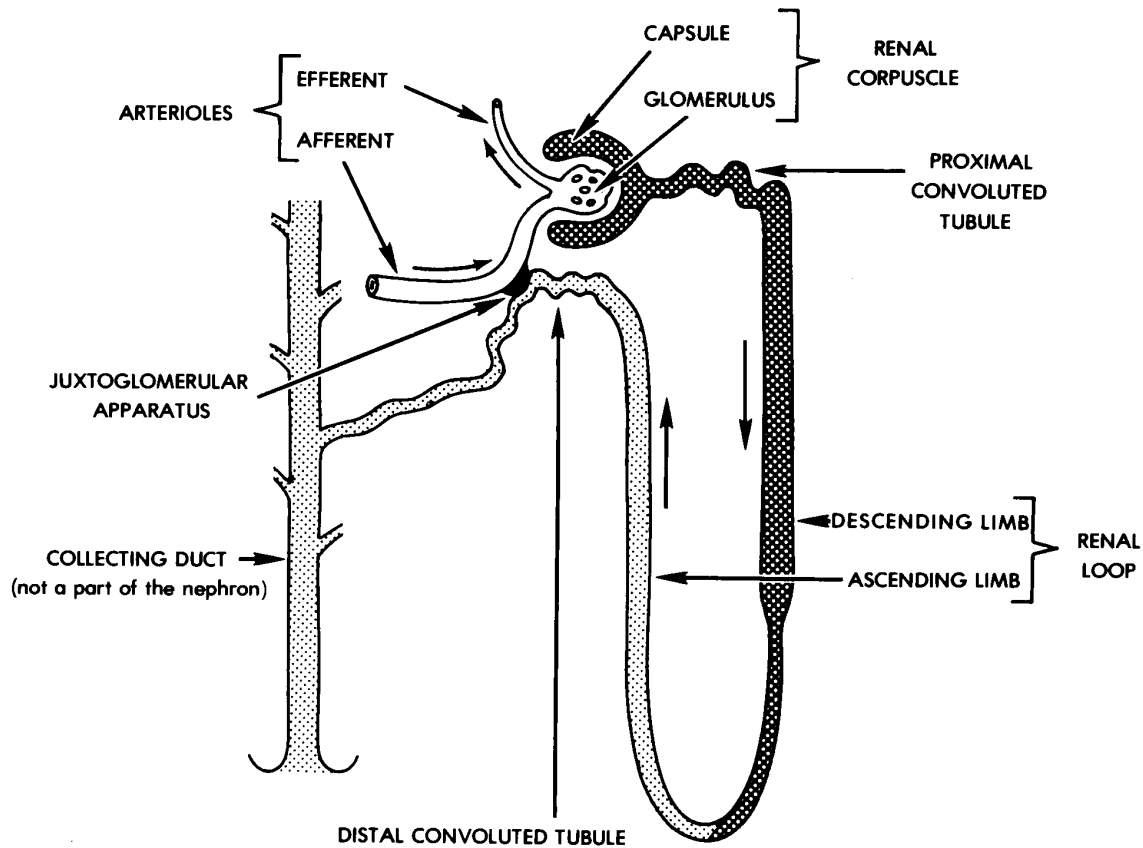


Figure 8-3. A "typical" nephron.

(1) Renal corpuscle. The renal corpuscle has a hollow double-walled sac called the renal capsule ("Bowman's capsule"). Leading into the capsule is a very small artery called the afferent arteriole. Within the capsule, this artery becomes a mass of capillaries known as the glomerulus. An efferent arteriole drains the blood away from the capsule. The capsule and the glomerulus together are known as the renal corpuscle.

(2) Tubules. Each renal capsule is drained by a renal tubule. The first part of this tubule runs quite a distance in a coiled formation and is called the proximal convoluted tubule. A long loop, the renal loop (of Henle), extends down into the medulla with two straight parts and a sharp bend at the bottom. As the tube returns to

the cortex layer, it once again becomes coiled and here is known as the distal convoluted tubule.

(3) Filtration/reabsorption. Except for the blood cells and the larger proteins, the fluid portion of the blood passes through the walls of the glomerulus into the cavity between the two layers of the renal capsule. This fluid is called the glomerular filtrate. By a process of taking back (resorption), the majority of the fluid is removed from the tubules and the concentrated fluid is called the urine.

d. **The Collecting Tubule**. The distal convoluted tubules of several nephrons empty into a collecting tubule. The urine is then passed from the collecting tubule at the papilla of the medullary pyramid. Several collecting tubules are present in each pyramid.

e. **Renal Pelvis**. The renal pelvis is a hollow sac within the sinus of the kidney. Urine from the pyramids collects into the funnel-shaped renal pelvis. The ureter then drains the urine from the renal pelvis.

8-4. URETERS

The ureters are tubes which connect the kidneys to the urinary bladder. The smooth muscle walls of the ureters produce a peristalsis (wave-like movement) that moves the urine along drop by drop.

8-5. URINARY BLADDER

a. The urinary bladder is a muscular organ for storing the urine. Near the inferior posterior corners of the urinary bladder are openings where the ureters empty into the bladder. Also at the inferior aspect of the urinary bladder is the exit, the beginning of the urethra. The triangular area, between the openings of the ureters and the urethra, is called the trigone, or base of the urinary bladder.

b. The urinary bladder wall is stretchable to accommodate varying volumes of urine.

c. Nerve endings called stretch receptors are found in the wall of the urinary bladder. Usually, the pressure within the urinary bladder is low. However, as the volume of the enclosed urine approaches the bladder's capacity, stretching of the wall stimulates the stretch receptors. The cycle of events controlling urination (voiding or emptying of the urinary bladder) is known as the voiding reflex.

8-6. URETHRA

The urethra is a tube which conducts the urine from the urinary bladder to the outside of the body. It begins at the anterior base of the urinary bladder.

a. **Urethral Sphincters.** The urethral sphincters are circular muscle masses which control the passage of the urine through the urethra. There are two urethral sphincters--an internal urethral sphincter and an external urethral sphincter.

(1) The internal urethral sphincter is located in the floor of the urinary bladder. It is made of smooth muscle tissue. It is controlled by nerves of the autonomic nervous system (lesson 11).

(2) The external urethral sphincter is more inferior around the urethra in the area of the pelvic floor. It is made up of striated muscle tissue. It is controlled by the peripheral nervous system (lesson 11).

b. **Male-Female Differences.** The female urethra is short and direct. The male urethra is much longer and has two curvatures. Whereas the female urethra serves only a urinary function, the male urethra serves both the urinary and reproductive functions.

Section II. INTRODUCTION TO HUMAN GENITAL (REPRODUCTIVE) SYSTEMS

8-7. SEXUAL DIMORPHISM

The human male and human female each has a system of organs specifically designed for the production of new humans. These systems are known as reproductive or genital systems. Since there are different systems for males and females, the genital systems are an example of sexual dimorphism.

MORPH = form, shape

DI = two

SEXUAL = according to sex (gender)

SEXUAL DIMORPHISM = having two different forms according to sex

8-8. ADVANTAGES OF DOUBLE PARENTING

The existence of two parents for each child means that genetic materials are recombined to produce a new type. This new type may be an improvement over previous generations.

8-9. MAJOR COMPONENT CATEGORIES OF THE GENITAL SYSTEMS

Components of the genital systems may be considered in the following categories:

a. **Primary Sex Organs (Gonads).** Primary sex organs produce sex cells (gametes). A male gamete and a female gamete may be united to form the one-cell

beginning of an embryo (the process of fertilization). Primary sex organs also produce sex hormones.

b. **Secondary Sex Organs.** Secondary sex organs care for the product of the primary sex organ.

c. **Secondary Sexual Characteristics.** Secondary sexual characteristics are those traits that tend to make males and females more attractive to each other. Secondary sexual characteristics help to ensure mating. These characteristics first appear during puberty (10-15 years of age).

Section III. THE HUMAN FEMALE GENITAL (REPRODUCTIVE) SYSTEM

8-10. PRIMARY SEX ORGANS (OVARIES)

The primary sex organ in the human female is the ovary. See figure 8-4 for an illustration of the female genital system. The ovaries are located to the sides of the upper end of the uterus. They are anchored to the posterior surface of the broad ligaments. (The broad ligaments are sheets or folds of peritoneum enclosing the uterus and uterine tubes and extending to the sides of the pelvis.)

- a. The ovary produces the egg cell or ovum (ova, plural).
- b. The ovary produces female sex hormones (estrogens and progesterone).
- c. The production of ova is cyclic. One ovum is released in each menstrual period, about 28 days.

8-11. SECONDARY SEX ORGANS

a. **Uterine Tubes (Fallopian Tubes, Oviducts).** Extending to either side of the uterus are two muscular tubes which open at the outer ends like fringed trumpets. The fringe-like appendages encircle the ovaries. At their medial ends, the uterine tubes open into the uterus. The function of the uterine tubes is to pick up the ovum when released from the ovary and hold it UNTIL one of the following happens:

(1) It is fertilized. After fertilization, the initial stages of embryo development take place. The developing embryo is eventually moved into the uterus.

(2) The nutrient stored within the ovum is used up and the ovum dies. This may take three to five days.

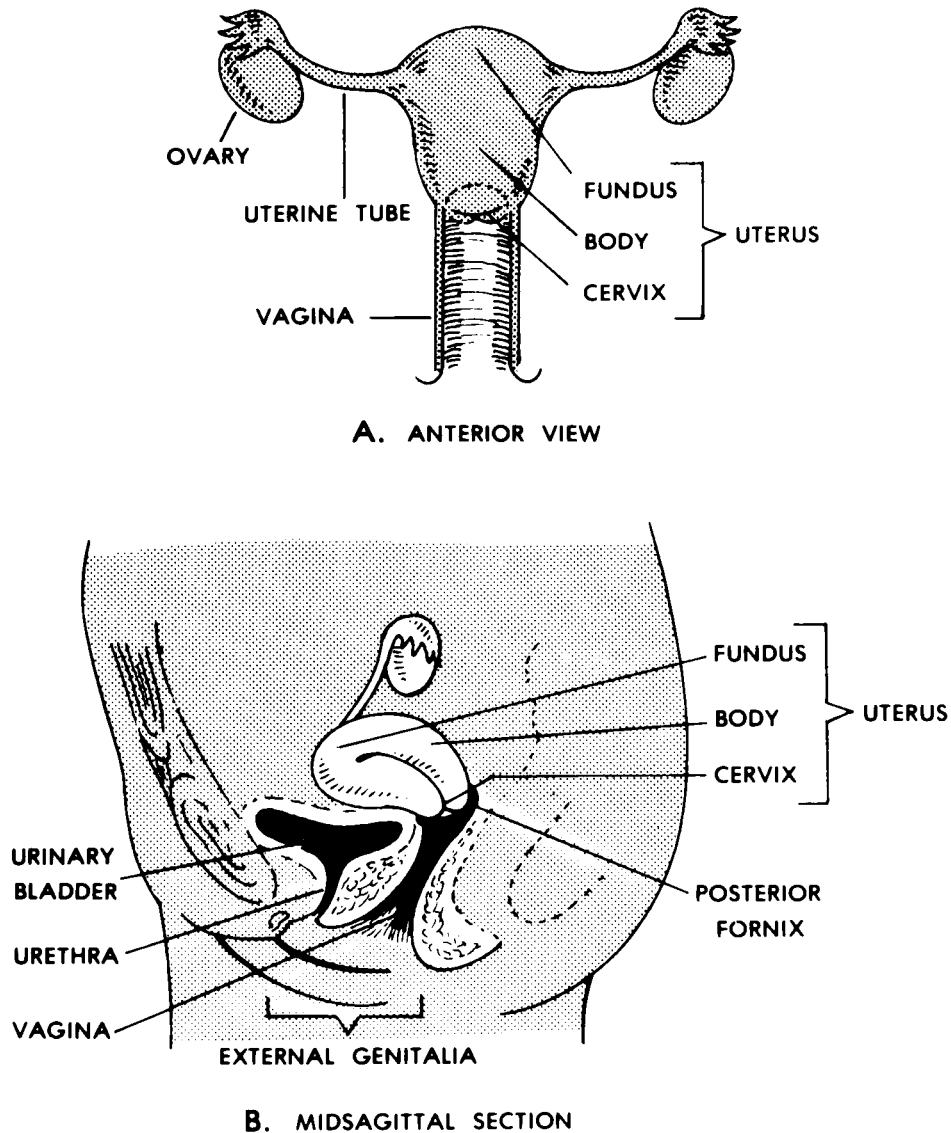


Figure 8-4. The human female genital system.

b. **Uterus.** The uterus is the site where all but the first few days of embryo development takes place. After eight weeks of embryonic development, it is known as the fetus.

(1) Main subdivisions. The uterus is shaped like a pear, with the stem (cervix) facing downward and toward the rear. The fundus is the portion of the uterus above the openings of the uterine tubes. The main part, or body, is the portion between the cervix and the fundus. The uterus usually leans forward with the body slightly curved as it passes over the top of the urinary bladder. The cervix opens into the upper end of the vagina.

(2) Wall structure. The inner lining of the uterus is called the endometrium. Made up of epithelium, it is well supplied with blood vessels and glands. The muscular wall of the uterus is called the myometrium. In the body of the uterus, the muscular tissue is in a double spiral arrangement. In the cervix, it is in a circular arrangement.

(3) Age differences. The uterus of an infant female is undeveloped. During puberty, the uterus develops. The uterus of an adult is fully developed. The uterus of an old woman is reduced in size and nonfunctional.

c. **Vagina**. The vagina is a tubular canal connecting the cervix of the uterus with the outside. It serves as a birth canal and as an organ of copulation. It is capable of stretching during childbirth. The lower opening of the vagina may be partially closed by a thin membrane known as the hymen.

d. **External Genitalia**. Other terms for the external genitals of the human female are vulva and pudendum. Included are the:

(1) Mons pubis. The mons pubis is a mound of fat tissue covered with skin and hair in front of the symphysis pubis (the joint of the pubic bones).

(2) Labia majora. Extending back from the mons pubis and encircling the vestibule (discussed below) are two folds known as the labia majora. Their construction is similar to the mons pubis, including fatty tissue and skin. The outer surfaces are covered with hair. The inner surfaces are moist and smooth. The corresponding structure in the male is the scrotum.

LABIA = lips (LABIUM, singular)

(3) Labia minora. The labia minora are two folds of skin lying within the labia majora and also enclosing the vestibule. In front, each labium minus (minus = singular of minora) divides into two folds. The fold above the clitoris (discussed below) is called the prepuce of the clitoris. The fold below is the frenulum.

(4) Clitoris. The clitoris is a small projection of sensitive erectile tissue which corresponds to the male penis. However, the female urethra does not pass through the clitoris.

(5) Vestibule. The cleft between the labia minora and behind the clitoris is called the vestibule. It includes the urethral opening in front and the vaginal opening slightly to the rear.

e. **Pregnancy and Delivery**. When an embryo forms an attachment to the endometrium, a pregnancy exists. The attachment eventually forms a placenta, an organ joining mother and offspring for such purposes as nutrition of the offspring. The fetal membranes surround the developing individual (fetus) and are filled with amniotic fluid.

(1) During the first eight weeks, the developing organism is known as an embryo. During this time, the major systems and parts of the body develop.

(2) During the remainder of the pregnancy, the developing organism is known as the fetus. During this time, growth and refinement of the body parts occur.

(3) Parturition is the actual delivery of the fetus into a free- living state. The delivery of the fetus is followed by a second delivery-- that of the placenta and fetal membranes.

f. **Menstruation and Menopause.** About two weeks after an ovum is released, if it is not fertilized, menstruation occurs. Menstruation involves the loss of all but the basal layer of the endometrium. This process includes bleeding. It first occurs at puberty and lasts until menopause (45 to 55 years of age). After menopause, pregnancy is no longer possible.

8-12. SECONDARY SEXUAL CHARACTERISTICS

The secondary sexual characteristics of females include growth of pubic hair, development of mammary glands, development of the pelvic girdle, and deposition of fat in the mons pubis and labia majora.

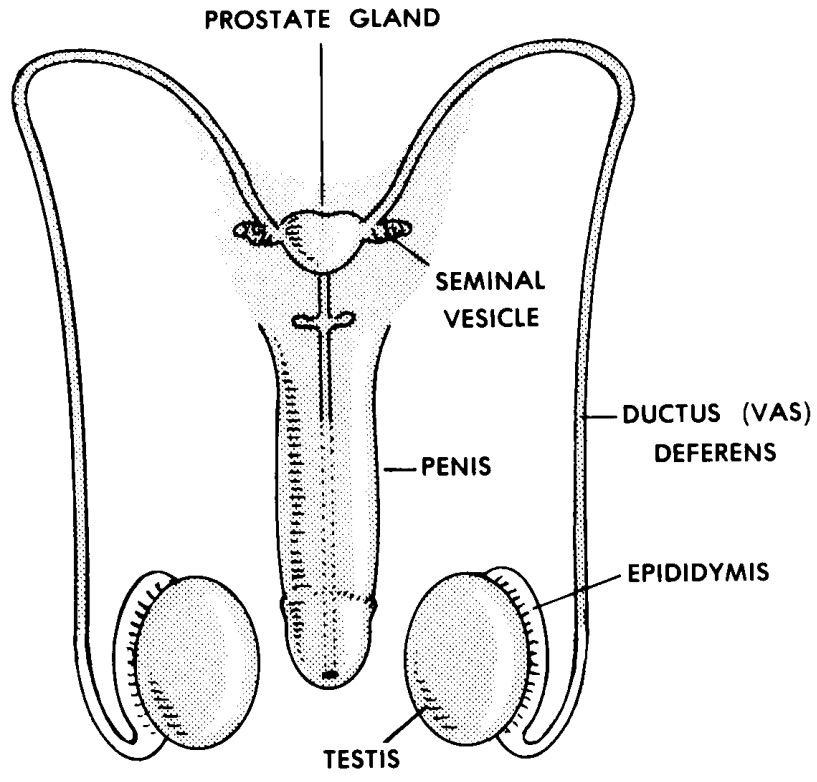
8-13. MAMMARY GLANDS

The mammary glands were previously mentioned in [paragraph 3-6c](#). Secretion of milk begins after parturition. Stimulation from suckling helps to maintain the normal rate of milk secretion. At the time of menopause, breast tissue becomes less prominent.

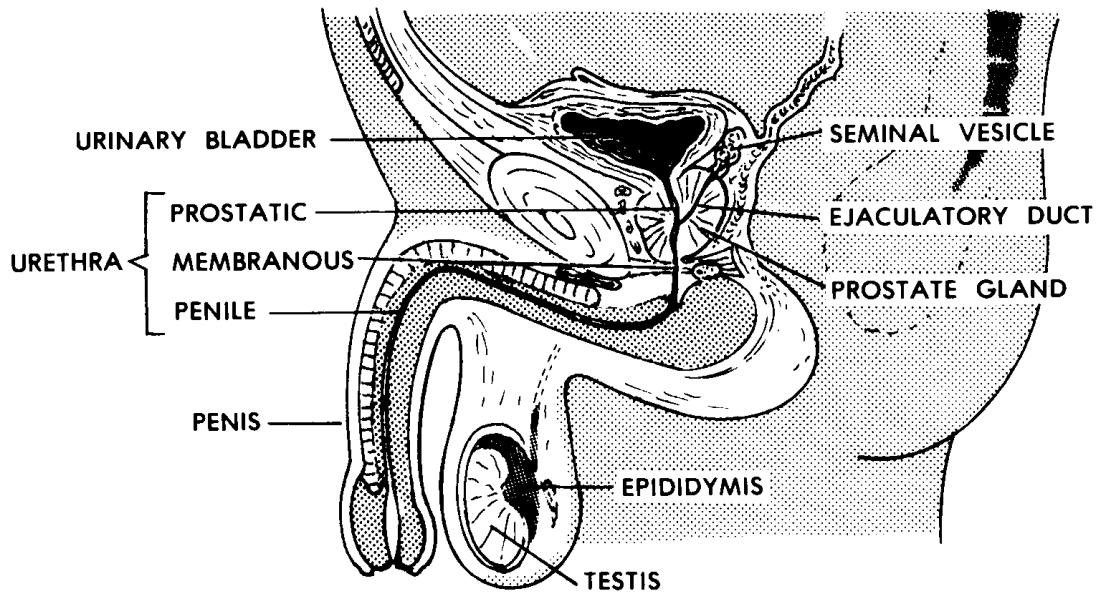
Section IV. THE HUMAN MALE GENITAL (REPRODUCTIVE) SYSTEM

8-14. PRIMARY SEX ORGANS (TESTES)

The primary sex organ of the human male is the testis. See figure 8-5 for an illustration of the male genital system. The testes are egg-shaped.



A. SCHEME OF ANTERIOR VIEW



B. MIDSAGITTAL SECTION

Figure 8-5. The human male genital system.

a. **Location.** The paired testes lie within the scrotum. The scrotum is a sac of loose skin attached in the pubic area of the lower abdomen. The scrotum provides a site cooler than body temperature to maintain the viability of the spermatozoa. However, when the air is too cold, muscles and muscular fibers draw the testes and scrotum closer to the body to maintain warmth. Otherwise, the scrotum hangs loosely. The tunica vaginalis is a serous cavity surrounding each testis.

b. **Functions.** The testis produces the male sex cells called spermatozoa (spermatozoon, singular). The spermatozoa are continuously produced by the millions. One such cell may eventually fertilize an ovum of a human female. The testes also produce male sex hormones called androgens.

8-15. SECONDARY SEX ORGANS

a. **Epididymis.** The epididymis is a coiled tube whose function is to aid in the maturation of spermatozoa. Its coiled length is only about one and one-half inches. Its uncoiled length is about 16 feet. When coiled, it extends downward along the posterior side of each testis. Its lining secretes a nutritive medium for spermatozoa. It receives spermatozoa from the testes in an immature state. As the spermatozoa pass through the nutrient, they mature.

b. **Ductus (Vas) Deferens.** The ductus deferens is a transporting tube which carries the mature sperm from the epididymis to the prostate. Each tube enters the abdomen through the inguinal canal. Each passes over a ureter to reach the back of the urinary bladder and then down to the prostate gland.

c. **Seminal Vesicles.** Lying alongside each ductus deferens as it crosses the back of the bladder is a tubular structure called the seminal vesicle. The seminal vesicle produces a fluid which becomes part of the ejaculate.

d. **Ejaculatory Duct.** Each ductus deferens and its corresponding seminal vesicle converge to form a short tube called the ejaculatory duct. The ejaculatory duct opens into the urethra within the prostate gland. The ejaculatory duct carries both spermatozoa and seminal vesicle fluid.

e. **Prostate Gland.** As the urethra leaves the urinary bladder, its first inch is surrounded by a chestnut-size gland called the prostate gland. The prostate gland provides an additional fluid to be added to the spermatozoa and seminal vesicle fluid.

f. **Penis.** As the urethra leaves the abdomen, it passes through the penis, the male organ of copulation.

(1) Surrounding the urethra is a central cylinder of erectile tissue called the corpus spongiosum. This cylinder is bulb-shaped at each end. The posterior end is attached to the base of the pelvis. The sensitive anterior end is known as the glans.

CORPUS SPONGIOSUM = spongy body

(2) Overlying the corpus spongiosum is a pair of cylinders of erectile tissue called the corpora cavernosa. These two cylinders are separate in their proximal fourth and joined in their distal three-fourths. They are attached to the pubic bones. Together, the corpus spongiosum and the corpora cavernosa combine to form the shaft of the penis.

CORPUS CAVERNOSUM = cavernous body

(3) The prepuce, or foreskin, is a covering of skin for the glans. It may be removed in a surgical procedure called circumcision.

8-16. SECONDARY SEXUAL CHARACTERISTICS

The secondary sexual characteristics of male include growth of facial, pubic, and chest hair; growth of the larynx to deepen the voice; and deposition of protein to increase muscularity and general body size.

Continue with Exercises

EXERCISES, LESSON 8

REQUIREMENT. The following exercises are to be answered by completing the incomplete statement or by writing the answer in the space provided at the end of the question.

After you have completed all the exercises, turn to "Solutions to Exercises," at the end of the lesson and check your answers.

1. The human urogenital systems are made up of the u_____, organs, which produce the fluid called _____, and the _____, or _____, organs of male and female humans, which together can produce a new human.

2. The urinary system is specialized to remove certain _____ from the circulating blood. These result from the body's use of _____.

3. The major parts of the human urinary system are two _____, two _____, one _____, and one _____.

4. On the concave, medial side of each kidney, there is a notch called the _____. Through this notch pass the _____ and the _____ which service the kidney.

5. If we compare the structure of the kidney with that of a cantaloupe, the structure corresponding to the hard rind would be the _____. The structure corresponding to the edible flesh of the melon would be the _____. Corresponding to the hollow center (after removal of the seeds) would be the _____. The pyramids of the renal medulla form peaks called _____, which empty into the _____.

6. The functional unit of the human kidney is the _____. Its main subdivisions are the _____ and a _____ system.

7. The renal corpuscle is composed of the _____ and the _____. Blood enters by way of the _____ arteriole, passes through the tangled mass of capillaries called the _____, and leaves by way of the _____ arteriole. Leaving the blood, fluid is first collected in the double-walled sac called the _____.

8. The first coiled portion of the renal tubule is known as the _____ . The hairpin-shaped portion of the renal tubule is known as the _____. The second coiled portion is known as the _____.

9. The distal convoluted tubules of several nephrons empty into a _____ tubule. The urine is then passed from the collecting tubule at the _____ of the medullary pyramid. Several collecting tubules are present in each _____. There is a hollow sac within the sinus of the kidney called the _____. The ureter then drains the urine from the _____.

10. What are ureters?

What mechanism is used by ureters to move urine?

11. The urinary bladder is a muscular organ for _____ing the urine. The triangular base of the urinary bladder is known as the _____. The two posterior corners of the trigone are the points where the _____ empty into the bladder. The anterior corner of the trigone is the opening of the _____. Nerve endings stimulated by the stretching of the bladder walls are known as _____.

12. What is the urethra?

At what part of the urinary bladder does the urethra begin?

There is an _____ urethral sphincter and an _____ urethral sphincter. The internal urethral sphincter is located in the _____ of the urinary bladder. It is controlled by nerves of the _____ nervous system. The external urethral sphincter is more inferior, in the area of the _____. It is controlled by nerves of the _____ nervous system.

13. The female urethra is _____ and _____. The male urethra is much longer and has two _____. The female urethra serves only a _____ function. The male urethra serves both the _____ and _____ functions.

14. Since there are different genital systems for males and females, genital systems are an example of _____.

15. Primary sex organs produce _____ cells (_____). Primary sex organs also produce _____.

What do secondary sex organs do?

Secondary sexual characteristics help to ensure mating by _____.

16. The primary sex organ of the human female is the _____. The ovaries are located to the sides of the upper end of the _____. They are anchored to the posterior surface of the _____. The broad ligaments are sheets or folds of _____ enclosing the _____ and uterine _____ and extending to the sides of the _____. The ovary produces the egg cell or _____. The ovary produces chemicals called female sex _____ (_____ and _____). One ovum is released in each _____ period.

17. Uterine tubes are two muscular tubes which extend to either side of the _____ and open at the outer ends. Fringe-like appendages encircle the _____. At their medial ends, the uterine tubes open into the _____. The function of a uterine tube is to _____ and hold it until (a) it is _____ OR (b) the nutrient is _____ and the ovum _____.

18. The uterus is the site for all but the first few days of the development of the _____. The uterus is shaped like a _____. The stem, or _____, faces _____. It opens into the _____. The uterus leans anteriorly with the body slightly curved as the body passes over the top of the _____.

19. The inner lining of the uterus is called the _____. The muscular wall of the uterus is called the _____.

20. The vagina is a tubular canal connecting the _____ of the _____ with the outside. The vagina serves as a _____ and as an organ of _____.

21. The external genitalia of the human female include the _____, the _____, the _____, the _____, and the _____.

22. The mons pubis is a mound of _____ tissue, covered with _____ and _____, in front of the s_____ p_____.

23. The labia majora are two folds of _____ tissue and _____ which extend back from the _____ and encircle the _____. The outer surfaces are covered with _____. The inner surfaces are _____ and _____.

24. The labia minora are two folds of skin lying within the _____ and also enclosing the _____.

25. What is the clitoris?

26. During the first eight weeks of pregnancy, the developing organism is known as a(n) _____. Thereafter, the developing organism is known as a(n) _____. At the time of birth, the second delivery is that of the _____ and f_____ m_____.

27. The secondary sexual characteristics of females include growth of _____ hair, development of _____ glands, development of the _____ girdle, and deposition of fat in the _____ and _____.

28. The primary sex organ of the human male is the _____. The testes are shaped like _____. Their location is within the _____. The scrotum is a sac of loose _____ attached in the _____ area of the lower abdomen.

How does the scrotum affect the temperature of the spermatozoa?

The testis produces the male sex cells called _____. The testis also produces chemicals, or _____, called _____.

29. The epididymis is a coiled _____ whose function is to aid in the _____ of _____. Its lining secretes a _____ medium for _____. As the spermatozoa pass through the nutrient, they _____.

30. The ductus deferens is a _____ing tube which carries the _____ from the _____ to the _____. Each tube enters the abdomen through the _____. Each tube passes over a _____ to reach the back of the _____ and then down to the _____.

31. Lying alongside each ductus deferens as it crosses the bladder is a tubular structure called the _____.

32. The prostate gland is a _____-size gland that surrounds the first inch of the _____ as it leaves the _____. It provides an additional fluid to be added to the _____ and _____ fluid.

33. The penis is the male organ of _____. Passing through the penis is the _____. The penis has a central cylinder of erectile tissue called the _____. Each end of this cylinder is _____-shaped. The sensitive anterior end is known as the _____.

What are the corpora cavernosa?

When present, a covering of skin for the glans is called the _____ or _____.

34. The secondary characteristics of males include growth of _____, _____, and _____ hair; growth of the _____ to deepen the voice; and deposition of protein to increase _____y and general body size.

Check Your Answers on Next Page

SOLUTIONS TO EXERCISES, LESSON 8

1. The human urogenital systems are made up of the urinary organs, which produce the fluid called urine, and the genital, or reproductive, organs of male and female humans, which together can produce a new human. (para 8-1)
2. The urinary system is specialized to remove certain nitrogenous waste products from the circulating blood. These result from the body's use of proteins. (para 8-2a)
3. The major parts of the human urinary system are two kidneys, two ureters, one urinary bladder, and one urethra. (para 8-2b)
4. On the concave, medial side of each kidney there is a notch called the hilus. Through this notch pass the ureter and the NAVL which service the kidney. (para 8-3a(2))
5. If we compare the structure of the kidney with that of a cantaloupe, the structure corresponding to the hard rind would be the renal cortex. The structure corresponding to the edible flesh of the melon would be the renal medulla. Corresponding to the hollow center (after removal of the seeds) would be the renal sinus. The pyramids of the renal medulla form peaks called papillae, which empty into the renal sinus. (para 8-3b)
6. The functional unit of the human kidney is the nephron. Its main subdivisions are the renal corpuscle and a tubular system. (para 8-3c)
7. The renal corpuscle is composed of the glomerulus and the renal capsule. Blood enters by way of the afferent arteriole, passes through the tangled mass of capillaries called the glomerulus, and leaves by way of the efferent arteriole. Leaving the blood, fluid is first collected in the double-walled sac called the renal capsule. (para 8-3c)
8. The first coiled portion of the renal tubule is known as the proximal convoluted tubule. The hairpin-shaped portion of the renal tubule is known as the renal loop (of Henle). The second coiled portion is known as the distal convoluted tubule. (para 8-3c(2))
9. The distal convoluted tubules of several nephrons empty into a collecting tubule. The urine is then passed from the collecting tubule at the papilla of the medullary pyramid. Several collecting tubules are present in each pyramid. There is a hollow sac within the sinus of the kidney called the renal pelvis. The ureter then drains the urine from the renal pelvis. (paras 8-3d, e)
10. Ureters are tubes which connect the kidneys to the urinary bladder. The mechanism used by ureters to move urine is peristalsis. (para 8-4)

11. The urinary bladder is a muscular organ for storing the urine. The triangular base of the urinary bladder is known as the trigone. The two posterior corners of the trigone are the points where the ureters empty into the bladder. The anterior corner of the trigone is the opening of the urethra. Nerve endings stimulated by the stretching of the bladder walls are known as stretch receptors. (para 8-5)
12. The urethra is a tube conducting urine from the urinary bladder to the outside of the body. It begins at the anterior base of the urinary bladder. There is an internal urethral sphincter and an external urethral sphincter. The internal urethral sphincter is located in the floor of the urinary bladder. It is controlled by nerves of the autonomic nervous system. The external urethral sphincter is more inferior, in the area of the pelvic floor. It is controlled by nerves of the peripheral nervous system. (para 8-6a)
13. The female urethra is short and direct. The male urethra is much longer and has two curvatures. The female urethra serves only a urinary function. The male urethra serves both the urinary and reproductive functions. (para 8-6b)
14. Since there are different genital systems for males and females, genital systems are an example of sexual dimorphism. (para 8-7)
15. Primary sex organs produce sex cells (gametes). Primary sex organs also produce sex hormones. What do secondary sex organs do? Secondary sex organs care for the product of the primary sex organ. Secondary sexual characteristics help to ensure mating by making males and females more attractive to each other. (para 8-9)
16. The primary sex organ of the human female is the ovary. The ovaries are located to the sides of the upper end of the uterus. They are anchored to the posterior surface of the broad ligaments. The broad ligaments are sheets or folds of peritoneum enclosing the uterus and uterine tubes and extending to the sides of the pelvis. The ovary produces the egg cell or ovum. The ovary produces chemicals called female sex hormones (estrogens and progesterone). One ovum is released in each menstrual period. (para 8-10)
17. Uterine tubes are two muscular tubes which extend to either side of the uterus and open at the outer ends. Fringe-like appendages encircle the ovaries. At their medial ends, the uterine tubes open into the uterus. The function of a uterine tube is to pick up the ovum when it is released from the ovary and hold it until (a) it is fertilized, or (b) the nutrient is used up and the ovum dies. (para 8-11a)
18. The uterus is the site for all but the first few days of the development of the embryo and fetus. The uterus is shaped like a pear. The stem, or cervix, faces downward and to the rear. It opens into the upper end of the vagina. The uterus leans anteriorly with the body slightly curved as the body passes over the top of the urinary bladder. (para 8-11b)

19. The inner lining of the uterus is called the endometrium. The muscular wall of the uterus is called the myometrium. (para 8-11b(2))
20. The vagina is a tubular canal connecting the cervix of the uterus with the outside. The vagina serves as a birth canal and as an organ of copulation. (para 8-11c)
21. The external genitalia of the human female include the mons pubis, the labia majora, the labia minora, the clitoris, and the vestibule. (para 8-11d)
22. The mons pubis is a mound of fat tissue, covered with skin and hair, in front of the symphysis pubis. (para 8-11d(1))
23. The labia majora are two folds of fatty tissue and skin which extend back from the mons pubis and encircle the vestibule. The outer surfaces are covered with hair. The inner surfaces are moist and smooth. (para 8-11d(2))
24. The labia minora are two folds of skin lying within the labia majora and also enclosing the vestibule. (para 8-11d(3))
25. The clitoris is a small projection of erectile tissue corresponding to the male penis. (para 8-11d(4))
26. During the first eight weeks of pregnancy, the developing organism is known as an embryo. Thereafter, the developing organism is known as a fetus. At the time of birth, the second delivery is that of the placenta and fetal membranes. (para 8-11e)
27. The secondary sexual characteristics of females include growth of pubic hair, development of mammary glands, development of the pelvic girdle, and deposition of fat in the mons pubis and labia majora. (para 8-12)
28. The primary sex organ of the human male is the testis. The testes are shaped like eggs. Their location is within the scrotum. The scrotum is a sac of loose skin attached in the pubic area of the lower abdomen. The scrotum provides a site cooler than body temperature to maintain the viability of the spermatozoa. When the air is too cold, muscles and muscular fibers draws the testes and scrotum closer to the body to maintain warmth. Otherwise, the scrotum hangs loosely. The testis produces male sex cells called spermatozoa. The testis also produces chemicals, or male sex hormones, called androgens. (para 8-14)
29. The epididymis is a coiled tube whose function is to aid in the maturation of spermatozoa. Its lining secretes a nutritive medium for spermatozoa. As the spermatozoa pass through the nutrient, they mature. (para 8-15a)

30. The ductus deferens is a transporting tube which carries the mature sperm from the epididymis to the prostate. Each tube enters the abdomen through the inguinal canal. Each tube passes over a ureter to reach the back of the urinary bladder and then down to the prostate gland. (para 8-15b)
31. Lying alongside each ductus deferens as it crosses the back of the bladder is a tubular structure called the seminal vesicle. (para 8-15c)
32. The prostate gland is a chestnut-size gland that surrounds the first inch of the urethra as it leaves the urinary bladder. It provides an additional fluid to be added to the spermatozoa and seminal vesicle fluid. (para 8-15e)
33. The penis is the male organ of copulation. Passing through the penis is the urethra. The penis has a central cylinder of erectile tissue called the corpus spongiosum. Each end of this cylinder is bulb-shaped. The sensitive anterior end is known as the glans. The corpora cavernosa are a pair of cylinders of erectile tissue overlying the corpus spongiosum. When present, a covering of skin for the glans is called the prepuce or foreskin. (para 8-15f)
34. The secondary sexual characteristics of males include growth of facial, pubic, and chest hair; growth of the larynx to deepen the voice; and deposition of protein to increase muscularity and general body size. (para 8-16)

End of Lesson 8

LESSON ASSIGNMENT

LESSON 9

The Human Cardiovascular and Lymphatic Systems.

TEXT ASSIGNMENT

Paragraphs 9-1 through 9-10.

LESSON OBJECTIVES

After completing this lesson, you should be able to:

- 9-1. Name and briefly explain the four basic components of any circulatory system.
- 9-2. Define the human cardiovascular system, name its four major components, and match its components with the four basic components of any circulatory system.
- 9-3. Briefly describe plasma and the formed elements of the blood and state four general functions of blood.
- 9-4. Describe the general construction of a blood vessel; name three types of blood vessels; state the basic function of each type.
- 9-5. Describe the general construction of the human heart, including its auricles, atria, ventricles, septa, wall layers, variations of wall thickness, and the names, structures, and position of the cardiac valves.
- 9-6. Describe three different control systems regulating the heart beat.
- 9-7. Describe the coronary arteries and cardiac veins and their function.
- 9-8. Briefly describe the pericardium.
- 9-9. Describe cardiovascular circulatory patterns, including the terms collateral circulation, end artery, pulmonary cycle, and systemic cycle. Name the major arteries and veins of the human body and the areas serviced or supplies.

9-10. Briefly describe lymphatic capillaries, lymph vessels (including the thoracic duct), lymph nodes, and tonsils.

SUGGESTION

After completing the assignment, complete the exercises at the end of this lesson. These exercises will help you to achieve the lesson objectives.

LESSON 9

THE HUMAN CARDIOVASCULAR AND LYMPHATIC SYSTEMS

Section I. INTRODUCTION

9-1. NEED FOR CIRCULATORY SYSTEMS

a. The need for circulatory systems is based on two criteria:

(1) Number of cells. Multicellular animals are animals with a great number of cells.

(2) Size. In larger animals, most cells are too far away from sources of food and oxygen for simple diffusion to provide sufficient amounts. Also, distances are too great for simple removal of wastes.

b. Because of these criteria, we need a system (or systems) to carry materials to all cells. To get food and oxygen to the cells and to remove waste products, we need a transport system or circulatory system. Human circulatory systems are so effective that no cell is more than two cells away from a blood capillary.

9-2. BASIC COMPONENTS OF ANY CIRCULATORY SYSTEM

The four basic components of any circulatory system are a vehicle, conduits, a motive force, and exchange areas.

a. **Vehicle**. The vehicle is the substance which actually carries the materials being transported.

b. **Conduits**. A conduit is a channel, pipe, or tube through which a vehicle travels.

c. **Motive Force**. If we say that a force is motive, we mean that it produces movement. Systems providing a motive force are often known as pumps.

d. **Exchange Areas**. Since the materials being transported must eventually be exchanged with a part of the body, special areas are developed for this purpose. They are called exchange areas.

9-3. CIRCULATORY SYSTEMS IN THE HUMAN BODY

a. The cardiovascular system is the circulatory system involving the heart and blood vessels.

b. The lymphatic system is a drainage-type circulatory system involved with the clear fluid known as lymph.

c. There are other minor circulatory systems in the human body, such as the one involved with cerebrospinal fluid.

Section II. THE HUMAN CARDIOVASCULAR SYSTEM

9-4. GENERAL

The human cardiovascular system is a collection of interacting structures designed to supply oxygen and nutrients to living cells and to remove carbon dioxide and other wastes. Its major components are the:

a. **Blood.** Blood is the vehicle for oxygen, nutrients, and wastes.

b. **Blood Vessels.** Blood vessels are the conduits, or channels, through which the blood is moved.

c. **Heart.** The heart is the pump which provides the primary motive force.

d. **Capillaries.** The capillaries, minute (very small) vessels, provide exchange areas. For example, in the capillaries of the lungs, oxygen is added and carbon dioxide is removed from the blood.

9-5. BLOOD

Blood is the vehicle for the human cardiovascular system. Its major subdivisions are the plasma, a fluid containing proteins, and the formed elements, including red blood cells, white blood cells, and platelets.

a. Plasma.

(1) Plasma makes up about 55 percent of the total blood volume. It is mainly composed of water. A variety of materials are dissolved in plasma. Among the most important of these are proteins.

(2) After the blood clots, the clear fluid remaining is called serum. Serum does not contain the proteins used for clotting. Otherwise, it is very similar to plasma.

b. **Formed Elements.** The formed elements make up about 45 percent of the total blood volume. The formed elements are cellular in nature. While the red blood cells (RBCs) and white blood cells (WBCs) are cells, the platelets are only fragments of cells.

(1) Red blood cells (erythrocytes). RBCs are biconcave discs. That is, they are shaped something like an inner tube from an automobile tire, but with a thin middle portion instead of a hole. There are approximately 5,000,000 RBCs in a cubic millimeter of normal adult blood. RBCs contain hemoglobin, a protein which carries most of the oxygen transported by the blood.

(2) White blood cells (leukocytes). There are various types of WBCs, but the most common are neutrophils and lymphocytes. Neutrophils phagocytize (swallow up) foreign particles and organisms and digest them. Lymphocytes produce antibodies and serve other functions in immunity. In normal adults, there are about 5,000 to 11,000 WBCs per cubic millimeter of blood.

(3) Platelets. Platelets are about half the size of erythrocytes. They are fragments of cells. Since they are fragile, they last only about three to five days. Their main function is to aid in clotting by clumping together and by releasing chemical factors related to clotting. There are 150,000 - 350,000 platelets in a cubic millimeter of normal blood.

c. **Some General Functions of the Blood.**

(1) Blood serves as a vehicle for oxygen, nutrients, carbon dioxide and other wastes, hormones, antibodies, heat, etc.

(2) Blood aids in temperature control. Beneath the skin, there is a network of vessels that functions much like a radiator. To avoid accumulation of excess heat in the body, the flow of blood to these vessels can be increased greatly. Here, aided by the evaporative cooling provided by the sweat glands, large amounts of heat can be rapidly given off. The flow of blood also helps keep the outer parts of the body from becoming too cold.

(3) The blood aids in protecting our bodies by providing immunity. Some WBCs phagocytize (swallow up) foreign particles and microorganisms. Other WBCs produce antibodies. The blood transports antibodies throughout the body.

(4) Blood clotting is another function of blood. Not only does this prevent continued blood loss, it also helps prevent invasion of the body by microorganisms and viruses by sealing the wound opening.

9-6. BLOOD VESSELS

The blood is conducted or carried through the body by tubular structures known as blood vessels. Since at no time does the whole blood ever leave a blood vessel of some sort, we refer to this system as a closed system.

a. **General Construction.** The blood vessels in general are tubular and have a three-layered wall.

(1) Intima. The lumen (hollow central cavity) is lined by a layer of smooth epithelium known as the intima.

(2) Media. A middle layer of smooth muscle tissue is called the media.

(3) Adventitia. The adventitia is the outer layer of fibrous connective tissue that holds everything together.

b. **Types of Blood Vessels.** See figure 9-1 for a diagram of the human circulatory system. We recognize three types of blood vessels:

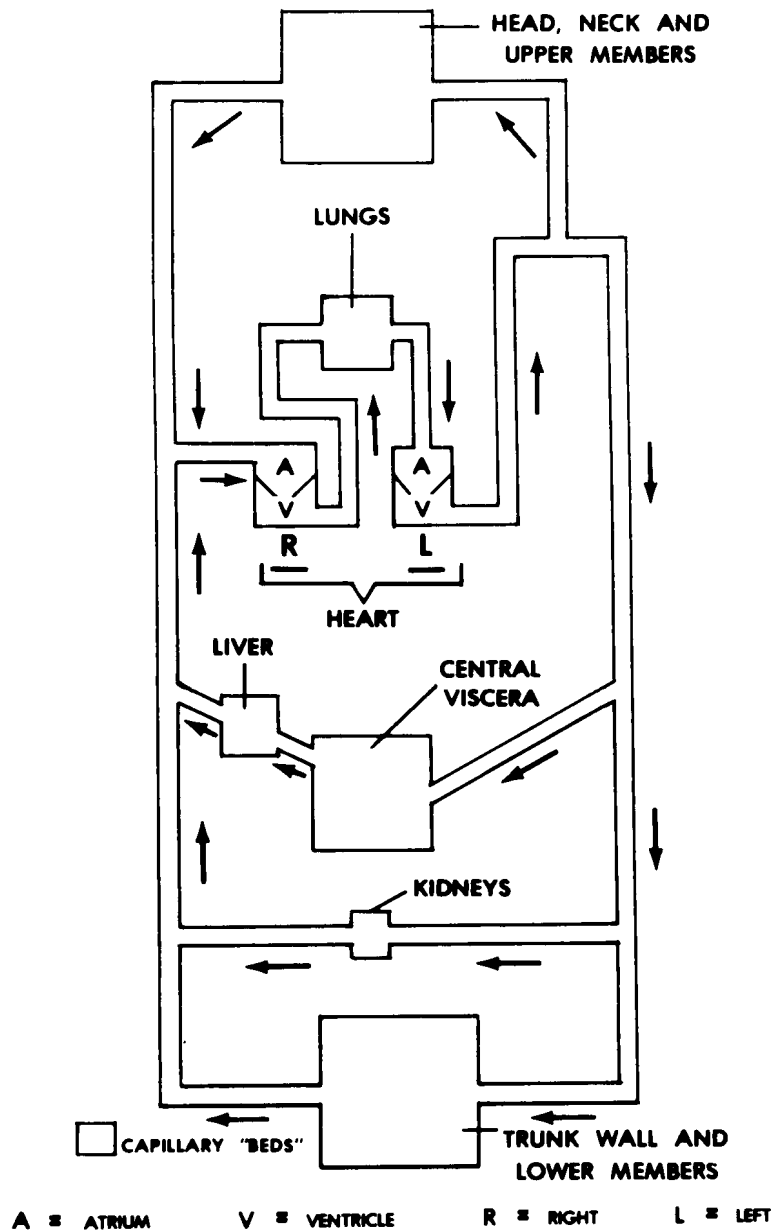


Figure 9-1. Scheme of blood vessels.

(1) The arteries carry blood away from the chambers of the heart.

(2) The veins carry blood to the chambers of the heart.

(3) Capillaries are extremely thin-walled vessels having only the intimal layer through which exchanges can take place between the blood and the tissue cells.

c. **Relationships.** Arteries and veins are largest where they are closest to the heart. Away from the heart, they branch into smaller and smaller and more numerous vessels. The branching continues until the smallest arteries (arterioles) empty into the capillaries. The capillaries in turn are drained by the venules of the venous system.

d. **Valves.** Within the heart and the veins are structures known as valves. Valves function to insure that the blood flows in only one direction.

9-7. THE HEART

Through the action of its very muscular walls, the heart produces the primary motive force to drive the blood through the arterial system. In humans, the heart is located just above the diaphragm, in the middle of the thorax, and extending slightly to the left. It is said that the heart of an average individual is about the size of that individual's clenched fist.

a. **General Construction of the Human Heart.** See figure 9-2 for an illustration of the human heart.

(1) Chambers. The heart is divided into four cavities known as the chambers. The upper two chambers are known as the atria, right and left. Each atrium has an ear-like projection known as an auricle. The lower two chambers are known as ventricles, right and left. Between the two atria is a common wall known as the interatrial septum. Between the two ventricles is a common wall known as the interventricular septum.

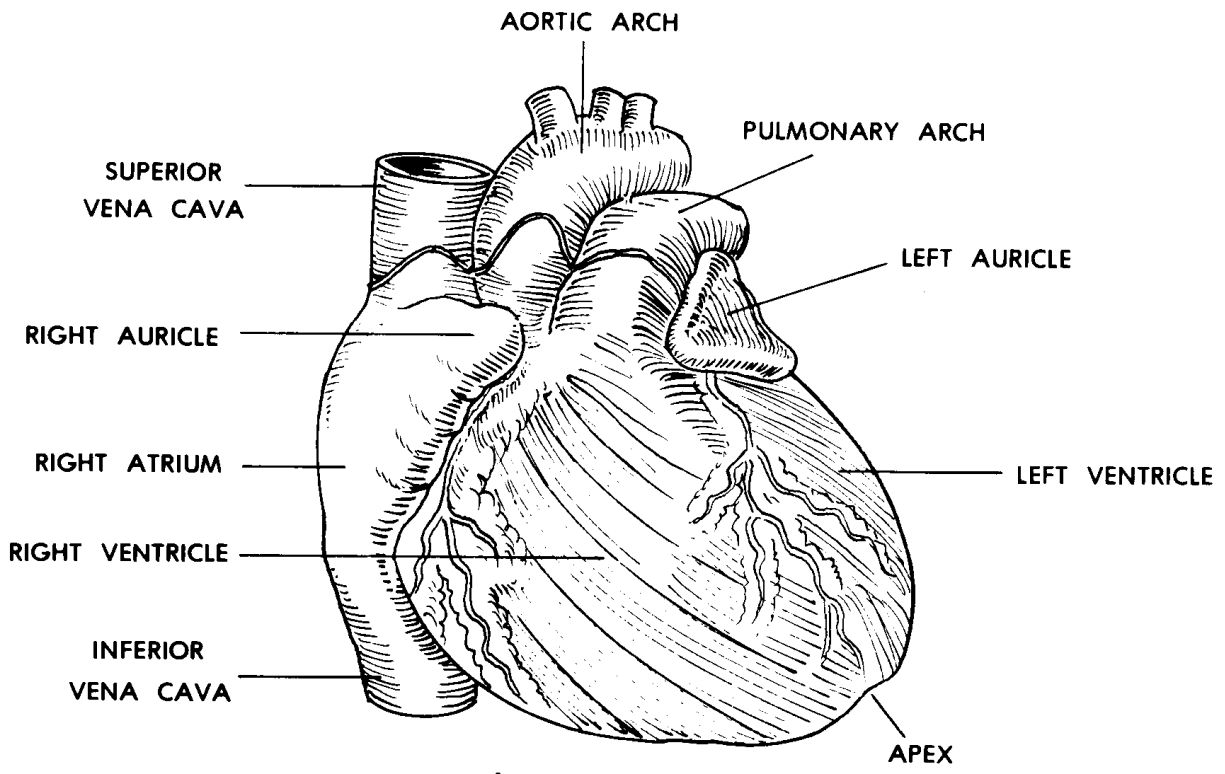
ATRIUM = hall

AURICLE = ear-like flap

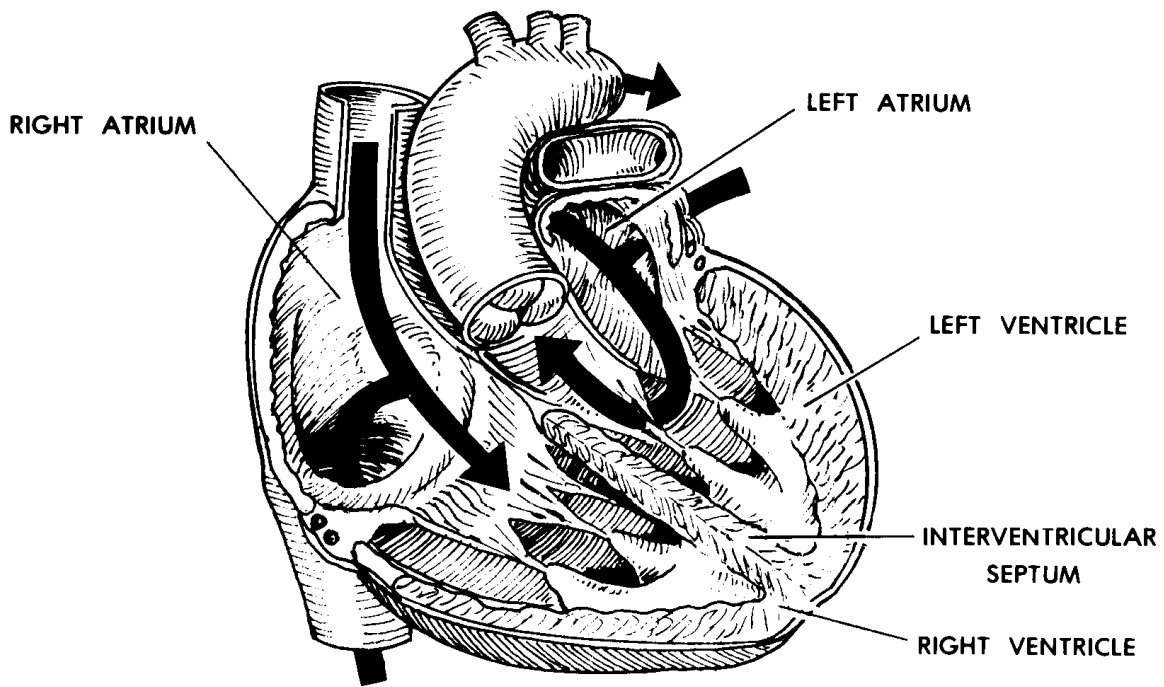
VENTER = belly

SEPTUM = fence

(2) Wall layers. The walls of the chambers are in three general layers. Lining the cavity of each chamber is a smooth epithelium known as the endocardium. (Endocarditis is an inflammation of the endocardium.) The middle layer is made up of cardiac muscle tissue and is known as the myocardium. The outer layer of the heart is another epithelium known as the epicardium.



A. ANTERIOR VIEW



B. INTERIOR VIEW

Figure 9-2. The human heart.

(3) Relationship of wall thickness to required pressure levels. A cross-section of the chambers shows that the atrial walls are relatively thin. The right ventricular wall is much thicker. The left ventricular wall is three to five times thicker than that of the right. These differences in wall thickness reflect the amount of muscle tissue needed to produce the amount of pressure required of each chamber.

(4) Cardiac valves (figure 9-3).

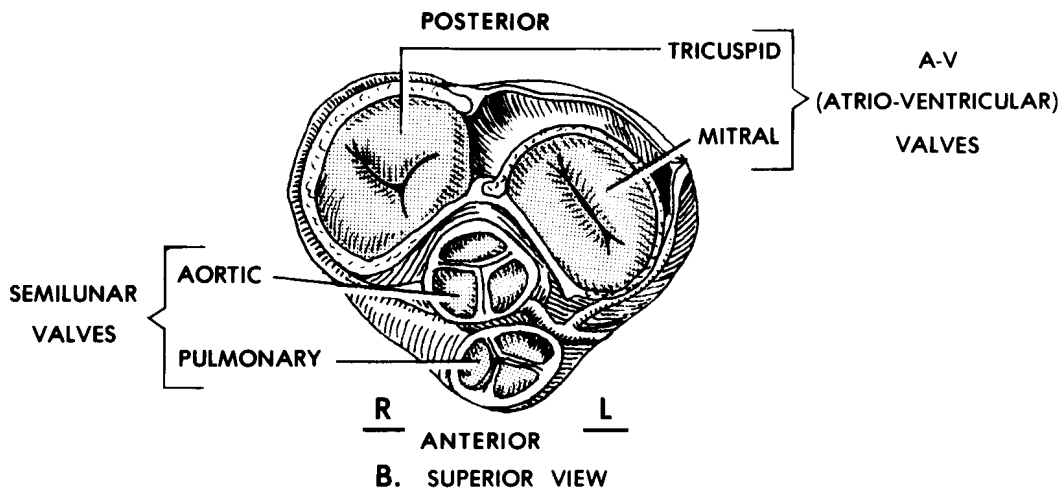
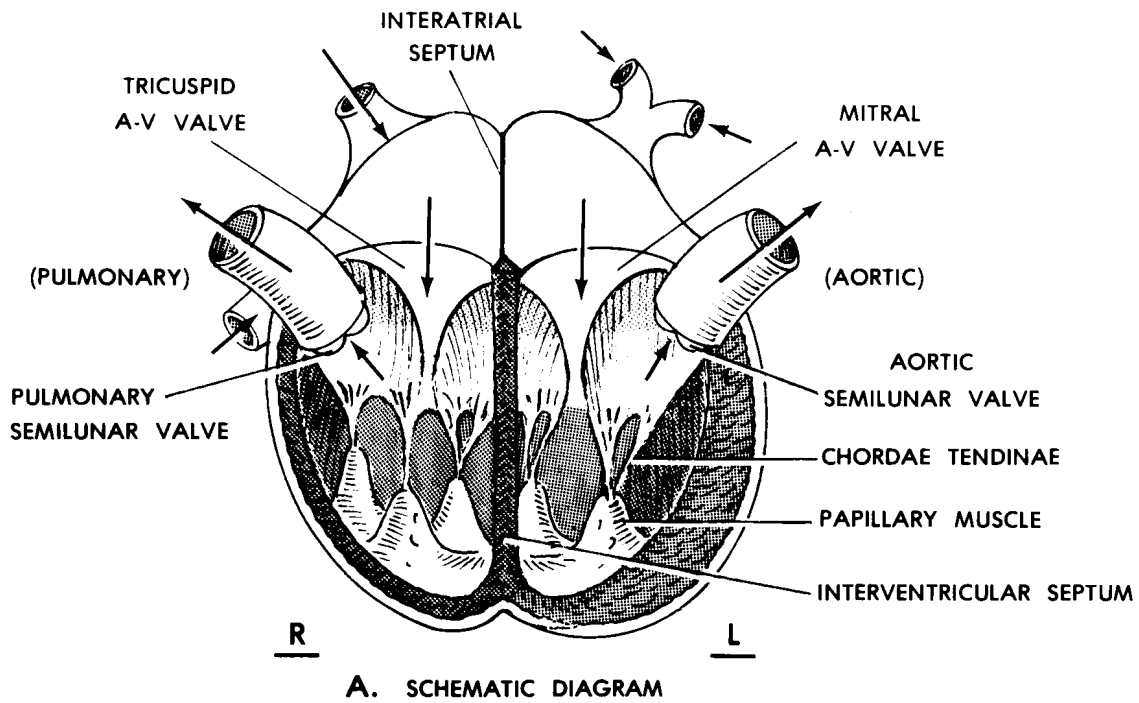


Figure 9-3. Scheme of heart valves.

(a) Between the atrium and ventricle of each side is the atrioventricular (A-V) valve. Each A-V valve prevents the blood from going back into the atrium from the ventricle of the same side. The right A-V valve is known as the tricuspid valve. The left A-V valve is known as the mitral valve. ("Might is never right.") The leaflets (flaps) of the A-V valves are prevented from being pushed back into the atria by fibrous cords. These fibrous cords are attached to the underside (the ventricular side) of the leaflets and are called chordae tendineae. At their other ends, the chordae tendineae are attached to the inner walls of the ventricles by papillary muscles.

(b) A major artery leads away from each ventricle--the pulmonary trunk from the right ventricle and the aortic arch from the left ventricle. A semilunar valve is found at the base of each of the pulmonary trunk and the aortic arch. These semilunar valves prevent blood from flowing back into the ventricles. The pulmonary (semilunar) valve and the aortic (semilunar) valve are each made up of three semilunar ("pocket-like") cusps.

b. **Control of the Heart Beat.** The heart is under several different control systems--extrinsic nervous control, intrinsic nervous control, and humoral control.

(1) Extrinsic nervous control. Extrinsic nervous control is control from outside of the heart. Extrinsic control is exerted by nerves of the autonomic nervous system. The sympathetic cardiac nerves accelerate (speed up) the heart. The vagus parasympathetic nerve decelerates (slows down) the heart.

(2) Intrinsic "nervous" control. Intrinsic "nervous" control is control built within the heart. The intrinsic "nervous" system consists of the sinoatrial (S-A) node (often referred to as the "pacemaker"), the atrioventricular (A-V) node, and the septal bundles. The septal bundles spread through the walls of the ventricles, just beneath the endocardium. This combination of nodes and bundles initiates the heart beat automatically and transmits the impulse through the atria and the ventricles.

(3) Humoral control. In addition to the "nervous" control of heart action, it appears that there are substances in the blood itself which have varying effects on the functioning of the heart. Although these substances are not as yet well understood, they appear to have some importance. The transplanted heart seems to depend to a degree on this control mechanism, since much of its "nervous controls" have been lost for the initial period in the recipient's body.

c. **Coronary Arteries and Cardiac Veins.** We may say that the heart deals with two different kinds of blood flow--"functional" blood and "nutritive" blood. "Functional" blood is the blood that the heart works on or pushes with its motive force. However, the walls of the heart require nutrition that they cannot get directly from the blood within the chambers. "Nutritive" blood is supplied to these walls by the coronary arteries, right and left. The coronary arteries arise from the base of the aortic arch and are distributed over the surface of the heart. This blood is collected by the cardiac veins and empties into the right atrium of the heart. Should a coronary artery, or one of its branches,

become closed for whatever reason, that part of the heart wall formerly supplied nutrient blood by the closed vessel will very likely die.

d. **Pericardial Sac.** The average heart contracts in what is known as a heart beat, about 70-80 times a minute. To reduce the frictional forces that would be applied to its moving surfaces, the heart is enclosed in a special serous sac known as the pericardium ("around the heart").

9-8. CARDIOVASCULAR CIRCULATORY PATTERNS

See figure 9-4 for an illustration depicting cardiovascular circulatory patterns.

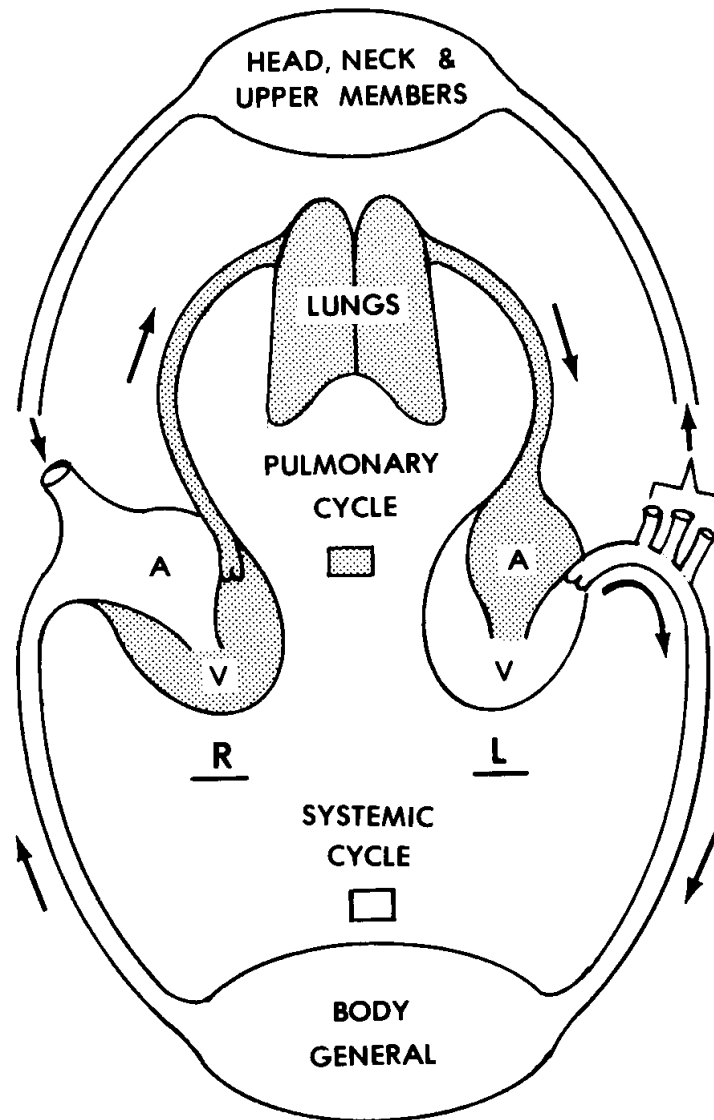


Figure 9-4. Cardiovascular circulatory patterns.

a. **General.** The human cardiovascular circulatory system is described as a closed, two-cycle system.

(1) It is closed because at no place is the blood as whole blood ever outside the system.

(2) It is two-cycle because the blood passes through the heart twice with each complete circuit of the body. In the pulmonary cycle, the blood passes from the right heart, through the lungs, and to the left heart. In the systemic cycle, the blood passes from the left heart, through the body in general, and returns to the right heart.

(3) It is common for an area of the body to be supplied by more than one blood vessel so that if one is damaged, the others will continue the supply. This is known as collateral circulation. However, there are situations, such as in the heart and the brain, where a single artery supplies a specific part of a structure. Such an artery is called an end artery. When an end artery is damaged, that area supplied by it will usually die, as in the case of the coronary artery (para 9-7c) above or in the case of a "stroke" in the brain.

b. **Pulmonary Cycle.** The pulmonary cycle begins in the right ventricle of the heart. Contraction of the right ventricular wall applies pressure to the blood. This forces the tricuspid valve closed and the closed valve prevents blood from going back into the right atrium. The pressure forces blood past the semilunar valve into the pulmonary trunk. Upon relaxation of the right ventricle, back pressure of the blood in the pulmonary trunk closes the pulmonary semilunar valve. The blood then passes into the lungs through the pulmonary arterial system. Gases are exchanged between the alveoli of the lungs and the blood in the capillaries next to the alveoli. This blood, now saturated with oxygen, is collected by the pulmonary veins and carried to the left atrium of the heart. This completes the pulmonary cycle.

c. **Systemic Cycle.**

(1) Left ventricle of the heart. The oxygen-saturated blood is moved from the left atrium into the left ventricle. When the left ventricular wall contracts, the pressure closes the mitral valve, which prevents blood from returning to the left atrium. The contraction of the left ventricular wall therefore forces the blood through the aortic semilunar valve into the aortic arch. Upon relaxation of the left ventricular wall, the back pressure of the aortic arch forces the aortic semilunar valve closed.

(2) Arterial distributions. The blood then passes through the various arteries to the tissues of the body. See figure 9-5 for an illustration of the main arteries of the human body.

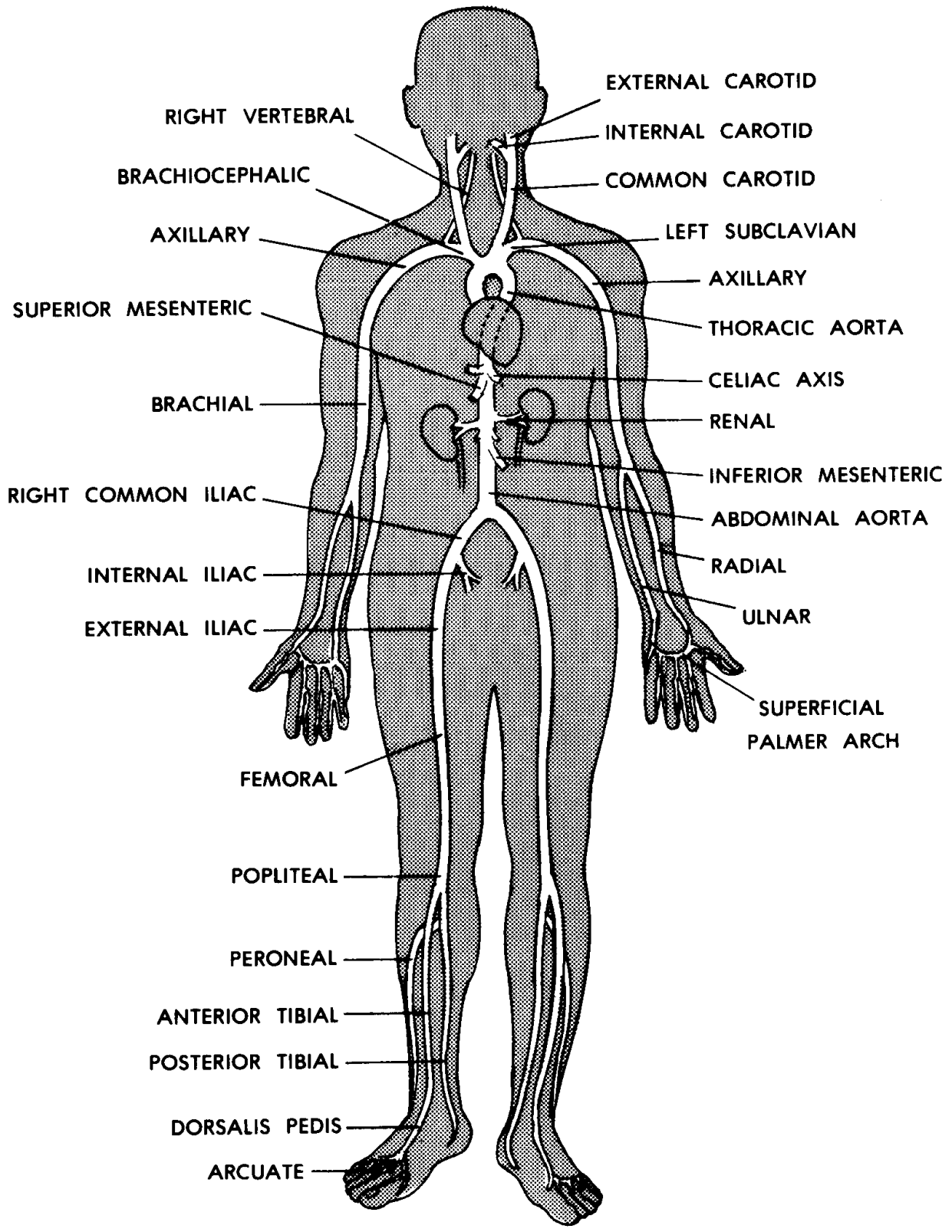


Figure 9-5. Main arteries of the human body.

(a) The carotid arteries supply the head. The neck and upper members are supplied by the subclavian arteries.

(b) The aortic arch continues as a large single vessel known as the aorta passing down through the trunk of the body in front of the vertebral column. It gives off branches to the trunk wall and to the contents of the trunk.

(c) At the lower end of the trunk, the aorta divides into right and left iliac arteries, supplying the pelvic region and lower members.

(3) Capillary beds of the body tissues. In the capillary beds of the tissues of the body, materials (such as food, oxygen, and waste products) are exchanged between the blood and the cells of the body.

(4) Venous tributaries. See figure 9-6 for an illustration of the main veins of the human body.

(a) The blood from the capillaries among the tissues is collected by a venous system parallel to the arteries. This system of deep veins returns the blood back to the right atrium of the heart.

(b) In the subcutaneous layer, immediately beneath the skin, is a network of superficial veins draining the skin areas. These superficial veins collect and then join the deep veins in the axillae (armpits) and the inguinal region (groin).

(c) The superior vena cava collects the blood from the head, neck, and upper members. The inferior vena cava collects the blood from the rest of the body. As the final major veins, the venae cavae empty the returned blood into the right atrium of heart.

(d) The veins are generally supplied with valves to assist in making the blood flow toward the heart. It is of some interest to note that the veins from the head do not contain valves.

(e) From that portion of the gut where materials are absorbed through the walls into the capillaries, the blood receives a great variety of substances. While most of these substances are useful, some may be harmful to the body. The blood carrying these substances is carried directly to the liver by the hepatic portal venous system. This blood is specially treated and conditioned in the liver before it is returned to the general circulation by way of the hepatic veins.

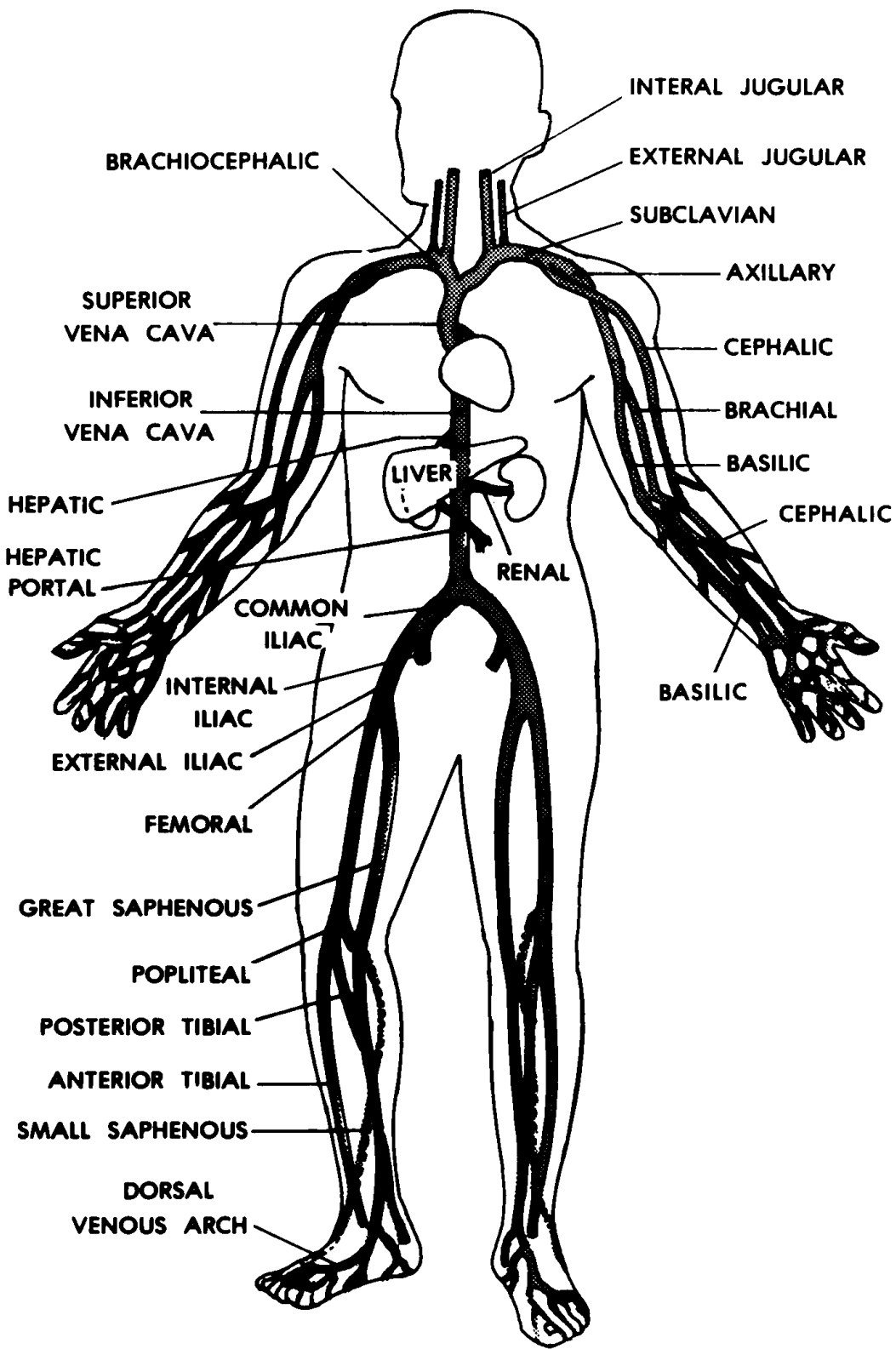


Figure 9-6. Main veins of the human body.

Section III. THE HUMAN LYMPHATIC SYSTEM

9-9. GENERAL

Between the cells of the body are spaces filled with fluid. This is the interstitial (or tissue) fluid, often referred to as intercellular fluid. There are continuous exchanges between the intracellular fluid, the interstitial fluid, and the plasma of the blood. The lymphatic system returns to the bloodstream the excess interstitial fluid, which includes proteins and fluid derived from the blood.

9-10. STRUCTURES OF THE HUMAN LYMPHATIC SYSTEM

See figure 9-7 for an illustration of the human lymphatic system.

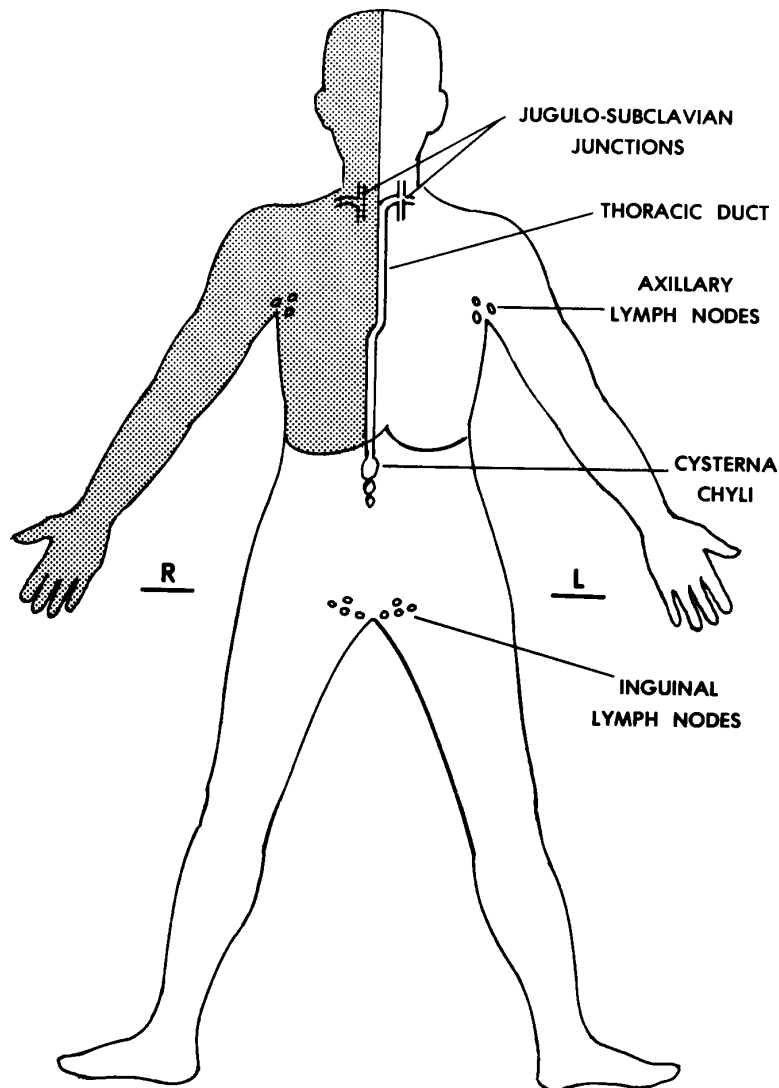


Figure 9-7. The human lymphatic system.

a. **Lymphatic Capillaries.** Lymphatic capillaries are located in the interstitial spaces. Here, they absorb the excess fluids.

b. **Lymph Vessels.** A tributary system of vessels collects these excess fluids, now called lymph. Like veins, lymphatic vessels are supplied with valves to help maintain a flow of lymph in one direction only. The lymphatic vessels, to a greater or lesser extent, parallel the venous vessels along the way. The major lymph vessel in the human body is called the thoracic duct. The thoracic duct passes from the abdomen up through the thorax and into the root of the neck in front of the vertebral column. The thoracic duct there empties into the junction of the left subclavian and jugular veins.

c. **Lymph Nodes.** Along the way, lymphatic vessels are interrupted by special structures known as lymph nodes. These lymph nodes serve as special filters for the lymph fluid passing through.

d. **Tonsils.** Tonsils are special collections of lymphoid tissue, very similar to a group of lymph nodes. These are protective structures and are located primarily at the entrances of the respiratory and digestive systems.

Continue with Exercises

EXERCISES, LESSON 9

REQUIREMENT. The following exercises are to be answered by completing the incomplete statement or by writing the answer in the space provided at the end of the question.

After you have completed all the exercises, turn to "Solutions to Exercises," at the end of the lesson and check your answers.

1. The four basic components of any circulatory system are a _____, _____s, a _____, and _____s. The vehicle is the substance which actually _____.
A conduit is a _____ through which a vehicle _____s. If we say that a force is motive, we mean that it _____. Systems providing a motive force are often known as _____. Exchange areas exist so that materials being transported may be eventually _____.

2. The human cardiovascular system is a collection of interacting _____s designed to supply _____ and _____ to living _____s and to remove _____ and other wastes. Its four major components are the _____, _____, _____ and _____. The vehicle is the _____. The conduits are the _____. The primary motive force is provided by the _____. The exchange areas are provided by minute vessels called _____.

3. The major subdivisions of blood are the _____ and the _____. Plasma makes up about ___ percent of the total blood volume. Plasma is mainly composed of _____. Among the most important materials dissolved in plasma are _____s. After the blood clots, the clear fluid remaining is _____, which does not contain the proteins used for _____. Otherwise, it is very similar to _____.

4. The formed elements of the blood make up about ___ percent of the total blood volume. While red blood cells and white blood cells are cells, the platelets are only _____ of cells.

What is the shape of an RBC? B_____ d_____.

In a cubic millimeter of normal adult blood, there are about how many RBCs?

RBCs contain a protein called _____ which transports most of the oxygen carried by the blood.

5. The most common types of white blood cells are _____ and _____. Neutrophils p_____ foreign particles and organisms. Lymphocytes produce _____s.

In a cubic millimeter of normal adult blood, there are about how many WBCs?

6. The main function of platelets is to aid in clotting by _____ing and by releasing c_____ f_____s related to clotting.

In a cubic millimeter of normal blood, there are about how many platelets?

7. Four general functions of blood are:

a. _____.

b. _____.

c. _____.

d. _____.

8. The inner, smooth epithelial layer of a blood vessel is called the i_____. The middle layer of smooth muscle tissue is called the m_____. The outer layer of FCT is the a_____.

9. The three types of blood vessels are _____, _____, and _____. The arteries carry blood away from _____. The veins carry blood toward the _____. Capillaries have extremely thin walls so that exchanges can take place between the _____ and _____.

10. What are the heart chambers?

What are the atria?

Each atrium has an ear-like projection known as an _____.

What are the ventricles? _____.

Between the two atria is a common wall known as the _____.
Between the two ventricles is a common wall known as the _____.

11. The three layers in the walls of the heart chambers are the _____m, the _____m, and the _____m. The inner layer is a smooth e_____. The middle layer is made up of cardiac _____ tissue. The outer layer is another e_____.

12. THIN OR THICK? The atrial walls are relatively _____. The right ventricular wall is much _____er than the atrial walls. The left ventricular wall is three to five times _____er than the right ventricular wall.

13. The valve between the atrium and ventricle of each side is the _____ (__) valve. The right A-V valve is known as the _____ valve. The left A-V valve is known as the _____ valve. The fibrous cords attached to the underside of the A-V valves are called _____. They are attached to the inner walls of the ventricles by _____ muscles. The valve at the base of the pulmonary trunk and the valve at the base of the aortic arch are both _____ valves, each with cusps. They are often called the _____ valve and the _____ valve.

14. Extrinsic nervous control of the heart is exerted by nerves of the _____ nervous system. Speeding the heart up are the _____ cardiac nerves. Slowing the heart down is the v_____ p_____ nerve. Intrinsic "nervous" control is built within the _____. It consists of the s_____ (__) node, the a_____ (__) nodes, and the s_____ b_____. For humoral control, there appears to be _____ which have varying effects upon the functioning of the heart.

15. The coronary arteries supply "_____" blood to the heart walls. The coronary arteries arise from the base of the _____ and are spread over the surface of the heart. This blood is collected by the _____ veins, which empty into the right _____ of the heart. If a coronary artery becomes closed, the receiving area of the heart will probably _____.

16. The pericardium is a special serous sac surrounding the _____ and reducing the _____l forces upon its moving surfaces.

17. The human cardiovascular system is closed because at no place is whole blood ever _____. It is two-cycle because the blood passes through the heart twice with each complete _____. In the pulmonary cycle, the blood passes from the _____ heart, through the _____, and to the _____ heart. In the systemic cycle, the blood passes from the _____ heart, through the _____, and returns to the _____ heart.

18. In the case of collateral circulation, if one blood vessel to an area is damaged, then _____. However, when an end artery is damaged, the receiving area will usually _____.

19. PULMONARY CYCLE:

In which chamber of the heart does the pulmonary cycle begin?

Contraction of the wall of the right ventricle forces the _____ valve to close. This keeps blood from flowing back into the _____. The pressure forces blood past the _____ valve into the _____. Upon relaxation of the right ventricle, back pressure of the blood in the pulmonary trunk closes the _____ valve. The blood then passes into the _____ through the pulmonary arterial system. Gases are exchanged between the _____ of the lungs and the blood in the _____ next to the alveoli. The oxygenated blood is collected by the _____ and carried to the _____ of the heart. This completes the pulmonary cycle.

20. SYSTEMIC CYCLE:

Oxygenated blood is moved from the left atrium into the _____. Contraction of the wall of the left ventricle closes the _____ valve, which prevents blood from returning to the _____. The pressure forces blood past the _____ valve into the _____. Upon relaxation of the left ventricular wall, back pressure of the blood in the aortic arch closes the _____ valve. The blood then passes through the various _____ to the _____. Materials are exchanged between the blood and cells of the body in the _____. The blood returns to the _____ of the heart in vessels called _____.

21. The head is supplied by the _____ arteries. The neck and upper members are supplied by the _____ arteries. The aortic arch continues as a large single vessel known as the _____. At the lower end of the trunk, the aorta divides into the right and left _____ arteries, supplying the pelvic region and lower members.

22. Running parallel to the arteries is the system of _____ veins. Immediately beneath the skin is a network of _____ veins. These veins collect and then join the deep veins in the _____ (armpits) and the _____ (groin). Collecting the blood from the head, neck, and upper members is the superior _____. Collecting the blood from the rest of the body is the _____. Thus, the final major veins, emptying the returned blood into the right atrium of the heart, are the _____. Except the veins from the head, veins are generally supplied with _____s to assist in making blood flow toward the heart. Carrying absorbed substances from the gut to the liver is the _____. After being specially treated and conditioned, this blood is returned to the general circulation by the _____ veins.

23. Located in the interstitial spaces, where they absorb excess interstitial fluid, are the lymphatics. A tributary system collects this fluid, now called lymph. To help maintain lymph flow in one direction, lymphatic vessels are supplied with valves. The major lymph vessel (which passes from the abdomen, up through the thorax, and into the root of the neck) is the inferior vena cava. Lymph nodes are special structures which interrupt lymphatic vessels and serve as special filters for the lymph fluid passing through. Tonsils are special collections of lymphoid tissue. They are immuneve structures located primarily at the junctionss of the respiratoryy and digestivee systems.

Check Your Answers on Next Page

SOLUTIONS TO EXERCISES, LESSON 9

1. The four basic components of any circulatory system are a vehicle, conduits, a motive force, and exchange areas. The vehicle is the substance which actually carries the materials being transported. A conduit is a channel, pipe, or tube through which a vehicle travels. If we say that a force is motive, we mean that it produces movement. Systems providing a motive force are often known as pumps. Exchange areas exist so that materials being transported may be eventually exchanged with a part of the body. (para 9-2)
2. The human cardiovascular system is a collection of interacting structures designed to supply oxygen and nutrients to living cells and to remove carbon dioxide and other wastes. Its four major components are the blood, blood vessels, heart, and capillaries. The vehicle is the blood. The conduits are the blood vessels. The primary motive force is provided by the heart. The exchange areas are provided by minute vessels called capillaries. (para 9-4)
3. The major subdivisions of blood are the plasma and the formed elements. Plasma makes up about 55 percent of the total blood volume. Plasma is mainly composed of water. Among the most important materials dissolved in plasma are proteins. After the blood clots, the clear fluid remaining is serum, which does not contain the proteins used for clotting. Otherwise, it is very similar to plasma. (para 9-5)
4. The formed elements of the blood make up about 45 percent of the total blood volume. While red blood cells and white blood cells are cells, the platelets are only fragments of cells. What is the shape of an RBC? Biconcave disc. In a cubic millimeter of normal blood, there are about 5,000,000 RBCs. RBCs contain a protein called hemoglobin, which transports most of the oxygen carried by the blood. (para 9-5b)
5. The most common types of white blood cells are neutrophils and lymphocytes. Neutrophils phagocytize foreign particles and organisms. Lymphocytes produce antibodies. In a cubic millimeter of normal adult blood, there are about 5,000 to 11,000 WBCs. (para 9-5b(2))
6. The main function of platelets is to aid in clotting by clumping together and by releasing chemical factors related to clotting. In a cubic millimeter of normal blood, there are about 150,000 - 350,000 platelets. (para 9-5b(3))
7. Four general functions of blood are:
 - a. Serving as a vehicle.
 - b. Aiding in temperature control.
 - c. Protecting our bodies by providing immunity.
 - d. Blood clotting. (para 9-5c)

8. The inner, smooth epithelial layer of a blood vessel is called the intima. The middle layer of smooth muscle tissue is called the media. The outer layer of FCT is the adventitia. (para 9-6a)
9. The three types of blood vessels are arteries, veins, and capillaries. The arteries carry blood away from the chambers of the heart. The veins carry blood toward the chambers of the heart. Capillaries have extremely thin walls so that exchanges can take place between the blood and tissue cells. (para 9-6b)
10. The heart chambers are the four cavities into which the heart is divided. The atria are the upper two chambers of the heart. Each atrium has an ear-like projection known as an auricle. The ventricles are the lower two chambers of the heart. Between the two atria is a common wall known as the interatrial septum. Between the two ventricles is a common wall known as the interventricular septum. (para 9-7a(1))
11. The three layers in the walls of the heart chambers are the endocardium, the myocardium, and the epicardium. The inner layer is a smooth epithelium. The middle layer is made up of cardiac muscle tissue. The outer layer is another epithelium. (para 9-7a(2))
12. The atrial walls are relatively thin. The right ventricular wall is much thicker than the atrial walls. The left ventricular wall is three to five times thicker than the right ventricular wall. (para 9-7a(3))
13. The valve between the atrium and ventricle of each side is the atrioventricular (A-V) valve. The right A-V valve is known as the tricuspid valve. The left A-V valve is known as the mitral valve. The fibrous cords attached to the underside of the A-V valves are called chordae tendineae. They are attached to the inner walls of the ventricles by papillary muscles. (para 9-7a(4)(a))

The valve at the base of the pulmonary trunk and the valve at the base of the aortic arch are both semilunar valves, each with three cusps. They are often called the pulmonary valve and the aortic valve. (para 9-7a(4)(b))

14. Extrinsic nervous control of the heart is exerted by nerves of the autonomic nervous system. Speeding the heart up are the sympathetic cardiac nerves. Slowing the heart down is the vagus parasympathetic nerve. (para 9-7b(1))

Intrinsic "nervous" control is built within the heart. It consists of the sinoatrial (S-A) node, the atrioventricular (A-V) node, and the septal bundles. (para 9-7b(2))

For humoral control, there appears to be substances in the blood itself which have varying effects upon the functioning of the heart. (para 9-7b(3))

15. The coronary arteries supply "nutritive" blood to the heart walls. The coronary arteries arise from the base of the aortic arch and are spread over the surface of the heart. This blood is collected by the cardiac veins, which empty into the right atrium of the heart. If a coronary artery becomes closed, the receiving area of the heart will probably die. (para 9-7c)
16. The pericardium is a special serous sac surrounding the heart and reducing the frictional forces upon its moving surfaces. (para 9-7d)
17. The human cardiovascular system is closed because at no place is whole blood ever outside the system. It is two-cycle because the blood passes through the heart twice with each complete circuit of the body. In the pulmonary cycle, the blood passes from the right heart, through the lungs, and to the left heart. In the systemic cycle, the blood passes from the left heart, through the body in general, and returns to the right heart. (para 9-8a)
18. In the case of collateral circulation, if one blood vessel to an area is damaged, then another blood vessel will continue the supply. However, when an end artery is damaged, the receiving area will usually die. (para 9-8a(3))
19. PULMONARY CYCLE: The pulmonary cycle begins in the right ventricle. Contraction of the wall of the right ventricle forces the tricuspid valve to close. This keeps blood from flowing back into the right atrium. The pressure forces blood past the pulmonary semilunar valve into the pulmonary trunk. Upon relaxation of the right ventricle, back pressure of the blood in the pulmonary trunk closes the pulmonary semilunar valve. The blood then passes into the lungs through the pulmonary arterial system. Gases are exchanged between the alveoli of the lungs and the blood in the capillaries next to the alveoli. The oxygenated blood is collected by the pulmonary veins and carried to the left atrium of the heart. (para 9-8b)
20. SYSTEMIC CYCLE: Oxygenated blood is moved from the left atrium into the left ventricle. Contraction of the wall of the left ventricle closes the mitral valve, which prevents blood from returning to the left atrium. The pressure forces blood past the aortic semilunar valve into the aortic arch. Upon relaxation of the left ventricular wall, back pressure of the blood in the aortic arch closes the aortic semilunar valve. The blood then passes through the various arteries to the tissues of the body. Materials are exchanged between the blood and cells of the body in the capillary beds. The blood returns to the right atrium of the heart in vessels called veins. (para 9-8c)
21. The head is supplied by the carotid arteries. The neck and upper members are supplied by the subclavian arteries. The aortic arch continues as a large single vessel known as the aorta. At the lower end of the trunk, the aorta divides into the right and left iliac arteries, supplying the pelvic region and lower members. (para 9-8c(2))

22. Running parallel to the arteries is the system of deep veins. Immediately beneath the skin is a network of superficial veins. These veins collect and then join the deep veins in the axillae (armpits) and the inguinal region (groin).
(paras 9-8c(4)(a)-(b))

Collecting the blood from the head, neck, and upper members is the superior vena cava. Collecting the blood from the rest of the body is the inferior vena cava. Thus, the final major veins, emptying the returned blood into the right atrium of the heart, are the venae cavae. (para 9-8c(4)(c))

Except the veins from the head, veins are generally supplied with valves to assist in making blood flow toward the heart. (para 9-8c(4)(d))

Carrying absorbed substances from the gut to the liver is the hepatic portal venous system. After being specially treated and conditioned, this blood is returned to the general circulation by the hepatic veins. (para 9-8c(4)(e))

23. Located in the interstitial spaces, where they absorb excess interstitial fluid, are the lymphatic capillaries. A tributary system collects this fluid, now called lymph. To help maintain lymph flow in one direction, lymphatic vessels are supplied with valves. The major lymph vessel (which passes from the abdomen, up through the thorax, and into the root of the neck) is the thoracic duct. Lymph nodes are special structures which interrupt lymphatic vessels and serve as special filters for the lymph fluid passing through. Tonsils are special collections of lymphoid tissue. They are protective structures located primarily at the entrances of the respiratory and digestive systems. (para 9-10)

End of Lesson 9

LESSON ASSIGNMENT

LESSON 10

The Human Endocrine System.

TEXT ASSIGNMENT

Paragraphs 10-1 through 10-18.

LESSON OBJECTIVES

After completing this lesson, you should be able to:

- 10-1. Define endocrine glands, hormones, target organs, and feedback mechanism.
- 10-2. Briefly describe three different control systems of the human body.
- 10-3. Briefly describe the endocrine system and name six better known endocrine organs.
- 10-4. Describe the pituitary body, including its location, its major subdivisions, and the origins and hormones of each subdivision.
- 10-5. Describe the location, structure, and hormone(s) for each of the following:
 - a. The thyroid gland.
 - b. The parathyroid glands.
 - c. The pancreatic islets.
 - d. The suprarenal glands.
- 10-6. Name the primary sex organs and the sex hormones for each gender.

SUGGESTION

After completing the assignment, complete the exercises at the end of this lesson. These exercises will help you to achieve the lesson objectives.

LESSON 10

THE HUMAN ENDOCRINE SYSTEM

Section I. INTRODUCTION

10-1. DEFINITIONS

ENDO = internal

CRINE = secrete

- a. The endocrine glands are glands of internal secretion (rather than external, as seen with the sweat glands and digestive glands).
- b. This internal secretion results from the fact that these glands have no ducts. Thus, they are often referred to as the ductless glands.
- c. The secretions produced by the endocrine glands are called hormones.
- d. Hormones are carried by the bloodstream to specific organs or tissues, which are then called the target organs.
- e. The activity of the target organ, in turn, affects the activity of the endocrine organ. Thus, it is a reverse or feedback mechanism.

10-2. GENERAL

a. **Control "Systems" of the Human Body.** The structure and function of the human body is controlled and organized by several different "systems."

(1) Heredity/environment. The interaction of heredity and environment is the fundamental control "system." Genes determine the range of potentiality and environment develops it. For example, good nutrition will allow a person to attain his full body height and weight within the limits of his genetic determination. Genetics is the study of heredity.

(2) Hormones. The hormones of the endocrine system serve to control the tissues and organs in general. (Vitamins have a similar role.) Both hormones and vitamins are chemical substances required only in small quantities.

(3) Nervous system. More precise and immediate control of the structures of the body is carried out by the nervous system.

b. **The Endocrine System.** In the human body, the endocrine system consists of a number of ductless glands producing their specific hormones. Because these hormones are carried to their target organs by the bloodstream, the endocrine organs (glands) are richly supplied with blood vessels.

c. **Better Known Endocrine Organs of Humans.** The better known endocrine organs are the:

- (1) Pituitary body.
- (2) Thyroid gland.
- (3) Parathyroid glands.
- (4) Pancreatic islets (islands of Langerhans).
- (5) Suprarenal (adrenal) glands.
- (6) Gonads (female--ovaries; male--testes).

In addition, there are several other endocrine organs, less well understood, and other organs suspected to be of the endocrine type. See figure 10-1, which shows the better known endocrine glands and their locations.

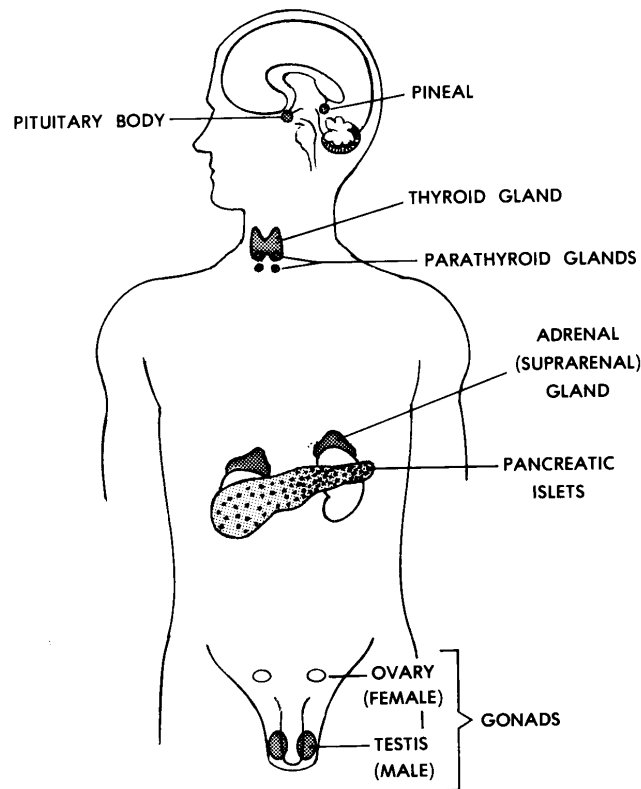


Figure 10-1. The endocrine glands of the human body and their locations.

Section II. THE PITUITARY BODY

10-3. GENERAL

a. **Location.** The pituitary body is a small pea-sized and pea-shaped structure. It is attached to the base of the brain in the region of the hypothalamus (see [paragraph 11-9](#)). In addition, it is housed within a hollow of the bony floor of the cranial cavity. This hollow is called the sella turcica ("Turk's saddle").

b. **Major Subdivisions.** The pituitary body is actually two glands-- the posterior pituitary gland and the anterior pituitary gland. Initially separate, these glands join together during development of the embryo.

10-4. POSTERIOR PITUITARY GLAND

The posterior pituitary gland is the portion which comes from and retains a direct connection with the base of the brain. The hormones of the posterior pituitary gland are actually produced in the hypothalamus of the brain. From the hypothalamus, the hormones are delivered to the posterior pituitary gland, where they are released into the bloodstream. At present, we recognize two hormones of the posterior pituitary gland.

a. **ADH (Antidiuretic Hormone).** ADH is involved with the resorption or salvaging of water within the kidneys. ADH is produced under thirst conditions.

b. **Oxytocin.** Oxytocin is concerned with contractions of smooth muscle in the uterus and with milk secretion.

10-5. ANTERIOR PITUITARY GLAND

a. The anterior pituitary gland originates from the roof of the embryo's mouth. It then "attaches" itself to the posterior pituitary gland.

b. The anterior pituitary gland is indirectly connected to the hypothalamus by means of a venous portal system. By "portal," we mean that the veins carry substances from the capillaries at one point to the capillaries at another point (hypothalamus to the anterior pituitary gland).

c. In the hypothalamus, certain chemicals known as releasing factors are produced. These are carried by the portal system to the anterior pituitary gland. Here, they stimulate the cells of the anterior pituitary gland to secrete their specific hormones.

d. The anterior pituitary gland produces many hormones. In general, they stimulate the target organs to develop or produce their own products. This stimulating effect is referred to as trophic.

e. Of the many hormones produced by the anterior pituitary gland, we will examine:

(1) Somatotrophic hormone (growth hormone). The target organs of this hormone are the growing structures of the body. This hormone influences such structures to grow.

(2) ACTH (adrenocorticotrophic hormone). This hormone of the anterior pituitary gland stimulates the cortex of the suprarenal (adrenal) gland to produce its hormones. We will later see that the hormones of the suprarenal cortex are involved with anti-inflammatory reactions of the body.

(3) Thyrotropin (TSH). This hormone stimulates the thyroid gland to produce its hormones.

(4) Luteinizing hormone (LH). LH stimulates ovulation and luteinization of ovarian follicles in females and promotes testosterone production in males.

(5) Follicle-stimulating hormone (FSH). FSH stimulates ovarian follicle growth in females and stimulates spermatogenesis in males.

(6) Prolactin. Prolactin stimulates milk production and maternal behavior in females.

Section III. THE THYROID GLAND

10-6. LOCATION

The thyroid gland is in the neck region just below the larynx and surrounds the trachea.

10-7. ANATOMY

a. The right and left thyroid lobes are the masses on either side of the trachea. The isthmus is found across the front of the trachea and connects the two lobes.

b. Each lobe of the thyroid gland is supplied by arteries from above and below (superior and inferior thyroid arteries).

10-8. HORMONES

The primary hormone of the thyroid gland is thyroxin. Thyroxin affects the basal metabolic rate (BMR), the level of activity of the body. Since iodine is a necessary element in the production of thyroxin, one can observe malformations of the thyroid gland

(called goiters) where there is little or no iodine available. A second hormone, calcitonin, is produced by the thyroid gland and it is involved with calcium metabolism in the body.

Section IV. THE PARATHYROID GLANDS

10-9. LOCATION AND STRUCTURE

Located on the posterior aspects of the thyroid lobes are two pairs of small round masses of tissue, known as the parathyroid glands.

10-10. HORMONE

The hormone produced by these glands is called parathyroid hormone, or parathormone. It is involved with calcium metabolism.

Section V. THE PANCREATIC ISLETS (ISLANDS OF LANGERHANS)

10-11. LOCATION AND STRUCTURE

Within the substance of the pancreas are distributed small groups of cells known as islets. Although the pancreas is a ducted gland of the digestive system, these isolated islets are, in fact, ductless glands.

10-12. HORMONES

Insulin and glucagon are the two most commonly recognized hormones of the islets. These hormones are involved with glucose metabolism.

Section VI. THE SUPRARENAL (ADRENAL) GLANDS

10-13. LOCATION AND STRUCTURE

Embedded in the fat above each kidney is a suprarenal gland. Both suprarenal glands have an internal medulla and an external cortex.

10-14. HORMONES OF THE SUPRARENAL MEDULLA

The medullary portion of each suprarenal gland produces a pair of hormones--epinephrine (adrenalin) and norepinephrine (noradrenalin). These

hormones are involved in the mobilization of energy during the stress reaction ("fight or flight").

10-15. HORMONES OF THE SUPRARENAL CORTEX

Each suprarenal cortex produces a variety of hormones which can be grouped into three categories:

- a. **Mineralocorticoids** (for example, aldosterone), which are concerned with the electrolytes of the body.

- b. **Glucocorticoids** (for example, cortisol), which are concerned with many metabolic functions and are anti-inflammatory in nature.

- c. **Sex hormones.** Adrenal androgens and estrogens.

Section VII. THE GONADS

10-16. GENERAL

In humans, the primary sex organs are known as gonads (lesson 8). The gonads produce sex cells (gametes) and sex hormones. These sex hormones are in addition to those produced by the suprarenal cortex (see para 10-15c).

10-17. FEMALE SEX HORMONES

In the female, the ovaries produce two types of sex hormones during the menstrual cycle. During the first half of the cycle (days 1 - 14), the estrogens are produced. During the last half of the cycle (days 15 - 28), progesterone is produced. These hormones are concerned with female sexuality and with the preparation of female sex organs for reproduction.

10-18. MALE SEX HORMONES

In the male, certain cells of the testes produce the male sex hormones known as androgens (for example, testosterone). Androgens are concerned with male sexuality.

Continue with Exercises

EXERCISES, LESSON 10

REQUIREMENT. The following exercises are to be answered by completing the incomplete statement or by writing the answer in the space provided at the end of the question.

After you have completed all the exercises, turn to "Solutions to Exercises," at the end of the lesson and check your answers.

1. Endocrine glands are glands of _____ secretion. These glands are also called _____ glands. Hormones are the secretions produced by _____ glands. Target organs are the specific organs or tissues to which _____s are carried by the _____. This is a feedback mechanism because the activity of the target organ affects the activity of the _____.

2. The fundamental control "system" is the interaction of _____ and _____. Genes determine the range of _____. Environment _____s it. Controlling the tissues and organs in general are the _____s of the _____ system. Providing more precise and immediate control of the body structures is the _____ system.

3. Why are endocrine organs (glands) richly supplied with blood vessels?

4. Name six of the better known endocrine organs.

a. _____.

b. _____.

c. _____.

d. _____.

e. _____.

f. _____.

5. The pituitary body is a small _____-sized and _____-shaped structure. It is attached to the base of the brain in the region of the h_____. In addition, it is housed within a hollow of the bony floor of the _____ cavity. The pituitary body is actually two glands: the _____ pituitary gland and the _____ pituitary gland.

6. The posterior pituitary gland is that portion of the pituitary body which comes from and retains its connection with the _____. The hormones of the posterior pituitary gland are actually produced in the h_____ of the brain. The two recognized hormones of the posterior pituitary gland are _____ (a hormone) and _____. The first is involved with the _____ of water within the kidneys; it is produced under _____ conditions. The second is concerned with contractions of smooth muscle in the _____ and with _____ production.

7. The anterior pituitary gland originates from the roof of the embryo's _____. It then attaches itself to the _____ gland. By means of a venous portal system, the anterior pituitary gland is connected to the h_____. Here, certain chemicals known as r_____ f_____ are produced. These are carried to the anterior pituitary by the _____ system. They stimulate the anterior pituitary gland's cells to secrete their specific _____. In turn, these hormones stimulate the target organs to produce their own products. This stimulating effect is referred to as _____. Two hormones produced by the anterior pituitary gland are _____ trophic hormone and _____ (_____ trophic hormone). The target organs of the first are the _____ ing structures of the body. The second stimulates the cortex of the _____ (_____) gland to produce its hormones.

8. The thyroid gland is in the _____ region just below the _____ and surrounds the _____. The masses on either side of the trachea are the right and left thyroid _____. The tissue connecting the two lobes is called the _____. It is found across the front of the _____. Each lobe of the thyroid gland is supplied by the superior and inferior _____ arteries. The primary hormone of the thyroid gland is _____, which affects the _____ _____ _____ (_____), the level of activity of the body.

9. Where are the parathyroid glands located?

The hormone produced by these glands is called _____ hormone or _____. It is involved with _____ metabolism.

10. Within the pancreas are distributed small groups of cells known as _____. The two most commonly recognized hormones of the islets are _____ and _____. These hormones are involved with _____ metabolism.

11. The suprarenal glands are embedded in the fat above the _____ on each side. Each suprarenal gland has an internal _____ and an external _____. The inner portion produces a pair of hormones: e_____ (_____) and n_____ (_____). These are involved in the mobilization of _____ during the stress reaction ("_____ or _____"). Each suprarenal cortex produces hormones which can be grouped into three different categories:

a. M_____s (for example, aldosterone), which are concerned with the _____ of the body.

b. G_____s (for example, cortisol), which are concerned with many metabolic functions and are anti-_____ in nature.

c. _____ hormones.

12. In humans, the primary sex organs are known as _____s. These organs produce _____ cells (_____) and sex _____s.

13. During the first half of the menstrual cycle, the ovaries produce _____s. During the second half, they produce _____e. These hormones are concerned with female _____y and with the preparation of female sex _____s for reproduction.

14. The testes produce the male sex hormones known as _____(for example, _____). These hormones are concerned with male _____.

Check Your Answers on Next Page

SOLUTIONS TO EXERCISES, LESSON 10

1. Endocrine glands are glands of internal secretion. These glands are also called ductless glands. Hormones are the secretions produced by endocrine glands. Target organs are the specific organs or tissues to which hormones are carried by the bloodstream. This is a feedback mechanism because the activity of the target organ affects the activity of the endocrine organ. (para 10-1)
2. The fundamental control "system" is the interaction of heredity and environment. Genes determine the range of potentiality. Environment develops it. Controlling the tissues and organs in general are the hormones of the endocrine system. Providing more precise and immediate control of the body structures is the nervous system. (para 10-2a)
3. Endocrine organs are richly supplied with blood vessels because hormones must be carried to their target organs by the bloodstream. (para 10-2b)
4.
 - a. Pituitary body.
 - b. Thyroid gland.
 - c. Parathyroid glands.
 - d. Pancreatic islets.
 - e. Suprarenal (adrenal) glands.
 - f. Gonads (female--ovaries, male--testes). (para 10-2c)
5. The pituitary body is a small pea-sized and pea-shaped structure. It is attached to the base of the brain in the region of the hypothalamus. In addition, it is housed within a hollow of the bony floor of the cranial cavity. The pituitary body is actually two glands: the posterior pituitary gland and the anterior pituitary gland. (para 10-3)
6. The posterior pituitary gland is that portion of the pituitary body which comes from and retains its connection with the base of the brain. The hormones of the posterior pituitary gland are actually produced in the hypothalamus of the brain. The two recognized hormones of the posterior pituitary gland are ADH (antidiuretic hormone) and oxytocin. The first is involved with the resorption or salvaging of water within the kidneys; it is produced under thirst conditions. The second is concerned with contraction of smooth muscle in the uterus and with milk production. (para 10-4)

7. The anterior pituitary gland originates from the roof of the embryo's mouth. It then attaches itself to the posterior pituitary gland. By means of a venous portal system, the anterior pituitary gland is connected to the hypothalamus. Here, certain chemicals known as releasing factors are produced. These are carried to the anterior pituitary by the venous portal system. They stimulate the anterior pituitary gland's cells to secrete their specific hormones. In turn, these hormones stimulate the target organs to produce their own products. This stimulating effect is referred to as trophic. Two of the hormones produced by the anterior pituitary gland are somatotropic hormone and ACTH (adrenocorticotrophic hormone). The target organs of the first are the growing structures of the body. The second stimulates the cortex of the suprarenal (adrenal) gland to produce its own hormones. (para 10-5)
8. The thyroid gland is in the neck region just below the larynx and surrounds the trachea. The masses on either side of the trachea are the right and left thyroid lobes. The tissue connecting the two lobes is called the isthmus. It is found across the front of the trachea. Each lobe of the thyroid gland is supplied by the superior and inferior thyroid arteries. The primary hormone of the thyroid gland is thyroxin, which affects the basal metabolic rate (BMR), the level of activity of the body. (paras 10-6--10-8)
9. The parathyroid glands are located on the posterior aspects of the thyroid lobes. The hormone produced by these glands is called parathyroid hormone or parathormone. It is involved with calcium metabolism. (paras 10-9, 10-10)
10. Within the pancreas are distributed small groups of cells known as islets. The two most commonly recognized hormones of the islets are insulin and glucagon. These hormones are involved with glucose metabolism. (paras 10-11, 10-12)
11. The suprarenal glands are embedded in the fat above the kidney on each side. Each suprarenal gland has an internal medulla and an external cortex. The inner portion produces a pair of hormones: epinephrine (adrenalin) and norepinephrine (noradrenalin). These are involved in the mobilization of energy during the stress reaction ("fight or flight"). Each suprarenal cortex produces hormones which can be grouped into three different categories:
 - a. Mineralocorticoids (for example, aldosterone), which are concerned with the electrolytes of the body.
 - b. Glucocorticoids (for example, cortisol), which are concerned with many metabolic functions and are anti-inflammatory in nature.
 - c. Sex hormones. (paras 10-13--10-15)
12. In humans, the primary sex organs are known as gonads. These organs produce sex cells (gametes) and sex hormones. (para 10-16)

13. During the first half of the menstrual cycle, the ovaries produce estrogens. During the second half, they produce progesterone. These hormones are concerned with female sexuality and with the preparation of female sex organs for reproduction. [\(para 10-17\)](#)
14. The testes produce the male sex hormones known as androgens (for example, testosterone). These hormones are concerned with male sexuality. [\(para 10-18\)](#)

End of Lesson 10

LESSON ASSIGNMENT

LESSON 11

The Human Nervous System.

TEXT ASSIGNMENT

Paragraphs 11-1 through 11-39.

LESSON OBJECTIVES

After completing this lesson, you should be able to:

- 11-1. Name and identify two types of nervous tissues.
- 11-2. Name three functions for which nervous tissues are specialized.
- 11-3. Define neuron, dendrite, and axon.
- 11-4. When given the shape, diameter, or function, name the corresponding type of neuron.
- 11-5. Describe neuron "connections," including the synapse and the neuromuscular junction.
- 11-6. Name and identify the three major divisions of the human nervous system; name the two major subdivisions of the CNS.
- 11-7. Name and briefly describe the three major subdivisions of the human brain; name and locate the four ventricles and their connecting channels.
- 11-8. Describe the spinal cord, including the two enlargements, elements of its cross section, and the surrounding vertebral canal.
- 11-9. Describe the meninges and the skeletal coverings of the CNS.
- 11-10. Name and identify the main arteries and veins of the brain and briefly describe the blood supply of the spinal cord.
- 11-11. Describe the formation of cerebrospinal fluid (CSF) and the path of CSF flow.

- 11-12. Define peripheral nervous system (PNS) and nerve; name and briefly describe two categories of PNS nerves; describe the anatomy of a "typical" spinal nerve; define reflex and reflex arc; briefly describe the components of the general reflex arc.
- 11-13. Define autonomic nervous system (ANS) and visceral organs; briefly describe efferent pathways of the ANS; name the major divisions of the human ANS; briefly describe the major activities of the human ANS for the thoraco-lumbar and cranio-sacral outflows; briefly describe the first and second neurons, innervations, and effects in each case.
- 11-14. Define pathway, neuraxis, sensor pathway, and motor pathway; briefly describe levels of control, pyramidal and extra-pyramidal motor pathways, and sensory pathways; and give examples of general senses and special senses.
- 11-15. Briefly describe the sensory receptors and sensory pathways for the special senses of smell and taste.
- 11-16. Describe the structures of the bulbus oculi, the orbit, and the adnexa.
- 11-17. Describe the structures of the external ear, the middle ear, and the internal ear.
- 11-18. Describe the structures of the sacculus, utriculus, semicircular ducts, and the vestibular nerve.
- 11-19. Describe controls in the human nervous system.

SUGGESTION

After completing the assignment, complete the exercises at the end of this lesson. These exercises will help you to achieve the lesson objectives.

LESSON 11

THE HUMAN NERVOUS SYSTEM

Section I. INTRODUCTION

11-1. NERVOUS TISSUES

There are two types of nervous tissues--the neurons (nerve cells) and glia (neuroglia). See paragraph 2-17. The neuron is the basic structural unit of the nervous system. The glia are cells of supporting tissue for the nervous system. There are several different types of glia, but their general function is support (physical, nutritive, etc.).

11-2. SPECIALIZATION

Nervous tissues are specialized to:

- a. **Receive Stimuli.** Cells receiving stimuli are said to be "irritable" (as are all living cells to a degree).
- b. **Transmit Information.**
- c. **"Store" Information.** The storing of information is called memory.

Section II. THE NEURON AND ITS "CONNECTIONS"

11-3. DEFINITION

A neuron (figure 11-1) is a nerve cell body and all of its processes (branches).

11-4. NEURON CELL BODY

The neuron cell body is similar to that of the "typical" animal cell described in lesson 1.

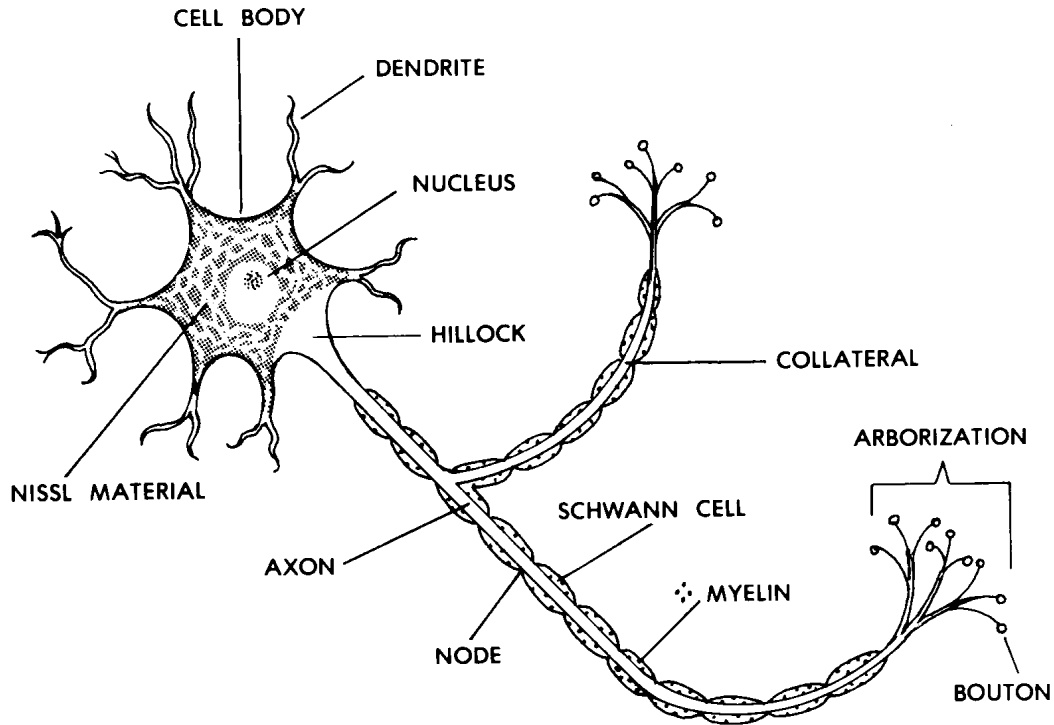


Figure 11-1. A "typical" neuron.

11-5. NEURON PROCESSES

There are two types of neuron processes--dendrites and axons.

a. **Dendrite.** A dendrite is a neuron process which carries impulses toward the cell body. Each neuron may have one or more dendrites. Dendrites receive information and transmit (carry) it to the cell body.

b. **Axon.** An axon is a neuron process which transmits information from the cell body to the next unit. Each neuron has only one axon.

c. **Information Transmission.** Information is carried as electrical impulses along the length of the neuron.

d. **Coverings.** Some neuron processes have a covering which is a series of Schwann cells, interrupted by nodes (thin spots). This gives the neuron process the appearance of links of sausage. The Schwann cells produce a lipid (fatty) material called myelin. This myelin acts as an electrical insulator during the transmission of impulses.

11-6. TYPES OF NEURONS

Neurons may be identified according to shape, diameter of their processes, or function.

a. **According to Shape.** A pole is the point where a neuron process meets the cell body. To determine the type according to shape, count the number of poles.

(1) Multipolar neurons. Multipolar neurons have more than two poles (one axon and two or more dendrites).

(2) Bipolar neurons. Bipolar neurons have two poles (one axon and one dendrite).

(3) Unipolar neurons. Unipolar neurons have a single process which branches into a T-shape. One arm is an axon; the other is a dendrite.

b. **According to Diameter (Thickness) of Processes.** Neurons may be rated according to the thickness of myelin surrounding the axon. In order of decreasing thickness, they are rated A (thickest), B, and C (thinnest). The thickness affects the rate at which impulses are transmitted. The thickest are fastest. The thinnest are slowest.

c. **According to Function.**

(1) Sensory neurons. In sensory neurons, impulses are transmitted from receptor organs (for pain, vision, hearing, etc.) to the central nervous system (CNS).

(2) Motor neurons. In motor neurons, impulses are transmitted from the CNS to muscles and glands (effector organs).

(3) Interneurons. Interneurons transmit information from one neuron to another. An interneuron "connects" two other neurons.

(4) Others. There are other, more specialized types, for example, in the CNS.

11-7. NEURON "CONNECTIONS"

A neuron may "connect" either with another neuron or with a muscle fiber. A phrase used to describe such "connections" is "continuity without contact." Neurons do not actually touch. There is just enough space to prevent the electrical transmission from crossing from the first neuron to the next. This space is called the synaptic cleft. Information is transferred across the synaptic cleft by chemicals called neurotransmitters. Neurotransmitters are manufactured and stored on only one side of the cleft. Because of this, information flows in only one direction across the cleft.

a. **The Synapse.** A synapse (figure 11-2) is a "connection" between two neurons.

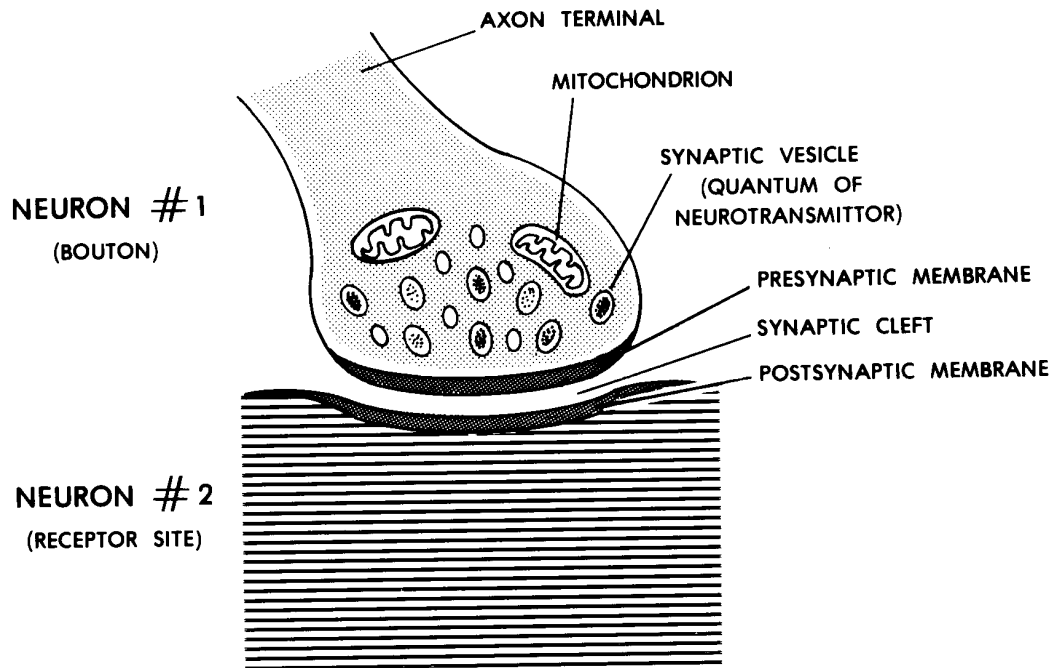


Figure 11-2. A synapse.

(1) First neuron. An axon terminates in tiny branches. At the end of each branch is found a terminal bulb. Synaptic vesicles (bundles of neurotransmitter) are located within each terminal bulb. That portion of the terminal bulb which faces the synaptic cleft is thickened and is called the presynaptic membrane. This is the membrane through which neurotransmitters pass to enter the synaptic cleft.

(2) Synaptic cleft. The synaptic cleft is the space between the terminal bulb of the first neuron and the dendrite or cell body of the second neuron.

(3) Second neuron. The terminal bulb of the first neuron lies near a site on a dendrite or the cell body of the second neuron. The membrane at this site on the second neuron is known as the postsynaptic membrane. Within the second neuron is a chemical that inactivates the used neurotransmitter.

b. **The Neuromuscular Junction.** A neuromuscular junction (figure 11-3) is a "connection" between the terminal of a motor neuron and a muscle fiber. The neuromuscular junction has an organization identical to a synapse. However, the bulb is larger. The postsynaptic membrane is also larger and has foldings to increase its surface area.

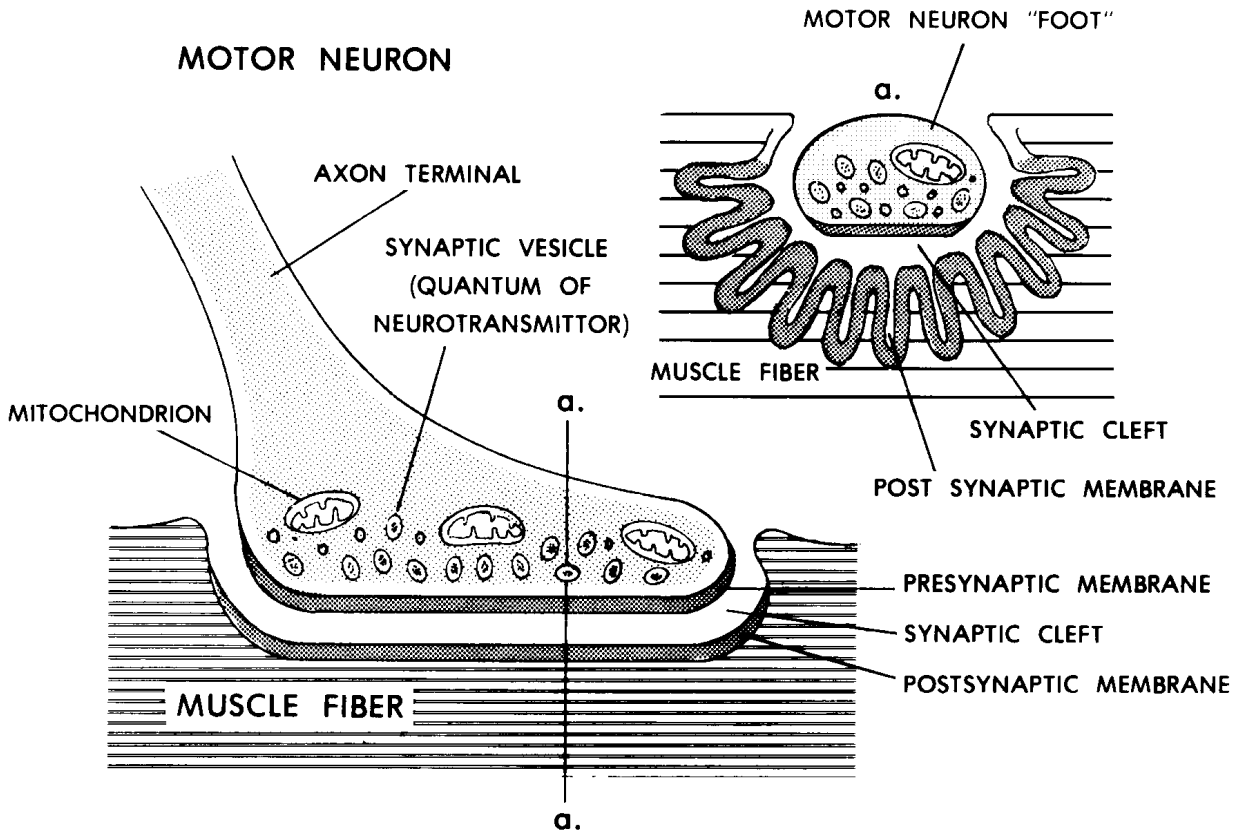


Figure 11-3. A neuromuscular junction.

(1) Motor neuron. The axon of a motor neuron ends as it reaches a striated muscle fiber (of a skeletal muscle). At this point, it has a terminal bulb. Within this bulb are synaptic vesicles (bundles of neurotransmitter). The presynaptic membrane lines the surface of the terminal bulb and lies close to the muscle fiber.

(2) Synaptic cleft. The synaptic cleft is a space between the terminal bulb of the motor neuron and the membrane of the muscle fiber.

(3) Muscle fiber. The terminal bulb of the motor neuron protrudes into the surface of the muscle fiber. The membrane lining the synaptic space has foldings and is called the postsynaptic membrane. Beneath the postsynaptic membrane is a chemical which inactivates the used neurotransmitter.

Section III. THE HUMAN CENTRAL NERVOUS SYSTEM

11-8. GENERAL

The major divisions of the human nervous system are the central nervous system (CNS), the peripheral nervous system (PNS), and the autonomic nervous

system (ANS). The CNS is made up of the brain and spinal cord. Both the PNS and the ANS carry information to and from the central nervous system. The PNS is generally concerned with the innervation of skeletal muscles and other muscles made up of striated muscle tissue, as well as sensory information from the periphery of the body. The ANS is that portion of the nervous system concerned with control of smooth muscle, cardiac muscle, and glands. The CNS (figure 11-4) is known as central because its anatomical location is along the central axis of the body and because the CNS is central in function. If we use a computer analogy to understand that it is central in function, the CNS would be the central processing unit and other parts of the nervous system would supply inputs and transmit outputs.

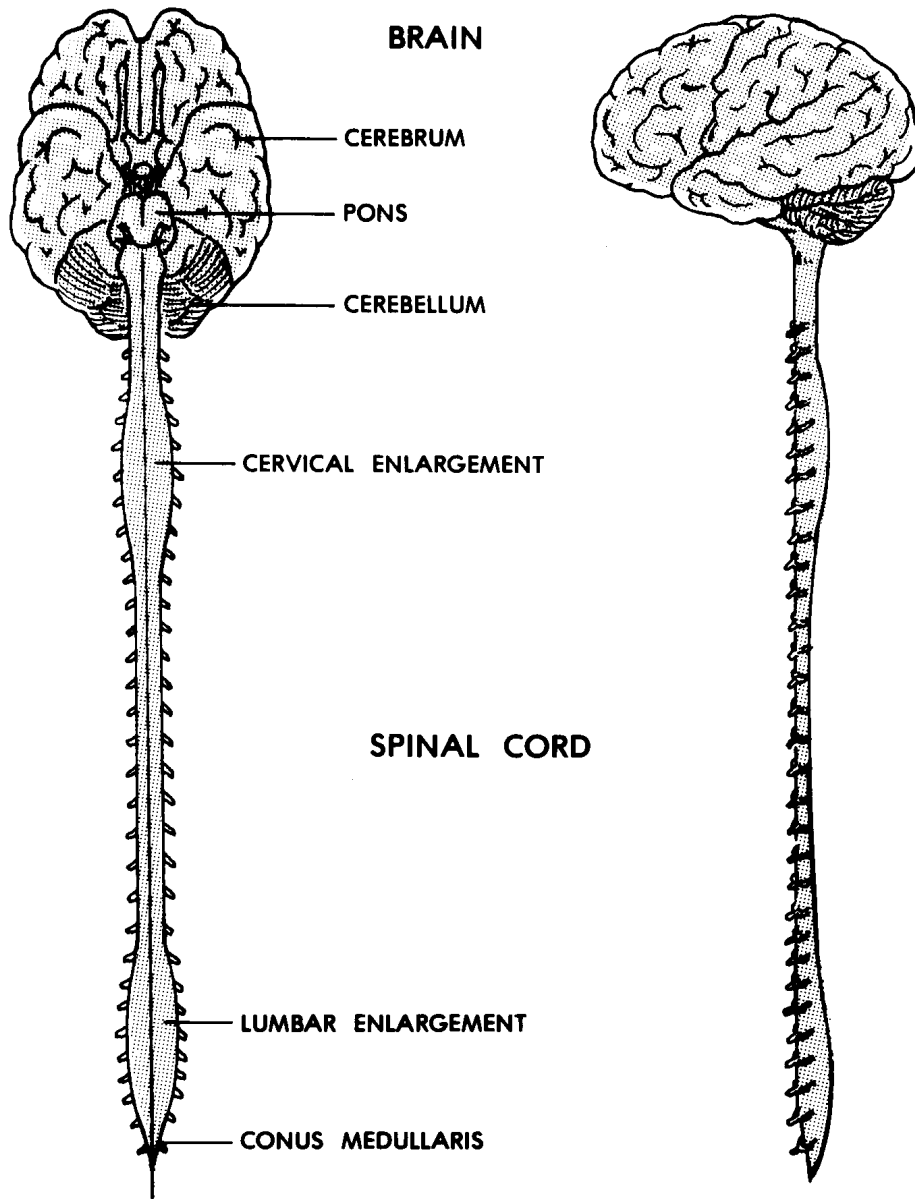


Figure 11-4. The human central nervous system.

a. **Major Subdivisions of the CNS.** The major subdivisions of the CNS are the brain and the spinal cord.

b. **Coverings of the CNS.** The coverings of the CNS are skeletal and fibrous.

c. **Cerebrospinal Fluid (CSF).** The CSF is a liquid thought to serve as a cushion and circulatory vehicle within the CNS.

11-9. THE HUMAN BRAIN

The human brain has three major subdivisions: brainstem, cerebellum, and cerebrum. The CNS is first formed as a simple tubelike structure in the embryo. The concentration of nervous tissues at one end of the human embryo to produce the brain and head is referred to as cephalization. When the embryo is about four weeks old, it is possible to identify the early forms of the brainstem, cerebellum, and cerebrum, as well as the spinal cord. As development continues, the brain is located within the cranium (para 4-13c(1)) in the cranial cavity. See figures 11-5A and 11-5B for illustrations of the adult brain.

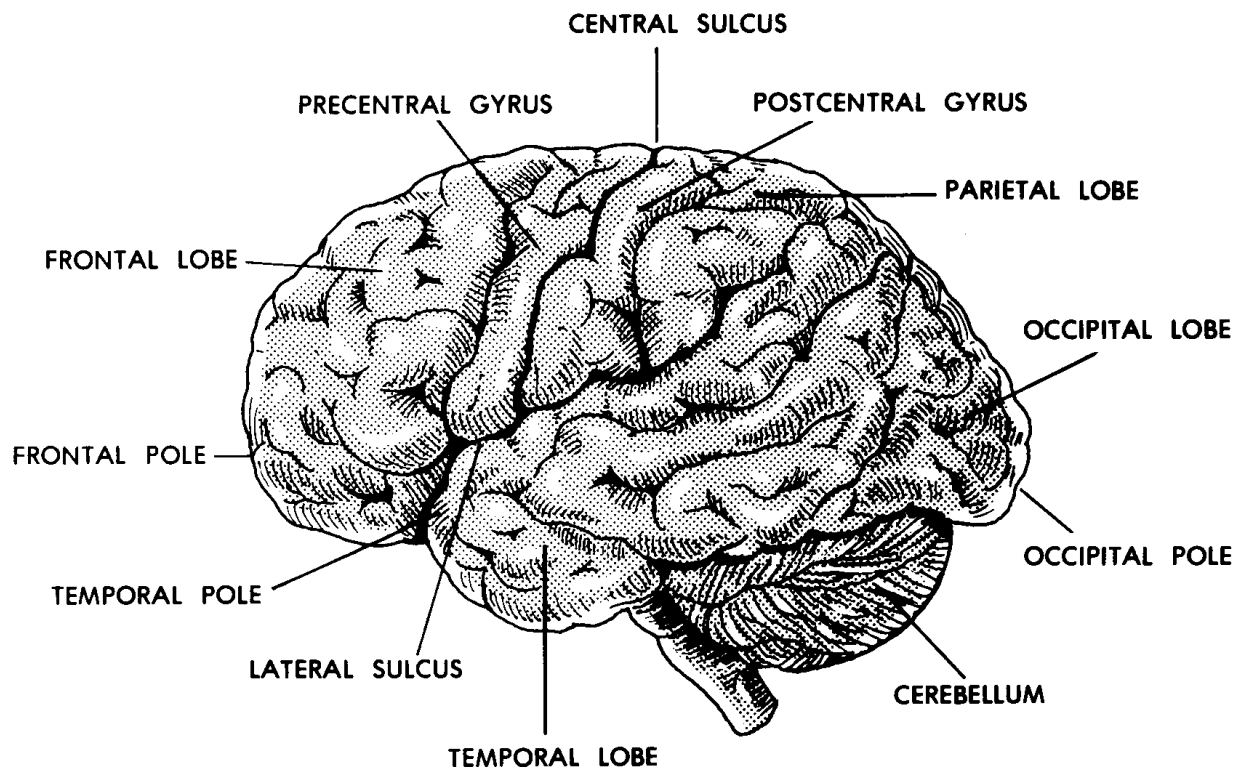


Figure 11-5A. Human brain (side view).

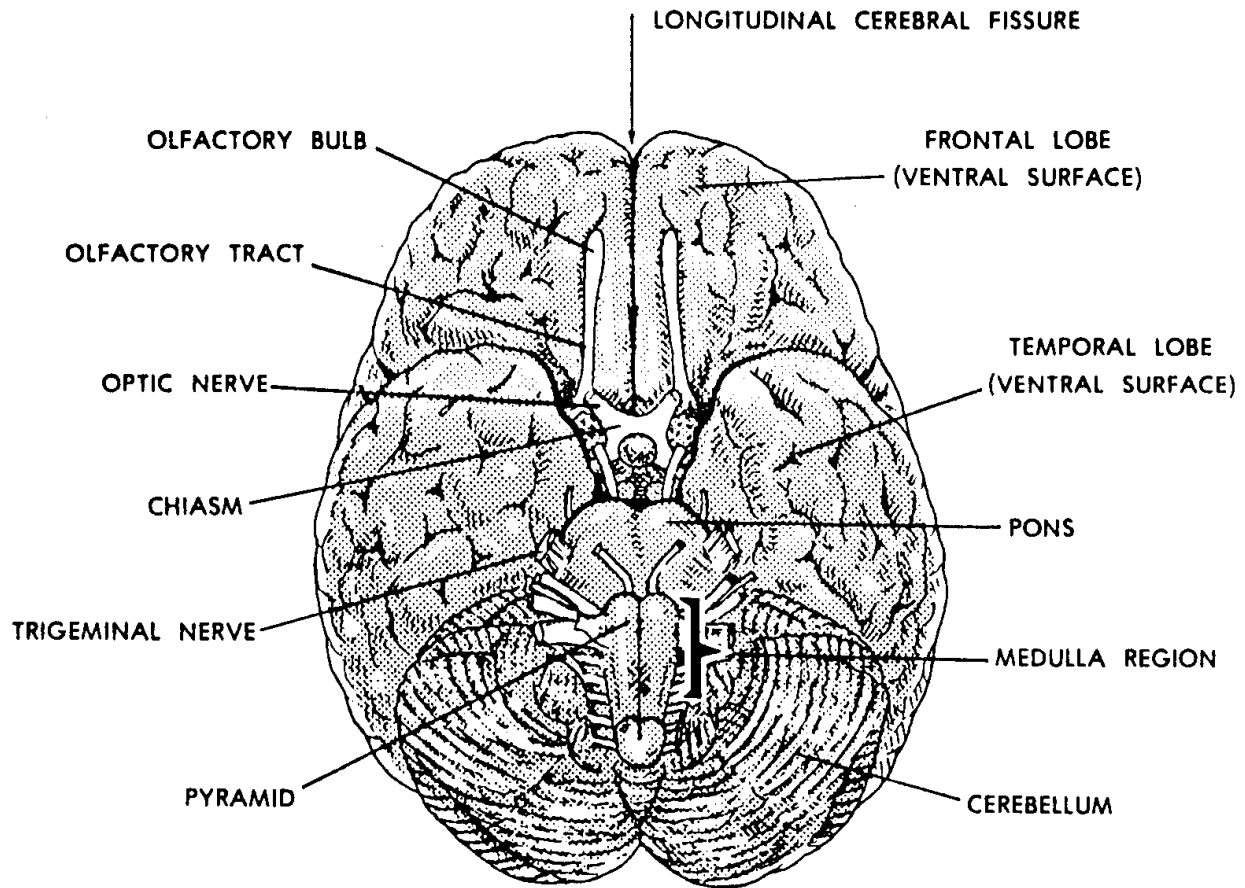


Figure 11-5B. Human brain (bottom view).

a. **The Brainstem.** The term brainstem refers to that part of the brain that would remain after removal of the cerebrum and cerebellum. The brainstem is the basal portion (portion of the base) of the brain. The brainstem can be divided as follows:

FOREBRAINSTEM:	thalamus hypothalamus
MIDBRAINSTEM:	corpora quadrigemina cerebral peduncles
HINDBRAINSTEM:	pons medulla

(1) The brainstem is continuous with the spinal cord. Together, the brainstem and the spinal cord are sometimes known as the neuraxis.

(2) The brainstem provides major relays and controls for information passing up or down the neuraxis.

(3) The 12 pairs of cranial nerves connect at the sides of the brainstem.

b. **Cerebellum.** The cerebellum is a spherical mass of nervous tissue attached to and covering the hindbrainstem. It has a narrow central part called the vermis and right and left cerebellar hemispheres.

(1) Peduncles. A peduncle is a stem-like connecting part. The cerebellum is connected to the brainstem with three pairs of peduncles.

(2) General shape and construction. A cross section of the cerebellum reveals that the outer cortex is composed of gray matter (cell bodies of neurons) with many folds and sulci (shallow grooves). More centrally located is the white matter (myelinated processes of neurons).

(3) Function. The cerebellum is the primary coordinator/integrator of motor actions of the body.

c. **Cerebrum.** The cerebrum consists of two very much enlarged hemispheres connected to each other by a special structure called the corpus callosum. Each cerebral hemisphere is connected to the brainstem by a cerebral peduncle. The surface of each cerebral hemisphere is subdivided into areas known as lobes. Each lobe is named according to the cranial bone under which it lies: frontal, parietal, occipital, and temporal.

(1) The space separating the two cerebral hemispheres is called the longitudinal fissure. The shallow grooves in the surface of the cerebrum are called sulci (sulcus, singular). The ridges outlined by the sulci are known as gyri (gyrus, singular).

(2) The cerebral cortex is the gray outer layer of each hemisphere. The occurrence of sulci and gyri helps to increase the amount of this layer. Deeper within the cerebral hemispheres, the tissue is white. The "gray matter" represents cell bodies of the neurons. The "white matter" represents the axons.

(3) The areas of the cortex are associated with groups of related functions.

(a) For example, centers of speech and hearing are located along the lateral sulcus, at the side of each hemisphere.

(b) Vision is centered at the rear in the area known as the occipital lobe.

(c) Sensory and motor functions are located along the central sulcus, which separates the frontal and parietal lobes of each hemisphere. The motor areas are located along the front side of the central sulcus, in the frontal lobe. The sensory areas are located along the rear side of the central sulcus, in the parietal lobe.

d. **Ventricles.** Within the brain, there are interconnected hollow spaces filled with cerebrospinal fluid (CSF). These hollow spaces are known as ventricles. The right and left lateral ventricles are found in the cerebral hemispheres. The lateral ventricles are connected to the third ventricle via the interventricular foramen (of Monroe). The third ventricle is located in the forebrainstem. The fourth ventricle is in the hindbrainstem. The cerebral aqueduct (of Sylvius) is a short tube through the midbrainstem which connects the third and fourth ventricles. The fourth ventricle is continuous with the narrow central canal of the spinal cord.

11-10. THE HUMAN SPINAL CORD

a. **Location and Extent.** Referring to [figure 4-4](#), you can see that the typical vertebra has a large opening called the vertebral (or spinal) foramen. Together, these foramina form the vertebral (spinal) canal for the entire vertebral column. The spinal cord, located within the spinal canal, is continuous with the brainstem. The spinal cord travels the length from the foramen magnum at the base of the skull to the junction of the first and second lumbar vertebrae.

(1) Enlargements. The spinal cord has two enlargements. One is the cervical enlargement, associated with nerves for the upper members. The other is the lumbosacral enlargement, associated with nerves for the lower members.

(2) Spinal nerves. A nerve is a bundle of neuron processes which carry impulses to and from the CNS. Those nerves arising from the spinal cord are spinal nerves. There are 31 pairs of spinal nerves.

b. **A Cross Section of the Spinal Cord (figure 11-6).** The spinal cord is a continuous structure which runs through the vertebral canal down to the lumbar region of the column. It is composed of a mass of central gray matter (cell bodies of neurons) surrounded by peripheral white matter (myelinated processes of neurons). The gray and white matter are thus considered columns of material. However, in a cross section, this effect of columns is lost.

(1) Central canal. A very narrow canal, called the central canal, is located in the center of the spinal cord. The central canal is continuous with the fourth ventricle of the brain.

(2) The gray matter. In the cross section of the spinal cord, one can see a central H-shaped region of gray matter. Each arm of the H is called a horn, resulting in two posterior horns and two anterior horns. The connecting link is called the gray commissure. Since the gray matter extends the full length of the spinal cord, these horns are actually sections of the gray columns.

(3) The white matter. The peripheral portion of the spinal cord cross section consists of white matter. Since a column of white matter is a large bundle of processes, it is called a funiculus. In figure 11-6, note the anterior, lateral, and posterior funiculi.

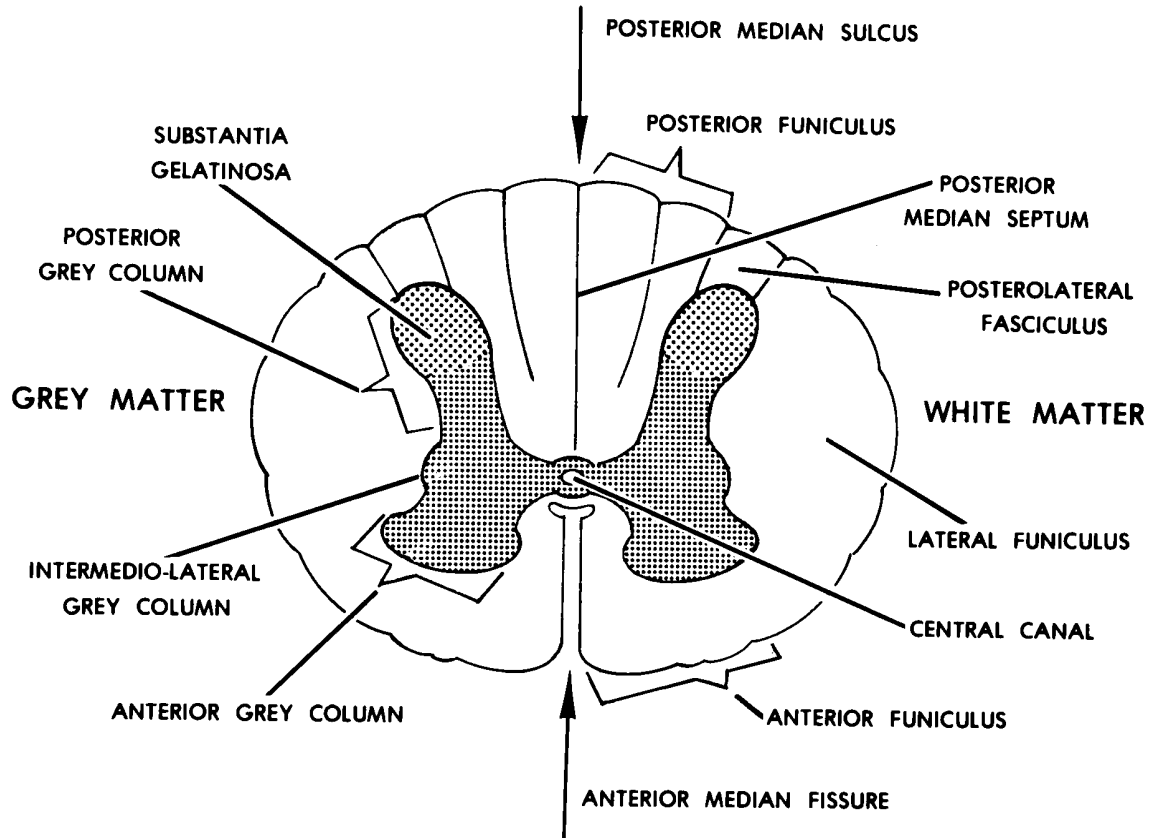


Figure 11-6. A cross-section of the spinal cord.

11-11. COVERINGS OF THE CNS

The coverings of the CNS are skeletal and fibrous.

a. Skeletal Coverings.

(1) Brain. The bones of the cranium form a spherical case around the brain. The cranial cavity is the space inclosed by the bones of the cranium.

(2) Spinal cord. The vertebrae, with the vertebral foramina, form a cylindrical case around the spinal cord. The overall skeletal structure is the vertebral column (spine). The vertebral (spinal) canal is the space inclosed by the foramina of the vertebrae.

b. **Meninges (Fibrous Membranes)**. The brain and spinal cord have three different membranes surrounding them called meninges (figure 11-7). These coverings provide protection.

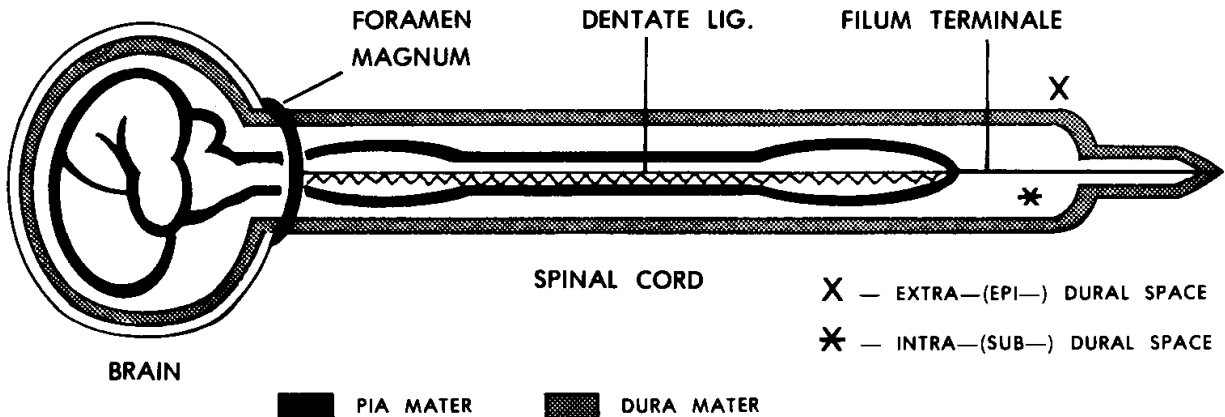


Figure 11-7. A schematic diagram of the meninges, as seen in side view of the CNS.

- (1) Dura mater. The dura mater is a tough outer covering for the CNS. Beneath the dura mater is the subdural space, which contains a thin film of fluid.
- (2) Arachnoid mater. To the inner side of the dura mater and subdural space is a fine membranous layer called the arachnoid mater. It has fine spiderweb-type threads which extend inward through the subarachnoid space to the pia mater. The subarachnoid space is filled with cerebrospinal fluid (CSF).

ARACHNOID = spider-like

- (3) Pia mater. The pia mater is a delicate membrane applied directly to the surface of the brain and the spinal cord. It carries a network of blood vessels to supply the nervous tissues of the CNS.

11-12. BLOOD SUPPLY OF THE CNS

a. **Blood Supply of the Brain.** The paired internal carotid arteries and the paired vertebral arteries supply blood rich in oxygen to the brain. Branches of these arteries join to form a circle under the base of the brain. This is called the cerebral circle (of Willis). From this circle, numerous branches supply specific areas of the brain.

- (1) A single branch is often the only blood supply to that particular area. Such an artery is called an end artery. If it fails to supply blood to that specific area, that area will die (stroke).

- (2) The veins and venous sinuses of the brain drain into the paired internal jugular veins, which carry the blood back toward the heart.

b. **Blood Supply of the Spinal Cord.** The blood supply of the spinal cord is by way of a combination of three longitudinal arteries running along its length and reinforced by segmental arteries from the sides.

11-13. CEREBROSPINAL FLUID (CSF)

A clear fluid called cerebrospinal fluid (CSF) is found in the cavities of the CNS. CSF is found in the ventricles of the brain (para 11-9d), the subarachnoid space (para 11-11b(2)), and the central canal of the spinal cord (para 11-10b(1)). CSF and its associated structures make up the circulatory system for the CNS.

a. **Choroid Plexuses.** Choroid plexuses are special collections of arterial capillaries found in the roofs of the third and fourth ventricles of the brain. The choroid plexuses continuously produce CSF from the plasma of the blood.

b. **Path of the CSF Flow.** Blood flows through the arterial capillaries of the choroid plexuses. As CSF is produced by the choroid plexuses, it flows into all four ventricles. CSF from the lateral ventricles flows into the third ventricle and then through the cerebral aqueduct into the fourth ventricle. By passing through three small holes in the roof of the fourth ventricle, CSF enters the subarachnoid space. From the subarachnoid space, the CSF is transported through the arachnoid villi (granulations) into the venous sinuses. Thus, the CSF is formed from arterial blood and returned to the venous blood.

Section IV. THE PERIPHERAL NERVOUS SYSTEM (PNS)

11-14. GENERAL

a. Definitions.

(1) The peripheral nervous system (PNS) is that portion of the nervous system generally concerned with commands for skeletal muscles and other muscles made up of striated muscle tissue, as well as sensory information from the periphery of the body. The sensory information is carried to the CNS where it is processed. The PNS carries commands from the CNS to musculature.

(2) A nerve is a collection of neuron processes, together and outside the CNS. (A fiber tract is a collection of neuron processes, together and inside the CNS.)

b. **General Characteristics of the Peripheral Nerves.** The PNS is made up of a large number of individual nerves. These nerves are arranged in pairs. Each pair includes one nerve on the left side of the brainstem or spinal cord and one nerve on the right side. The nerve pairs are in a series, each pair resembling the preceding, from top to bottom.

c. **Categories of PNS Nerves.** PNS nerves include cranial nerves and spinal nerves.

(1) Cranial nerves. The 12 pairs of nerves attached to the right and left sides of the brainstem are called cranial nerves. Each cranial nerve is identified by a Roman numeral in order from I to XII and an individual name. For example, the Vth ("fifth") cranial nerve is known as the trigeminal nerve (N.).

TRI = three

GEMINI = alike

TRIGEMINAL = having three similar major branches

(2) Spinal nerves. Attached to the sides of the spinal cord are 31 pairs of spinal nerves. The spinal nerves are named by:

(a) The region of the spinal cord with which the nerve is associated.

(b) An Arabic numeral within the region. For example, T-5 is the fifth spinal nerve in the thoracic region.

11-15. A "TYPICAL" SPINAL NERVE

In the human body, every spinal nerve has essentially the same construction and components. By learning the anatomy of one spinal nerve, you can understand the anatomy of all spinal nerves.

a. **Parts of a "Typical" Spinal Nerve (figure 11-8)**. Like a tree, a typical spinal nerve has roots, a trunk, and branches (rami).

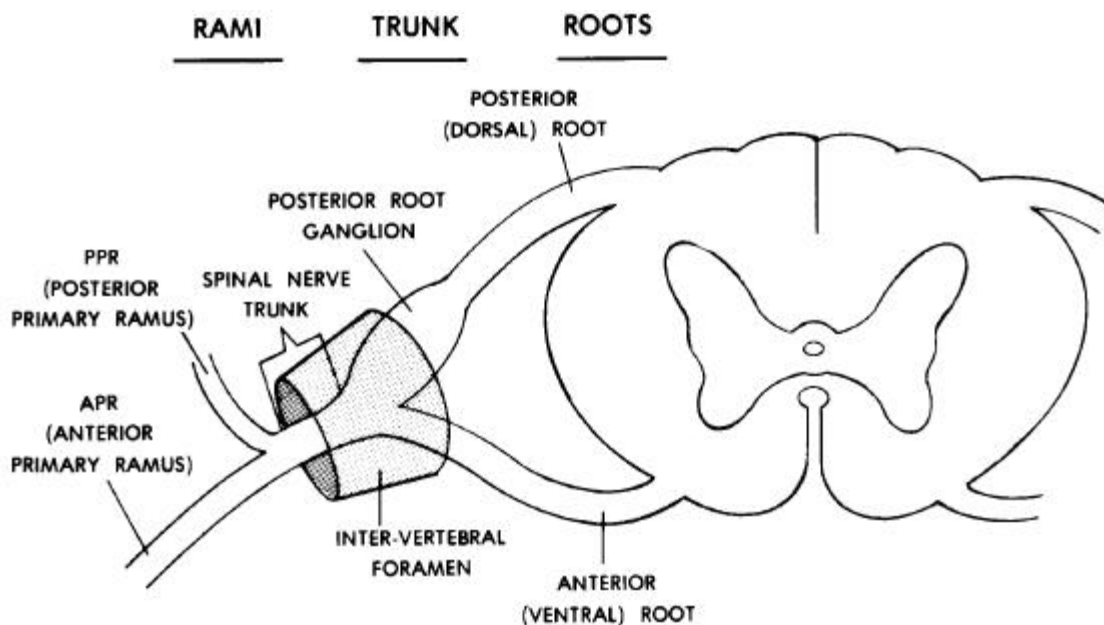


Figure 11-8. A "typical" spinal nerve with a cross section of the spinal cord.

(1) Coming off of the posterior and anterior sides of the spinal cord are the posterior (dorsal) and anterior (ventral) roots of the spinal nerve. An enlargement on the posterior root is the posterior root ganglion. A ganglion is a collection of neuron cell bodies, together, outside the CNS.

(2) Laterally, the posterior and anterior roots of the spinal nerve join to form the spinal nerve trunk. The spinal nerve trunk of each spinal nerve is located in the appropriate intervertebral foramen of the vertebral column. (An intervertebral foramen is a passage formed on either side of the junction between two vertebrae.)

(3) Where the spinal nerve trunk emerges laterally from the intervertebral foramen, the trunk divides into two major branches. These branches are called the anterior (ventral) and posterior (dorsal) primary rami (ramus, singular). The posterior primary rami go to the back. The anterior primary rami go to the sides and front of the body and also to the upper and lower members.

b. **Neurons of a "Typical" Spinal Nerve.** A nerve is defined above as a collection of neuron processes. Thus, neuron processes are the components that make up a nerve. These processes may belong to any of several different types of neurons: afferent (sensory), efferent (motor), and visceral motor neurons of the ANS.

(1) The afferent neuron and the efferent neuron are the two types we will consider here. An afferent neuron is one which carries information from the periphery to the CNS.

A = toward

FERENT = to carry

An efferent neuron is one which carries information from the CNS to a muscle or gland.

E = away from

FERENT = to carry

(2) The afferent neuron is often called the sensory neuron because it carries information about the senses to the CNS. The efferent neuron is often called the motor neuron because it carries commands from the CNS to cause a muscle to act.

(3) A stimulus acts upon a sensory receptor organ in the skin or in another part of the body. The information is carried by an afferent (sensory) neuron through merging branches of the spinal nerve to the posterior root ganglion. The afferent (sensory) neuron's cell body is located in the posterior root ganglion. From this point, information continues in the posterior root to the spinal cord. The efferent (motor) neuron carries command information from the spinal cord to the individual muscle of the human body.

(4) Visceral motor neurons of the ANS (see section V), which innervate visceral organs of the body's periphery, are distributed along with the peripheral nerves.

c. **The General Reflex Arc (figure 11-9).**

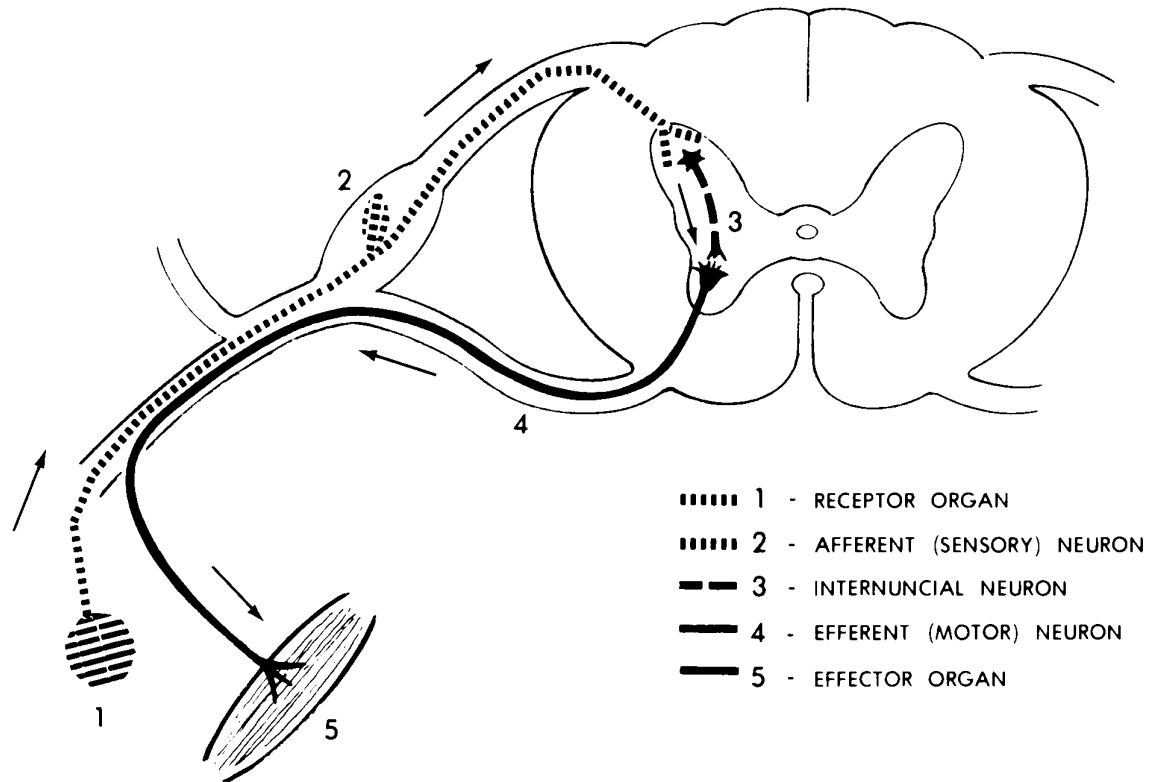


Figure 11-9. The general reflex arc.

(1) Definitions.

(a) An automatic reaction to a stimulus (without first having conscious sensation) is referred to as a reflex. (As an example: The withdrawal of the hand from a hot object.)

(b) The pathway from the receptor organ to the reacting muscle is called the reflex arc.

(2) Components of the general reflex arc. The pathway of a general reflex arc involves a minimum of five structures.

(a) The stimulus is received by a receptor organ.

(b) That information is transmitted to the CNS by the afferent (sensory) neuron.

(c) Within the spinal cord, there is a special neuron connecting the afferent neuron to the efferent neuron. This special connecting neuron is called the internuncial neuron, or interneuron.

INTER = between

NUNCIA = messenger

INTERNUNCIAL = the carrier of information between

(d) The efferent (motor) neuron carries the appropriate command from the spinal cord to the reacting muscle.

(e) The reacting muscle is called the effector organ.

Section V. THE AUTONOMIC NERVOUS SYSTEM (ANS)

11-16. GENERAL

The autonomic nervous system (ANS) is that portion of the nervous system generally concerned with commands for smooth muscle tissue, cardiac muscle tissue, and glands.

a. Visceral Organs.

(1) Definition. The term visceral organs may be used to include:

(a) The various hollow organs of the body whose walls have smooth muscle tissue in them. Examples are the blood vessels and the gut.

(b) The glands.

(2) Distribution. The visceral organs are located in the central cavity of the body (example: stomach) and throughout the periphery of the body (example: sweat glands of the skin).

(3) Control. It has always been thought that the control of visceral organs was "automatic" and not conscious. However, recent researches indicate that proper training enables a person to consciously control some of the visceral organs.

b. **Efferent Pathways**. Earlier, we said that each neuron in the PNS extended the entire distance from the CNS to the receptor or effector organ. In the ANS, there are always two neurons (one after the other) connecting the CNS with the visceral

organ. The cell bodies of the second neurons form a collection outside the CNS, called a ganglion.

(1) The first neuron extends from the CNS to the ganglion and is therefore called the preganglionic neuron.

(2) Cell bodies of the second neuron make up the ganglion. The second neuron's processes extend from the ganglion to the visceral organ. Thus, the second neuron is called the post-ganglionic neuron.

c. **Major Divisions of the Human ANS.** The efferent pathways of the ANS fall into two major divisions:

(1) The thoraco-lumbar outflow (sympathetic nervous system).

(2) The cranio-sacral outflow (parasympathetic nervous system).

d. **Major Activities of the Human ANS.**

(1) The ANS maintains visceral activities in a balanced or stable state. This is called homeostasis.

(2) When subjected to stress, such as a threat, the body responds with the "fight-or-flight reaction." That is, those activities of the body necessary for action in an emergency are activated and those not necessary are deactivated. This is the primary function of the sympathetic portion of the ANS.

11-17. THE THORACO-LUMBAR OUTFLOW (SYMPATHETIC NERVOUS SYSTEM)

a. Refer to paragraph 11-10b(2) which describes the H-shaped region of gray matter in the cross section of the spinal cord. Imagine extending the cross link of the H slightly to the left and right of the vertical arms; the extended ends would correspond to the intermediolateral gray columns. Cell bodies of the first neurons of the sympathetic NS make up those columns between the T-1 and L-2 levels of the spinal cord, a total of 14 levels. Here, we are speaking of preganglionic sympathetic neurons.

b. Cell bodies of the second neurons make up various sympathetic ganglia of the body. These ganglia include the trunk or chain ganglia and the pre-aortic or "central" ganglia. Here, we are speaking of post-ganglionic sympathetic neurons.

c. The sympathetic NS innervates:

(1) Peripheral visceral organs (example: sweat glands).

(2) Central visceral organs (examples: lungs and stomach).

d. The neurons innervating the peripheral visceral organs are distributed to them by being included in the nerves of the PNS.

e. The sympathetic NS activates those visceral organs needed to mobilize energy for action (example: heart) and deactivates those not needed (example: gut).

11-18. THE CRANIO-SACRAL OUTFLOW (PARASYMPATHETIC NERVOUS SYSTEM)

a. Cell bodies of the first neurons of the parasympathetic NS make up the intermediolateral gray columns in the sacral spinal cord at the S-2, S-3, and S-4 levels. See paragraph 11-17a above for the position of the intermediolateral gray columns. Cell bodies of the first neurons also make up four pairs of nuclei in the brainstem; these nuclei are associated with cranial nerves III, VII, IX, and X. Here, we are speaking of preganglionic parasympathetic neurons.

b. Cell bodies of the second neurons make up intramural ganglia within the walls of the visceral organs. These second neurons innervate the central visceral organs. They do NOT innervate peripheral visceral organs. Here, we are speaking of the post-ganglionic parasympathetic neurons.

c. The parasympathetic NS has the opposite effect on visceral organs from that of the sympathetic NS. (Example: The heart is accelerated by the sympathetic NS and decelerated by the parasympathetic NS.)

Section VI. PATHWAYS OF THE HUMAN NERVOUS SYSTEM

11-19. GENERAL

a. Definitions.

(1) A pathway is the series of nervous structures utilized in the transmission of an item of information. An example of a pathway is the reflex arc discussed in paragraph 11-15c.

(2) The brainstem is continuous with the spinal cord. Together, the brainstem and the spinal cord are sometimes known as the neuraxis.

b. General Categories of Neural Pathways.

(1) Sensory pathways. A sensory pathway is a series of nervous structures used to transmit information from the body to the CNS. Upon arrival in the CNS, these pathways ascend (go up) the neuraxis to the brain.

(2) Motor pathways. A motor pathway is a series of nervous structures used to transmit information from the CNS to the body. The commands for motor action originate in the brain and descend (go down) the neuraxis to the appropriate spinal levels. From this point, the commands pass through the nerves to the effector organs.

c. **Controls**. The human nervous system has several levels for control. The lowest level is the simple reflex arc (see para 11-15c). The highest level of control is the conscious level. From the lowest to the highest levels are several progressively higher levels, such as the righting reflex. Thus, the processing of information and the transmission of commands are not haphazard but very carefully monitored and controlled. All information input and all information output are monitored and evaluated.

11-20. THE MOTOR PATHWAYS

Motor pathways begin in the brain. They descend the neuraxis in bundles of a number of specific neuron processes called motor fiber tracts. Commands originating in the right half of the brain leave the CNS through peripheral nerves on the left side. Commands from the left half of the brain leave the CNS on the right side. Therefore, the right half of the brain controls the left side of the body and the left half of the brain controls the right side of the body. For example, the actions of the right hand are controlled by the left half of the brain. (In those people who are right-handed, we refer to the left half of the brain as being dominant.)

a. **Pyramidal Motor Pathways**. A pyramidal motor pathway is primarily concerned with volitional (voluntary) control of the body parts, in particular the fine movements of the hands. Because control is volitional, the pathways can be used for neurological screening and testing. These pathways are called pyramidal because their neuron processes contribute to the makeup of a pair of structures in the base of the brain known as the pyramids.

b. **Extrapyramidal Motor Pathways**. An extrapyramidal pathway is primarily concerned with automatic (nonvolitional) control of body parts for purposes of coordination. Extrapyramidal pathways use many intermediate relays before reaching the effector organs. The cerebellum of the brain plays a major role in extrapyramidal pathways; the cerebellum helps to integrate patterned movements of the body.

11-21. THE SENSORY PATHWAYS

a. The body is continuously bombarded by types of information called stimuli (stimulus, singular). Those few stimuli which are consciously perceived (in the cerebral hemispheres) are called sensations.

b. Those stimuli received throughout the body are called the general senses. Stimuli received by only single pairs of organs in the head (for example, the eyes) are called special senses (for example, smell and taste).

c. The general senses in humans include pain, temperature (warm and cold), touch (light and deep), and proprioception ("body sense": posture, tone, tension).

d. The special senses in humans include smell (olfaction), taste (gustation), vision, hearing (auditory), and equilibrium.

e. The input from each special sensory receptor goes to its own specific area of the opposite cerebral hemisphere. The general sensory pathway is from the receptor organ, via the PNS nerves, to the CNS. This general pathway then ascends fiber tracts in the neuraxis. The pathway ends in the central area of the cerebral hemisphere (on the side opposite to the input).

Section VII. THE SPECIAL SENSE OF SMELL (OLFACTION)

11-22. SENSORY RECEPTORS

Molecules of various materials are dispersed (spread) throughout the air we breathe. A special olfactory epithelium is located in the upper recesses of the nasal chambers in the head. Special hair cells in the olfactory epithelium are called chemoreceptors, because they receive these molecules in the air.

11-23. OLFACTORY SENSORY PATHWAY

The information received by the olfactory hair cells is transmitted by way of the olfactory nerves (cranial nerves I). It passes through these nerves to the olfactory bulbs and then into the opposite cerebral hemisphere. Here, the information becomes the sensation of smell.

Section VIII. THE SPECIAL SENSE OF TASTE (GUSTATION)

11-24. SENSORY RECEPTORS

Molecules of various materials are also dispersed or dissolved in the fluids (saliva) of the mouth. These molecules are from the food ingested (taken in). Organs known as taste buds are scattered over the tongue and the rear of the mouth. Special hair cells in the taste buds are chemoreceptors to react to these molecules.

11-25. SENSORY PATHWAY

The information received by the hair cells of the taste buds is transmitted to the opposite side of the brain by way of three cranial nerves (VII, IX, and X). This information is interpreted by the cerebral hemispheres as the sensation of taste.

Section IX. THE SPECIAL SENSE OF VISION (SIGHT)

11-26. GENERAL

a. **Stimulus.** Rays of light stimulate the receptor tissues of the eyeballs (bulbus oculi) to produce the special sense of vision. This includes both the sensation of vision or seeing and a variety of reactions known as the light reflexes. The actual reception of the light energy is a chemical reaction which in turn stimulates the neuron endings.

b. **Optical Physics.** To appreciate the functioning of the bulbus oculi, some simple principles of optical physics must be understood.

(1) By means of a lens system, light rays are bent and brought to the focal point for acute vision. This process is referred to as focusing.

(2) The focal length is the distance from the focal point to the center of the lens. The amount of bending or focusing depends upon the exact curvatures of the lens system.

c. **Sense Organ.** The eyeball is the special sense organ which contains the receptor tissues. The eyeball is suspended in the orbit. The orbit is a skeletal socket of the skull which helps protect the eyeball. Various structures associated with the functioning of the eyeball are called the adnexa. The adnexa include the eyelids, the lacrimal system, etc.

11-27. THE EYEBALL (FIGURE 11-10)

a. **Shape.** In the main, the eyeball is a spherical bulb-like structure. Its anterior surface, transparent and more curved, is known as the cornea of the eyeball.

b. **Wall of the Eyeball.** The eyeball is a hollow structure. Its wall is made up of three layers known as coats or tunics.

(1) Sclera. The outermost layer is white and very dense FCT (fibrous connective tissue). It is known as the sclera, scleral coat, or fibrous tunic. Its anterior portion is called the cornea. As already mentioned, the cornea is transparent and more curved than the rest of the sclera. The fixed curvature of the cornea enables it to serve as the major focusing device for the eyeball.

(2) Choroid. The middle layer of the wall of the eyeball is known as the choroid, the choroid coat, or the vascular tunic. This layer is richly supplied with blood vessels. It is also pigmented with a black material. The black color absorbs light rays and prevents them from reflecting at random.

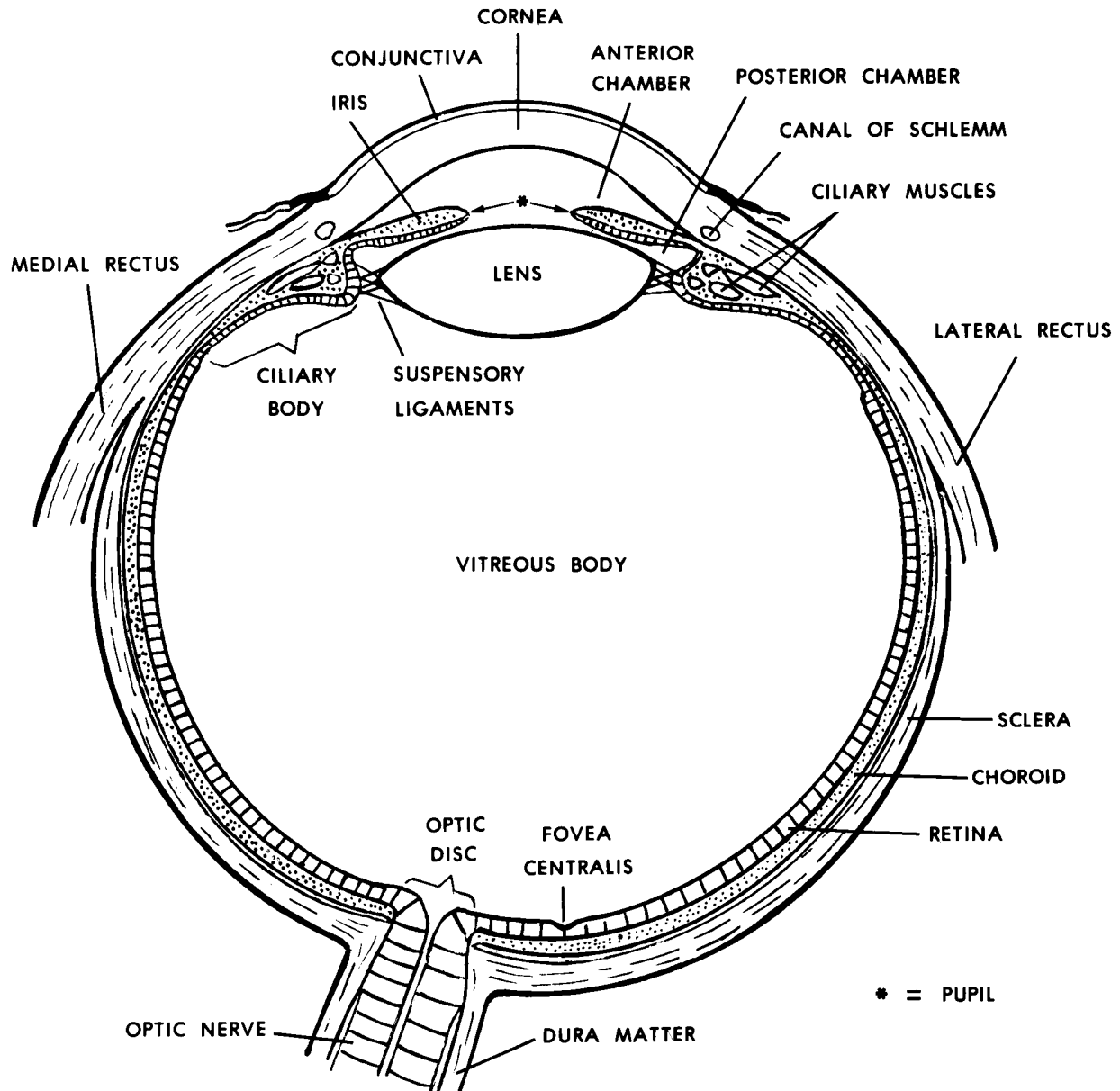


Figure 11-10. A horizontal section of the eyeball.

(3) Retina. The inner layer of the wall of the eyeball is known as the retina, retinal coat, or internal tunic. The actual photoreceptor elements are located in the retina at the back and sides of the eyeball. These elements are the rods and cones. They constitute the nervous portion of the retina. In the anterior part of the eyeball, the retina continues as a nonnervous portion.

c. **Internal Structures of the Eyeball.**

(1) The nervous retina.

(a) The photoreceptors of the nervous portion of the retina (figure 11-11) contain chemicals known as visual pigments (rhodopsin). The cones are more concentrated in the center at the back of the eyeball. The cones can register colors and are used for acute vision. However, cones require more intense light than do rods. The rods are distributed more toward the sides of the nervous retina. Although the rods are capable of registering less intense light, rods perceive only black and white.

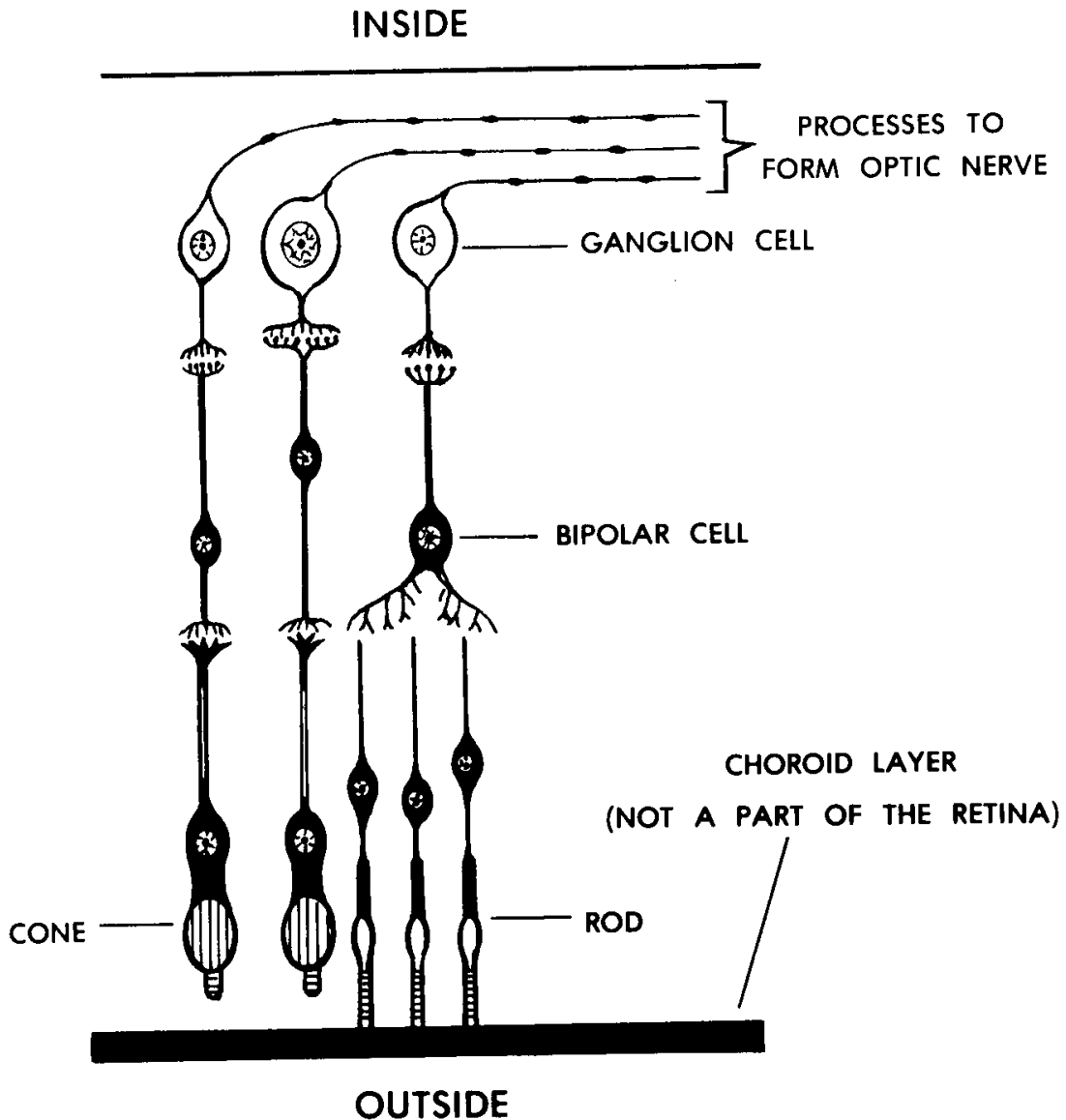


Figure 11-11. Cellular detail of the retina.

(b) If you look directly at an object, light from the object will fall in a small depression of the retina called the fovea centralis. The fovea centralis is at the posterior end of the eyeball, exactly opposite the centers of the cornea, pupil, and lens. The fovea centralis is found in a small yellow area of the retina called the macula lutea. The macula lutea is the area of the retina where vision is sharpest.

FOVEA = small depression

CENTRALIS = center

MACULA = spot

LUTEA = yellow

(c) Associated with the rods and cones are the beginnings of neurons of the optic nerve. These neurons pass out of the eyeball at the posterior end (in a point medial and superior to the fovea centralis). At the point of exit, there are no rods or cones. Therefore, it is called the blind spot (optic disc).

(2) Ciliary body. The anterior end of the choroid layer thickens to form a circular "picture frame" around the lens of the eyeball. This is also near the margin of the base of the cornea. The framelike structure is called the ciliary body. It includes mostly radial muscle fibers, which form the ciliary muscle.

(3) Ligaments. The lens is suspended in place by ligaments (fibers of the ciliary zonule). These ligaments connect the margin (equator) of the lens with the ciliary body.

(4) Lens. The lens is located in the center of the anterior of the eyeball, just behind the cornea.

(a) The lens is biconvex. This means that it has two outwardly curved surfaces. The anterior surface is flatter (less curved) than the posterior surface.

(b) The lens is transparent and elastic. (As one grows older, the lens becomes less and less elastic.) The ligaments maintain a tension upon the lens. This tension keeps the lens flatter and allows the lens to focus on distant objects. When the ciliary muscle contracts, the tension on the lens is decreased. The decreased tension allows the lens to thicken. The greater thickness increases the anterior curvature and allows close objects to be seen clearly.

(c) The process of focusing the lens for viewing close objects clearly is called accommodation. The process of accommodation is accompanied by a reduction in the pupil size as well as a convergence of the two central lines of sight (axes of eyeball).

(5) Iris. Another structure formed from the anterior portion of the choroid layer is the iris. The iris is located between the lens and the cornea.

(a) The pupil is the hole in the middle of the iris. The size of the pupil is controlled by radial and circular muscles in the iris. The radial muscles are dilators. The circular muscles are constrictors. By changing the size of the pupil, the iris controls the amount of light entering the eyeball.

(b) The iris may have many different colors. The actual color is determined by multiple genes.

(6) Chambers. The space between the cornea and the lens is called the anterior cavity. The space between the cornea and the iris is called the anterior chamber. The space between the iris and the lens is called the posterior chamber (see fig 11-10). Both chambers of the anterior cavity are filled with a fluid called the aqueous humor. The aqueous humor is secreted into the chambers by the ciliary body. It drains into the encircling canal of Schlemm, located in the angle between the cornea and the iris. This angle is called the iridocornealis angle.

(7) Vitreous body. Behind the lens is a jellylike material called the vitreous body.

11-28. THE ORBIT

The orbit is the cavity in the upper facial skull which contains the eyeball and its adnexa. The orbit is open anteriorly.

a. The floor of the orbit is generally horizontal. Its medial wall is generally vertical and straight from front to back. Since the lateral wall and roof converge to the rear, the orbit is a conelike cavity.

b. In the facial skull, the orbit is surrounded by a number of specific spaces. Superiorly, the roof of the orbit is also the floor of the anterior cranial cavity, where the frontal portion of the brain is. Just medial to the medial wall are the structures of the nasal chamber. Inferiorly, the floor of the orbit is also the roof of the maxillary sinus. Laterally, the wall of the orbit is the inner wall of the temporal fossa, a depression on each side of the skull where a fan-shaped chewing muscle (temporalis M.) is attached.

11-29. THE ADNEXA

The adnexa are the various structures associated with the eyeball.

a. **Extrinsic Ocular Muscles**. Among the adnexa are the extrinsic ocular muscles, which move the eyeball within the orbit. Each eyeball has associated with it six muscles made up of striated muscle fibers.

(1) Four recti. Four of these muscles are straight from the rear of the orbit to the eyeball. They are therefore known as the recti muscles (RECTUS = straight). Each name indicates the position of the muscles in relationship to the eyeball as follows:

lateral rectus M. (on the outer side)

superior rectus M. (above)

medial rectus M. (on the inner side)

inferior rectus M. (below)

(2) Two obliques. Two muscles approach the eyeball from the medial side and are known as the superior oblique and inferior oblique muscles.

b. **Eyelids**. Attached to the margins of the orbit, in front of the eyeball, are the upper and lower eyelids (palpebra (Latin), blepharon (Greek)). These have muscles for opening and closing the eyelids. The eyelashes (cilia) are special hairs of the eyelids which help protect the eyeball. The margins of the eyelids have special oil to prevent the loss of fluids from the area. The inner lining of the eyelids is continuous with the conjunctiva, a membrane over the anterior surface of the eyeball.

c. **Lacrimal Apparatus**. The conjunctiva must be kept moist and clean at all times. To do this, a lacrimal apparatus is associated with the eyelids. In the upper outer corner of the orbit is a lacrimal gland, which secretes a lacrimal fluid (tears) into the junction between the upper eyelid and the conjunctiva. By the motion of the eyeball and the eyelids (blinking), this fluid is moved across the surface of the conjunctiva to the medial inferior aspect. Here, the lacrimal fluid is collected and delivered into the nasal chamber by the nasolacrimal duct.

d. **Eyebrow**. The eyebrow (supercilium) is a special group of hairs above the orbit. The eyebrow serves to keep rain and sweat away from the eyeball.

e. **Optic Nerve (Cranial Nerve II)**. Neurons carry information from the photoreceptors of the nervous retina. They leave the eyeball at the blind spot. At the optic nerve, or second cranial nerve, the neurons pass to the rear of the orbit. There, the optic nerve exits through the optic canal into the cranial cavity. Beneath the brain, the optic nerves from both sides join to form the optic chiasma, in which half of the neurons from each optic nerve cross to the opposite side. From the optic chiasma, the right and left optic tracts proceed to the brain proper.

Section X. THE SPECIAL SENSE OF HEARING (AUDITORY)

11-30. GENERAL

The human ear serves two major special sensory functions--hearing (auditory) and equilibrium (balance). The stimulus for hearing is sound waves. The stimulus for equilibrium is gravitational forces.

a. **Methods of Sound Transmission.** The sound stimulus is transmitted in a variety of ways. Regardless of the actual transmission method, the sound stimulus is unchanged. Sound may be transmitted as:

(1) Airborne waves. These airborne waves have frequency (pitch) and amplitude (loudness or intensity).

(2) Mechanical oscillations (vibrations) of structures.

(3) Fluid-borne pressure pulses.

(4) Electrical impulses along the neurons to and in the brain.

b. **Sections of the Human Ear (figure 11-12).** The human ear has three major parts. Each part serves a specific function in the transmission and reception of the sound stimulus. The three parts are known as the external (outer) ear, the middle ear, and the internal (inner) ear.

11-31. THE EXTERNAL EAR

The external ear begins on the outside of the head in the form of a funnel-shaped auricle (pinna). Actually serving as a funnel, the auricle directs airborne sound waves into the external auditory meatus. The external auditory meatus is a tubular canal extending into the temporal portion of the skull.

11-32. THE MIDDLE EAR

a. **Tympanic Membrane.** At the inner end of the external auditory meatus is the tympanic membrane. The tympanic membrane (eardrum) is a circular membrane separating the external auditory meatus from the middle ear cavity. The tympanic membrane vibrates (mechanically oscillates) in response to airborne sound waves.

b. **Middle Ear Cavity.** On the medial side of the tympanic membrane is the middle ear cavity. The middle ear cavity is a space within the temporal bone.

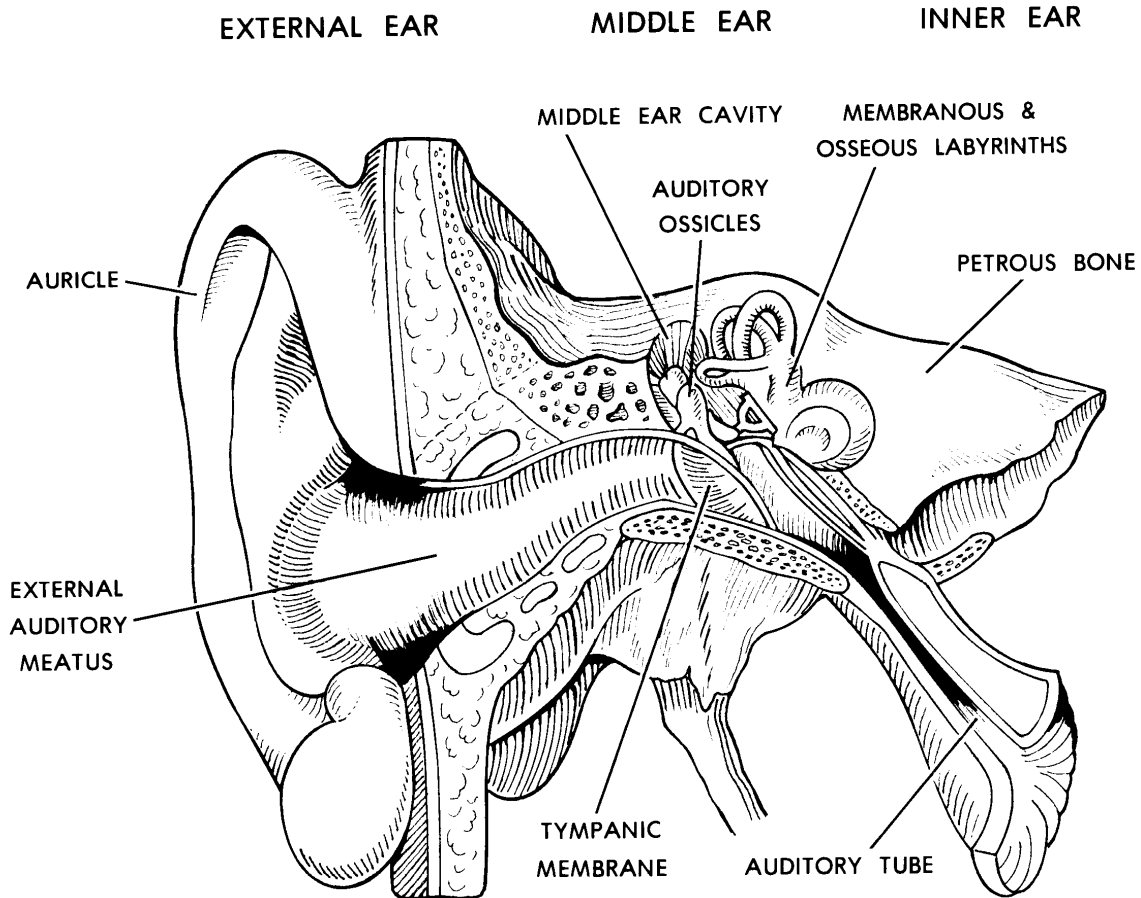


Figure 11-12. A frontal section of the human ear.

c. **Auditory Ossicles.** The auditory ossicles (OSSICLE = small bone) are three very small bones which form a chain across the middle ear cavity. They join the tympanic membrane with the medial wall of the middle ear cavity. In order, the ossicles are named as follows: malleus, incus, and stapes. The malleus is attached to the tympanic membrane. A sound stimulus is transmitted from the tympanic membrane to the medial wall of the middle ear cavity by way of the ossicles. The ossicles vibrate (mechanically oscillate) in response to the sound stimulus.

d. **Auditory (Eustachian) Tube.** The auditory tube is a passage connecting the middle ear cavity with the nasopharynx. The auditory tube maintains equal air pressure on the two sides of the tympanic membrane.

e. **Association With Other Spaces.** The middle ear cavity is associated with other spaces in the skull. The thin roof of the middle ear cavity is the floor of part of the cranial cavity. The middle ear cavity is continuous posteriorly with the mastoid air cells via the antrum (an upper posterior recess of the middle ear cavity).

11-33. THE INTERNAL EAR

a. Labyrinths (Figure 11-13).

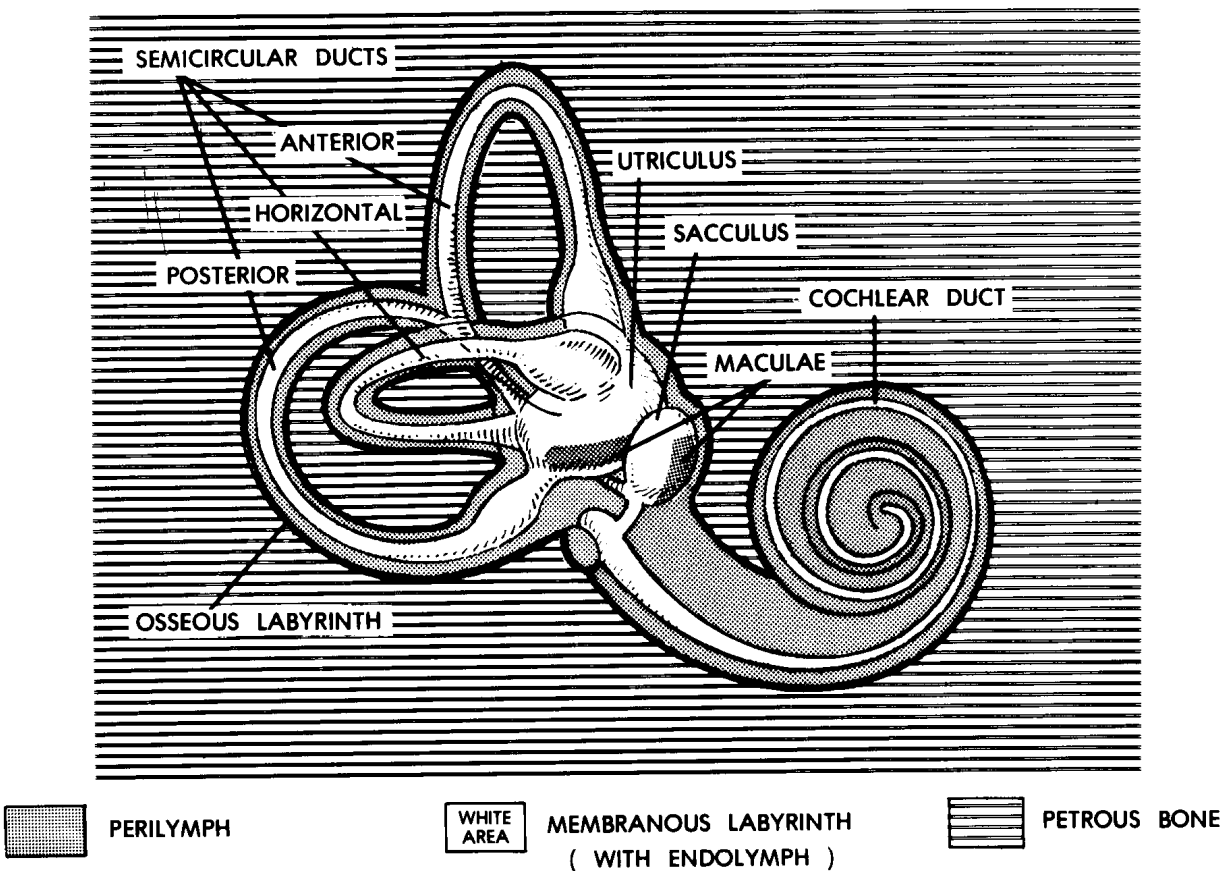


Figure 11-13. The labyrinths of the internal ear.

(1) Bony labyrinth. The bony labyrinth (LABYRINTH = a maze) is a complex cavity within the temporal bone. It has three semicircular canals, a vestibule (hallway), and a snail-shaped cochlear portion.

(2) Membranous labyrinth. The membranous labyrinth is a hollow tubular structure suspended within the bony labyrinth.

b. **Fluids of the Internal Ear**. The endolymph is a fluid filling the space within the membranous labyrinth. The perilymph is a fluid filling the space between the membranous labyrinth and the bony labyrinth. These fluids are continuously formed and drained away.

ENDO = within

PERI = around

c. **The Cochlea.** The cochlea is a spiral structure associated with hearing. It has 2-1/2 turns. Its outer boundaries are formed by the snail- shaped portion of the bony labyrinth.

(1) The central column or axis of the cochlea is called the modiolus. Extending from this central column is a spiral shelf of bone called the spiral lamina. A fibrous membrane called the basilar membrane (or basilar lamina) connects the spiral lamina with the outer bony wall of the cochlea. The basilar membrane forms the floor of the cochlear duct, the spiral portion of the membranous labyrinth. Within the cochlear duct, there is a structure on the basilar membrane called the organ of Corti. The organ of Corti has hairs which are the sensory receptors for the special sense of hearing.

LAMINA = thin plate

(2) Within the bony cochlea, the space above the cochlear duct is known as the scala vestibuli and the space below is known as the scala tympani. (See figure 11-14.) Since the scalae are joined at their apex, they form a continuous channel and the connection between them is called the helicotrema.

(3) Between the scalae and the middle ear cavity are two windows.

(a) Fenestra vestibuli (oval window). Between the middle ear cavity and the scala vestibuli is an oval window called the fenestra vestibuli. It is filled with the foot plate of the stapes.

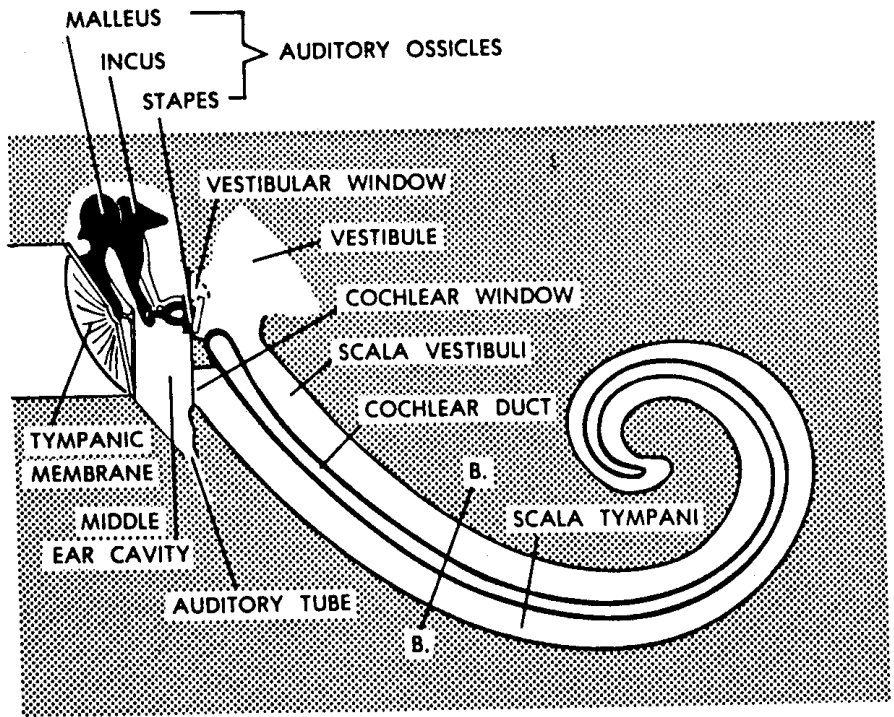
(b) Fenestra cochleae (round window). Between the middle ear cavity and the scala tympani is a round window called the fenestra cochleae. It is covered or closed by a membrane.

d. **Transmission.**

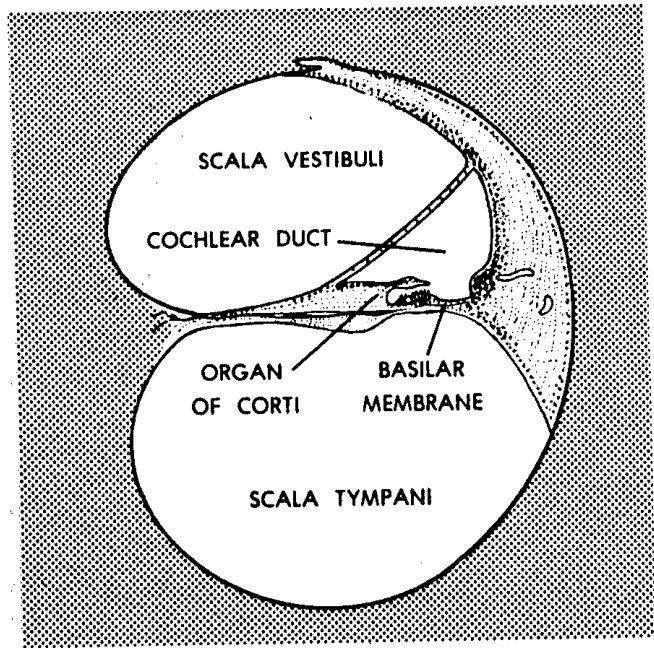
(1) The sound stimulus is transferred from the stapes to the perilymph of the scala vestibuli. Here the stimulus is transmitted as a pressure pulse in the fluid.

(2) In response, the basilar membrane of the cochlea vibrates (mechanically oscillates). Only selected portions of the basilar membrane vibrate at any one time, depending on the frequency of the sound stimulus.

(3) The hair cells of the organ of Corti at that particular location are mechanically stimulated. This stimulation is transferred to the neurons of the acoustic nerve (cranial nerve VIIIa). The acoustic nerve passes out of the modiolus into the internal auditory meatus of the temporal bone. From here, it enters into the cranial cavity and goes to the brain.



A - schematic relationships



B - cross-section

Figure 11-14. Diagram of the scalae.

Section XI. THE SPECIAL SENSE OF EQUILIBRIUM (BALANCE)

11-34. GENERAL

a. **Posture.** Posture is the specific alinement of the body parts at any given time. Humans can assume an infinite variety of postures. However, the truly erect posture is unique to humans.

b. **Equilibrium.** Equilibrium is the state of balance of the body. An erect standing human has a highly unstable equilibrium and therefore can easily fall. Through a variety of sensory inputs (visual, etc.) and postural reflexes, the body is maintained in its erect posture.

c. **Stimulus-Gravitational Forces.** A primary sensory input for equilibrium consists of gravitational forces. This input is received by the membranous labyrinth within the internal ear. The gravitational forces are of two types: static, when the body is standing still, and kinetic, when the body is moving in either linear (straight) or angular directions.

d. **Membranous Labyrinth.** The specific portions of the membranous labyrinth involved are the two sac-like structures--the sacculus and the utriculus. Each of these two structures has an area of special hair cells called the macula. In addition, there are three semicircular ducts located within the osseous semicircular canals of the temporal bone of the skull. Each semicircular duct has a crista, a little ridge of hair cells across the axis of the duct.

e. **"Body Sense."** All of the various sensory inputs related to the maintenance of equilibrium and posture are integrated within the brain as "body sense." Correct information is sent to the muscles of the body by means of specific postural reflexes in order to maintain the proper posture.

11-35. SACCULUS AND UTRICULUS

a. The sacculus and the utriculus are two sac-like portions of the membranous labyrinth. They are filled with endolymph.

b. On the wall of each sac is a collection of special hair cells known as the macula, which serves as a receptor organ for static and linear kinetic gravitational forces. The saccular macula and the utricular macula are oriented at more or less right angles to each other. For the pair of maculae in the membranous labyrinth of the right side, there is a corresponding pair in the labyrinth of the left side. Information from all of these maculae is sent into the brain for continuous sensing of the position of the head in space.

11-36. SEMICIRCULAR DUCTS (FIGURE 11-15)

Extending from and opening into the utriculus are three hollow structures called the semicircular ducts. Since the utriculus completes the circle for each duct, the ducts act as if they were complete circles.

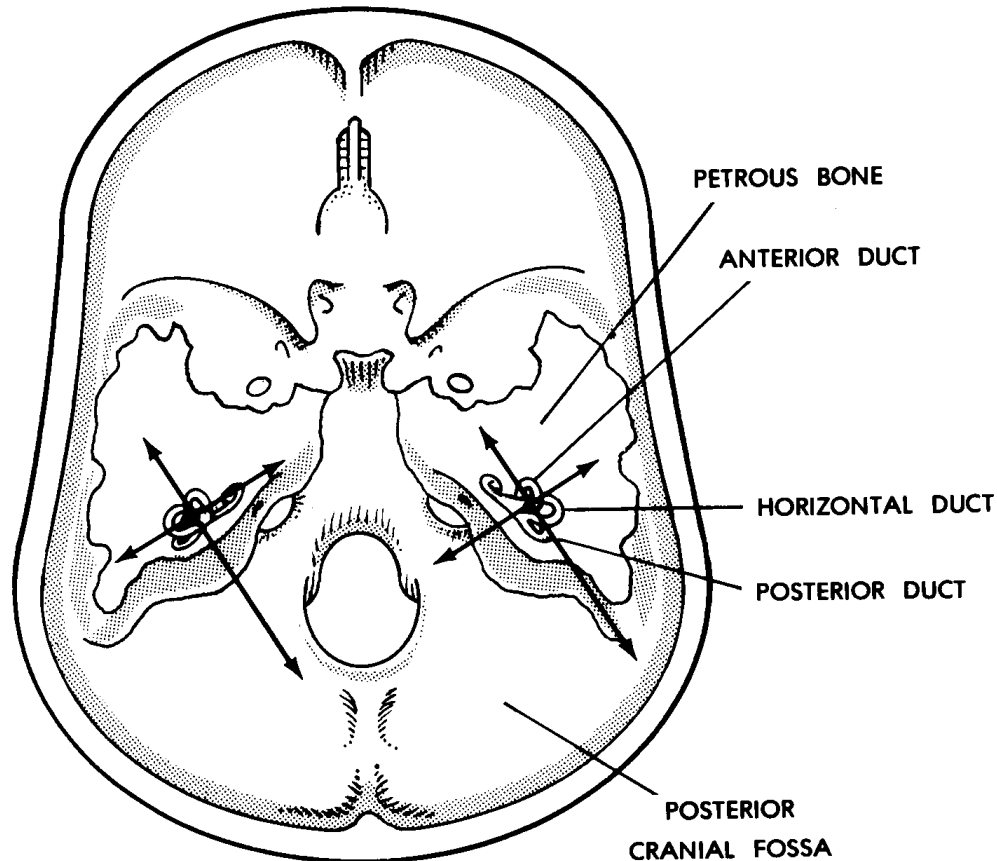


Figure 11-15. Diagram of semicircular duct orientation.

a. **Orientation.** Two of the ducts are vertically oriented (one anterior and one posterior). The third duct is essentially horizontal. The three ducts are all oriented at right angles to each other. In addition, the three ducts of one membranous labyrinth are matched or paired by the three ducts of the opposite membranous labyrinth.

b. **Ampullae and Cristae.** Each semicircular duct ends with an enlargement where it opens into the utriculus. This enlargement or swelling is called an ampulla. The crista is at a right angle to the axis of the duct. Movement of the endolymph within the duct--caused by movement of the head in space--deforms (bends) the hairs of the crista in specific directions. These are responses to linear and/or angular kinetic gravitational forces.

11-37. THE VESTIBULAR NERVE

The vestibular nerve (cranial nerve VIII) carries all this information from the maculae and cristae to the brain. The vestibular and auditory nerves are contained in the same fibrous sheath from the membranous labyrinth to the brain. Within the brain, the vestibular and auditory nerves separate into different pathways.

Section XII. CONTROLS IN THE HUMAN NERVOUS SYSTEM

11-38. GENERAL CONCEPT

The human nervous system can be thought of as a series of steps or levels. Each level is more complex than the level just below. No level is completely overpowered by upper levels, but each level is controlled or guided by the next upper level as it functions.

11-39. LEVELS OF CONTROL

a. **Reflex Arc.** The simplest and lowest level of control is the reflex arc (see para 11-15c). The reflex arc operates essentially on the level of the sensory input.

b. **Segmental Reflexes.** Segmental reflexes produce a wider reaction to a stimulus than the reflex arc. For this purpose, the nervous system is organized more complexly. Thus, information spreads to a wider area of the CNS. We can observe a greater reaction to the stimulus.

c. **Medullary Hindbrain.** In the hindbrainstem are to be found a number of nuclei (collections of neuron cell bodies) which monitor and control the activities of the visceral functions of the body, such as respiration, heartbeat, etc.

d. **Reticular Formation.** Within the substance of the brainstem is a diffuse system called the reticular formation.

RETICULAR = network

This reticular formation has a facilitatory (excitatory) area and an inhibitory area. These areas monitor and control general body functions, including sleep.

e. **Thalamus.** In the forebrainstem is a major collection of nuclei, all together called the thalamus. The thalamus is a primary relay for information going to and from the cerebrum and cerebellum. In the lowest animals, the thalamus represents the highest level of nervous control.

f. **Cerebellum.** The cerebellum has been greatly developed with many functional subdivisions. All together, it is one of the most important integrators of motor activity of the body.

g. **Cerebrum.** In humans, the highest level of nervous control is localized in the cerebrum. It is at this level that conscious sensation and volitional motor activity are localized. Even so, we can clearly designate three levels of control within the cerebrum:

(1) Visceral (vegetative) level. This level is concerned primarily with visceral activities of the body as related to fight-or-flight, fear, and other emotions.

(2) Patterned (stereotyped) motor actions. Here, activities of the body are standardized and repetitive in nature. An example of a stereo- typed pattern of muscle activity would be the sequence of muscle actions involved in walking.

(3) Volitional level. The volitional level is the highest and newest level of control. Here, unique, brand-new solutions can be created.

Continue with Exercises

EXERCISES, LESSON 11

REQUIREMENT. The following exercises are to be answered by completing the incomplete statement or by writing the answer in the space provided at the end of the question.

After you have completed all the exercises, turn to "Solutions to Exercises," at the end of the lesson and check your answers.

1. Two types of nervous tissues are _____ and _____.

What role does the first play in the nervous system?

What role does the second play?

2. Nervous tissues are specialized to:

- a. _____ stimuli.
- b. _____ information.
- c. _____ information.

3. A neuron is a nerve cell body and all of its _____s.

4. A dendrite carries impulses (toward) (away from) the cell body.

5. What is an axon?

6. Each item below indicates the number of poles for a type of neuron. Give the name which corresponds to each.

- a. More than two poles: _____.
- b. Two poles: _____.
- c. One pole: _____.

7. Each item below refers to the thickness of the myelin surrounding an axon. Give the letter indicating the type of neuron.

- a. Thickest: _____.
- b. Medium: _____.
- c. Thinnest: _____.

8. Each item below indicates the route over which impulses are transmitted. Give the type of neuron corresponding to each route.

- a. From receptor organs to the CNS: _____.
- b. From the CNS to muscles and glands: _____.
- c. From one neuron to another: _____.

9. What is meant by the term "continuity without contact" as related to neuron "connections"?

10. What is a synapse?

An axon terminates in tiny branches. What is at the end of each branch?

Where is neurotransmitter stored?

What is the presynaptic membrane?

What is the synaptic cleft?

What is the postsynaptic membrane?

11. What is a neuromuscular junction?

Compare the neuromuscular junction to a synapse.

12. The major divisions of the human nervous system are the _____ nervous system (____), the _____ nervous system (____), and the _____ nervous system (____). The CNS is made up of the _____ and the _____.

13. The three major subdivisions of the human brain are the _____, the _____, and the _____.

What is the brainstem?

14. The cerebellum is a spherical mass of nervous tissue attached to and covering the _____. Its three major parts are the _____ and right and left _____ hemispheres. In addition, the cerebellum has three pairs of stem-like connecting parts called _____. The outer cortex is composed of _____ matter, which is the _____s of neurons. More central is the _____ matter, which is the myelinated processes of _____. The cerebellum is the primary _____/_____ of motor actions of the body.

15. The cerebrum consists of two very much enlarged _____s connected to each other by a special structure called the c____c____. Each cerebral hemisphere is connected to the brainstem by a c____p____. The surface of each cerebral hemisphere is subdivided into areas known as l____. The names of the four lobes are f____, p____, o____, and t_____.

16. The space separating the two cerebral hemispheres is called the longitudinal _____. The shallow grooves in the surface of the cerebrum are called _____. The ridges outlined by the grooves are called _____.

17. The gray outer layer of each hemisphere is the _____. Deeper within the cerebral hemispheres, the tissue is colored _____. The "gray matter" represents the _____s of the neurons. The "white matter" represents the _____.

18. Groups of related functions are associated with specific areas of the cerebral cortex. For example, centers of speech and hearing are located along the lateral _____. Vision is centered in the _____ lobe. Sensory and motor functions are located along the central _____.

19. The ventricles of the brain are interconnected hollow spaces filled with _____. The right and left lateral ventricles are found in the cerebral _____s. The lateral ventricles are connected to the third ventricle by the i_____ f_____. The third ventricle is located in the f_____. The third and fourth ventricles are connected by the c_____ a_____. The fourth ventricle is located in the h_____. The fourth ventricle is continuous with the part of the spinal cord known as the c_____ c_____.

20. The spinal cord, located within the spinal _____l, is continuous with the b_____. The spinal cord has two enlargements. One, associated with nerves for the upper members, is called the _____ enlargement. The other, associated with the nerves for the lower members, is called the _____ enlargement. Nerves arising from the spinal cord are called _____ nerves.

There are how many pairs of spinal nerves?

21. In the cross section of the spinal cord, one can see a central region of gray matter shaped like an _____. Each arm of this figure is called a _____. The connecting link is called the gray _____. These horns are actually sections of the gray _____s. Since a column of white matter is a large bundle of processes, it is called a _____.

22. The skeletal covering for the brain is provided by bones of the _____. The overall skeletal structure covering the spinal cord is the _____ column (spine).

23. The brain and spinal cord have three different membranes surrounding them called _____. The tough outer covering for the CNS is the _____. Beneath it is the _____ space. The fine second membrane is called the _____. Beneath it is the _____ space, which is filled with _____. The delicate membrane applied directly to the surface of the brain and spinal cord is called the _____.

24. The two main pairs of arteries supply oxygenated blood to the brain are the internal _____ and _____ arteries. Beneath the brain, branches of these arteries join to form a circle, called the _____ circle (of _____). The main pair of veins carrying blood back toward the heart is the internal _____ veins. The blood supply of the spinal cord is by way of a combination of three l _____ arteries running along its length and reinforced by s _____ arteries from the sides.

25. Found in the cavities of the CNS is a clear fluid called _____ fluid (____). This fluid is found in the _____s of the brain, the sub _____ space, and the spinal cord's _____ canal. Special collections of arterial capillaries found in the roofs of the third and fourth ventricles are called choroid _____s. These structures continuously produce CSF from the _____ of the blood.

26. As CSF is produced by the choroid plexuses, it flows into all four _____s. CSF from the lateral ventricles flows into the _____ ventricle, and then through the _____ aqueduct into the _____ ventricle. By passing through three small holes in the roof of the fourth ventricle, CSF enters the subarachnoid _____. From here, the CSF is transported through the arachnoid _____ into the venous sinuses.

27. The peripheral nervous system is that portion of the nervous system which generally provides commands for _____ muscles and other _____ muscles and carries _____y information from the p _____ of the body. A nerve is a collection of neuron _____s, together and _____ the CNS.

28. The 12 pairs of nerves attached to the right and left sides of the brainstem are called _____ nerves. Each such nerve is identified by a _____ in order from _____ to _____ and an individual name. Attached to the sides of the spinal cord are 31 pairs of _____ nerves. For each, the region is designated by a _____; within each region, a nerve pair is identified by an _____.

29. Like a tree, a typical spinal nerve has _____s, a _____, and branches (called _____). Coming off of the posterior and anterior sides of the spinal cord are the posterior and anterior _____ of the spinal nerve. An enlargement on the posterior root is the _____. A ganglion is a collection of _____, together, outside the CNS. Laterally, the posterior and anterior roots of the spinal nerve join to form the spinal nerve _____. The spinal nerve trunk of each spinal nerve is located in the corresponding intervertebral _____ of the vertebral column. As the nerve trunk emerges laterally, it divides into the anterior and posterior _____.

30. If it carries information from the periphery to the CNS, it is an _____t (_____) neuron. If it carries information from the CNS to a muscle or gland, it is an _____t (_____) neuron.

31. An automatic reaction to a stimulus is referred to as a _____. The pathway from the receptor organ to the reacting muscle is called the _____.

32. The pathway of a general reflex arc involves a minimum of ____ structures. The stimulus is received by a _____ organ. That information is transmitted to the CNS by the _____t (_____) neuron. Within the spinal cord, there is a special neuron connecting the afferent neuron to the efferent neuron; this special connecting neuron is called the _____. Carrying the appropriate command from the spinal cord to the reacting muscle is the _____t (_____) neuron. The reacting muscle is called the e_____ organ.

33. The autonomic nervous system is that portion of the nervous system generally concerned with commands for s_____ muscle, c_____ muscles, and _____s.

34. In the ANS, the number of neurons connecting the CNS with a visceral organ is always _____. The cell bodies of the second neuron form a collection outside the CNS, called a _____. The first neuron extends from the CNS to the ganglion and is therefore called the _____ neuron. Cell bodies of the second neurons make up the _____. The second neuron's processes extend from the ganglion to the _____. Thus, the second neuron is called the _____ neuron.

35. The efferent pathways of the ANS fall into two major divisions. The one most active during a "fight-or-flight" reaction is the _____-_____ outflow (_____ nervous system). The other is the _____-_____ outflow (_____ nervous system).

36. The intermediolateral gray columns from the T-1 to the L-2 levels of the spinal cord are made up of the cell bodies of the ____-ganglionic sympathetic neurons. The sympathetic ganglia are made up of the cell bodies of the ____-ganglionic sympathetic neurons. The sympathetic NS activates those visceral organs needed to _____. It deactivates those which are _____.

37. Four pairs of nuclei in the brainstem and the intermediolateral gray columns at the S-2 through S-4 levels of the spinal cord are made up of the cell bodies of the p_____ p_____ neurons. The intramural ganglia within the walls of the _____ organs are made up of the cell bodies of the p_____ p_____ neurons. As compared to that of the sympathetic NS, the parasympathetic NS has the (same) (opposite) effect on visceral organs.

38. What is a pathway?

39. What is the neuraxis?

40. What is a sensory pathway?

41. What is a motor pathway?

42. The human nervous system has several levels of control. The lowest level is the _____ level. The highest level is the _____ level. Between, there are several progressively _____ levels. All information input and all information output are _____ d and _____ d.

43. The right half of the brain controls the _____ side of the body. The left half of the brain controls the _____ side of the body.

44. A pyramidal pathway is primarily concerned with _____ (_____) control of body parts, particularly the _____ movements of _____s. These pathways are called pyramidal because their neuron processes help to make up structures in the base of the brain called _____.

45. An extrapyramidal pathway is primarily concerned with _____ (_____) control of body parts for purposes of _____.

46. Name examples of general senses.

a. _____.

b. _____.

c. _____.

d. _____.

47. Name examples of special senses.

a. _____.

b. _____.

c. _____.

d. _____.

e. _____.

48. The general sensory pathway is from the _____ organ, via the _____ nerves, to the _____. This general pathway then ascends fiber tracts in the _____. The pathway ends in the central area of the opposite _____ hemisphere.

49. The receptors for the sense of smell are special hair cells called c____s. These are found in the o_____ e_____, high in the n_____ c_____s in the head. The information received is transmitted by way of the o_____ nerves to the _____y bulbs and then into the opposite _____ hemisphere.

50. Describe the sensory receptors for the special sense of taste.

The information received is transmitted to the opposite side of the brain by three _____ nerves.

51. What is the eyeball?

The eyeball is shaped like a _____.

52. The outermost layer of the eyeball is colored _____ and is made up of very dense _____; it is known as the _____. Its anterior portion is called the _____. The major focusing device for the eyeball is the _____.

53. The middle layer of the wall of the eyeball is known as the _____. This layer is richly supplied with _____ and pigmented with a _____ material.

54. The inner layer of the wall of the eyeball is known as the _____. The actual photoreceptor elements are located at the _____ and the _____s. These elements are the _____s and the _____s.

55. The elements which register colors are the _____. However, _____ require more intense light than do _____. Rods register only _____.

56. What are the fovea centralis and macula lutea?

.

57. What is the blind spot?

.

58. The thickening of the choroid layer around the edge of the lens is called the _____. It includes radial muscle fibers making up the _____ muscle.

59. Describe the lens and the process of accommodation.

60. The space between the cornea and the iris is called the _____. The space between the iris and the lens is called the _____. Together, these make up the space between the cornea and the lens, called the _____ and filled with the _____. This drains into the encircling _____, located in the angle between the _____ and the _____. Behind the lens is a jellylike material called the _____. It fills the _____ cavity of the eyeball.

61. The orbit is the cavity in the upper facial skull which contains the _____ and its _____. The orbit is shaped roughly like a _____.

62. Examples of the adnexa are the:

a. _____.

b. _____.

c. _____.

d. _____.

e. _____.

63. Of the six extrinsic ocular muscles, four are called _____ muscles. Two are _____ muscles. The lateral rectus M. is on the _____ side of the eyeball. The superior rectus M. is _____ the eyeball. The medial rectus M. is on the _____ side of the eyeball. The inferior rectus M. is _____ the eyeball. The superior oblique and inferior oblique muscles approach the eyeball from the _____ side.

64. Attached to the margins of the orbit are the upper and lower _____. These have special hairs called _____. The inner lining of the eyelids is continuous with the _____, a membrane over the anterior surface of the eyeball.

65. In the upper outer corner of the orbit is a lacrimal _____, which secretes a lacrimal _____, which is ultimately collected and delivered into the nasal chamber by the _____ duct.

66. Neurons carry information from the photoreceptors located in the nervous _____. They leave the eyeball at the _____. Passing to the rear of the orbit, the neurons now belong to the _____ nerve (cranial nerve ____). The optic nerve enters the cranial cavity by passing through the _____ canal. Beneath the brain, the optic nerves from both sides join to form the _____, in which half of the neurons from each optic nerve _____. From the optic chiasma, the right and left optic _____s proceed to the brain proper.

67. The human ear has two major special sensory functions: _____ (_____) and _____ (_____). The three parts of the human ear are the _____ (_____) ear, the _____ ear, and the _____ (_____) ear.

68. The external flap of the ear is called the _____ (_____). It directs airborne sound waves into the canal called the external auditory _____, which extends into the _____ portion of the skull.

69. Where is the tympanic membrane?

On the medial side of the tympanic membrane, there is a space within the temporal bone called the _____.

What are the auditory ossicles?

The auditory ossicles respond to a sound stimulus by _____. From the lateral to the medial ends, the names of the ossicles are: _____, _____, and _____. The auditory tube connects the middle ear cavity with the _____.

70. What is the bony labyrinth?

It has three _____ canals, a _____ (hallway), and a snail-shaped _____ portion.

What is the membranous labyrinth?

71. Where is the endolymph found?

Where is the perilymph found?

72. The cochlea is a _____ structure associated with _____ing. It has _____ turns. Its outer boundaries are formed by the snail-shaped portion of the _____.

73. The central column of the cochlea is called the m_____. Extending from this central column is a spiral shelf of bone called the s_____ l_____. Connecting this shelf with the outer bony wall is a fibrous membrane called the b_____ membrane. This membrane forms the floor of the spiral portion of the membranous labyrinth called the c_____ d____. This contains a structure with hairs, sensory receptors of hearing; this structure is called the organ of _____.

74. Within the bony cochlea, the space above the cochlear duct is known as the _____ and the space below is known as the _____. Between the middle ear cavity and the upper space is an oval window called the fenestra _____. Between the middle ear cavity and the lower space is a round window called the fenestra _____.

75. A sound stimulus is transferred from the stapes to the fluid _____ of the _____. In response, the b_____ membrane of the cochlea vibrates. The hair cells of the _____ of _____ are mechanically stimulated. This stimulation is transferred to the neurons of the _____ nerve, which passes out of the modiolus into the internal auditory _____ of the temporal bone. From here, the nerve enters the _____ cavity and goes to the _____.

76. The two sac-like portions of the membranous labyrinth are the _____ and the _____. They are filled with _____. On the wall of each sac is a collection of special hair cells known as the _____, which serves as a receptor organ for _____ and linear _____ gravitational forces. The saccular macula and the utricular macula are oriented at more or less _____° angles to each other.

77. Extending from and opening into the utricle are three hollow structures called the _____ ducts. The utricle completes the circle for each _____. The three ducts are all oriented at _____° angles to each other. Where it opens into the utricle, each semicircular duct ends in an enlargement called an _____. Movement of the fluid endolymph bends the hairs of the _____ in specific directions. These are responses to _____ and/or _____ kinetic gravitational forces.

78. Carrying the information from the maculae and the cristae to the brain is the _____ nerve. Contained in the same fibrous sheath from the membranous labyrinth to the brain are the v_____ and a_____ nerves.

79. The simplest and lowest level of control is the _____. Producing wider reactions to stimuli are s_____ reflexes. A number of nuclei in the hindbrain monitor and control v_____l functions of the body, including r_____ and h_____b_____. The facilitatory and inhibitory areas of the reticular formation monitor and control general body functions, including _____. The thalamus is a primary relay for information going to and from the _____ and _____. One of the most important integrators of motor activity of the body is the _____.

80. In humans, the highest level of control is in the _____. Here, we can clearly designate three levels of control:

a. The first level is concerned with _____ activities of the body, as related to _____, fear, and other emotions.

b. At the second level, activities of the body are s_____d and repetitive in nature. An example is the sequence of muscle actions involved in w_____ing.

c. At the third level, brand new solutions can be created. This is the v_____ level.

Check Your Answers on Next Page

SOLUTIONS TO EXERCISES, LESSON 11

1. Two types of nervous tissues are neurons (nerve cells) and glia (neuroglia). The neuron is the basic structural unit of the nervous system. The glia are cells of supporting tissue for the nervous system. (para 11-1)
2. Nervous tissues are specialized to:
 - a. Receive stimuli.
 - b. Transmit information.
 - c. Store information. (para 11-2)
3. A neuron is a nerve cell body and all of its processes. (para 11-3)
4. A dendrite carries impulses toward the cell body. (para 11-5a)
5. An axon is a neuron process which transmits information from the cell body to the next unit. (para 11-5b)
6. More than two poles: multipolar neuron.
Two poles: bipolar neuron.
One pole: unipolar neuron.
(para 11-6a)
7. Thickest: A.
Medium: B.
Thinnest: C. (para 11-6b)
8. From receptor organs to the CNS: sensory neurons.
From the CNS to muscles and glands: motor neurons.
From one neuron to another: interneurons. (para 11-6c)
9. The term "continuity without contact" refers to the fact that neurons do not actually touch. Thus, there is no electrical transmission of impulses from one neuron to the next. In fact, information is transferred across the synaptic cleft by chemicals called neurotransmitters. (para 11-7)
10. A synapse is a "connection" between two neurons. An axon terminates in tiny branches. At the end of each branch is a terminal bulb. Neurotransmitters are stored in bundles called synaptic vesicles located within each terminal bulb. The presynaptic membrane is the thickened layer of the terminal bulb which faces the synaptic cleft and through which pass the neurotransmitters before entering the synaptic cleft. The synaptic cleft is the space between the terminal bulb of the first neuron and the dendrite or cell body of the second neuron. The postsynaptic membrane is that portion of the membrane of the second neuron which lies near the terminal bulb of the first neuron. (para 11-7a)

11. A neuromuscular junction is a "connection" between the terminal of a motor neuron and a muscular fiber. Comparison: The neuromuscular junction has an organization identical to a synapse. However, the bulb is larger and protrudes into the surface of the muscle fiber. The postsynaptic membrane is also larger and has foldings. (para 11-7b)
12. The major divisions of the human nervous system are the central nervous system (CNS), the peripheral nervous system (PNS), and the autonomic nervous system (ANS). The CNS is made up of the brain and the spinal cord. (para 11-8)
13. The three major subdivisions of the human brain are the brainstem, the cerebellum, and the cerebrum. The brainstem is that part of the brain remaining after removal of the cerebrum and cerebellum. It is the basal portion. Together with the spinal cord, it is known as the neuraxis. (para 11-9a)
14. The cerebellum is a spherical mass of nervous tissue attached to and covering the hindbrainstem. Its three major parts are the vermis and right and left cerebellar hemispheres. In addition, the cerebellum has three pairs of stem-like connecting parts called peduncles. The outer cortex is composed of gray matter, which is the cell bodies of neurons. More central is the white matter, which is the myelinated processes of neurons. The cerebellum is the primary coordinator/ integrator of motor actions of the body. (para 11-9b)
15. The cerebrum consists of two very much enlarged hemispheres connected to each other by a special structure called the corpus callosum. Each cerebral hemisphere is connected to the brainstem by a cerebral peduncle. The surface of each cerebral hemisphere is subdivided into areas known as lobes. The names of the four lobes are frontal, parietal, occipital, and temporal. (para 11-9c)
16. The space separating the two cerebral hemispheres is called the longitudinal fissure. The shallow grooves in the surface of the cerebrum are called sulci. The ridges outlined by the sulci are called gyri. (para 11-9c(1))
17. The gray outer layer of each hemisphere is the cerebral cortex. Deeper within the cerebral hemispheres, the tissue is colored white. The "gray matter" represents the cell bodies of the neurons. The "white matter" represents the axons. (para 11-9c(2))
18. Groups of related functions are associated with specific areas of the cerebral cortex. For example, centers of speech and hearing are located along the lateral sulcus. Vision is centered in the occipital lobe. Sensory and motor functions are located along the central sulcus. (para 11-9c(3))

19. The ventricles of the brain are interconnected hollow spaces filled with CSF. The right and left lateral ventricles are found in the cerebral hemispheres. The lateral ventricles are connected to the third ventricle by the interventricular foramen. The third ventricle is located in the forebrainstem. The third and fourth ventricles are connected by the cerebral aqueduct. The fourth ventricle is located in the hindbrainstem. The fourth ventricle is continuous with the part of the spinal cord known as the central canal. (para 11-9d)
20. The spinal cord, located within the spinal canal, is continuous with the brainstem. The spinal cord has two enlargements. One, associated with nerves for the upper members, is called the cervical enlargement. The other, associated with nerves for the lower members, is called the lumbosacral enlargement. Nerves arising from the spinal cord are called spinal nerves. There are 31 pairs of spinal nerves. (para 11-10a)
21. In the cross section of the spinal cord, one can see a central region of gray matter shaped like an H. Each arm of this figure is called a horn. The connecting link is called the gray commissure. These horns are actually sections of the gray columns. Since a column of white matter is a large bundle of processes, it is called a funiculus. (para 11-10b)
22. The skeletal covering for the brain is provided by bones of the cranium. The overall skeletal structure covering the spinal cord is the vertebral column (spine). (para 11-11a)
23. The brain and spinal cord have three different membranes surrounding them called meninges. The tough outer covering for the CNS is the dura mater. Beneath it is the subdural space. The fine second membrane is called the arachnoid mater. Beneath it is the subarachnoid space, which is filled with CSF. The delicate membrane applied directly to the surface of the brain and spinal cord is called the pia mater. (para 11-11b)
24. The two main pairs of arteries supplying oxygenated blood to the brain are the internal carotid and the vertebral arteries. Beneath the brain, branches of these arteries join to form a circle, called the cerebral circle (of Willis). The main pair of veins carrying blood back toward the heart is the internal jugular veins. The blood supply of the spinal cord is by way of a combination of three longitudinal arteries running along its length and reinforced by segmental arteries from the sides. (para 11-12)
25. Found in the cavities of the CNS is a clear fluid called cerebrospinal fluid (CSF). This fluid is found in the ventricles of the brain, the subarachnoid space, and the spinal cord's central canal. Special collections of arterial capillaries found in the roofs of the third and fourth ventricles are called choroid plexuses. These structures continuously produce CSF from the plasma of the blood. (para 11-13)

26. As CSF is produced by the choroid plexuses, it flows into all four ventricles. CSF from the lateral ventricles flows into the third ventricle and then through the cerebral aqueduct into the fourth ventricle. By passing through three small holes in the roof of the fourth ventricle, CSF enters the subarachnoid space. From here, the CSF is transported through the arachnoid villi into the venous sinuses. (para 11-13b)
27. The peripheral nervous system is that portion of the nervous system which generally provides commands for skeletal muscles and other striated muscles and carries sensory information from the periphery of the body. A nerve is a collection of neuron processes, together and outside the CNS. (para 11-14a)
28. The 12 pairs of nerves attached to the right and left sides of the brainstem are called cranial nerves. Each such nerve is identified by a Roman numeral in order from I to XII and an individual name. Attached to the sides of the spinal cord are 31 pairs of spinal nerves. For each, the region is designated by a letter; within each region, a nerve pair is identified by an Arabic numeral. (para 11-14c)
29. Like a tree, a typical spinal nerve has roots, a trunk, and branches (called rami). Coming off of the posterior and anterior sides of the spinal cord are the posterior and anterior roots of the spinal nerve. An enlargement on the posterior root is the posterior root ganglion. A ganglion is a collection of neuron cell bodies, together, outside the CNS. Laterally, the posterior and anterior roots of the spinal nerve join to form the spinal nerve trunk. The spinal nerve trunk of each spinal nerve is located in the corresponding intervertebral foramen of the vertebral column. As the nerve trunk emerges laterally, it divides into the anterior and posterior rami. (para 11-15a)
30. If it carries information from the periphery to the CNS, it is an afferent (sensory) neuron. If it carries information from the CNS to a muscle or gland, it is an efferent (motor) neuron. (para 11-15b)
31. An automatic reaction to a stimulus is referred to as a reflex. The pathway from the receptor organ to the reacting muscle is called the reflex arc. (para 11-15c(1))
32. The pathway of a general reflex arc involves a minimum of five structures. The stimulus is received by a receptor organ. The information is transmitted to the CNS by the afferent (sensory) neuron. Within the spinal cord, there is a special neuron connecting the afferent neuron to the efferent neuron; this special connecting neuron is called the interneuron (or internuncial neuron). Carrying the appropriate command from the spinal cord to the reacting muscle is efferent (motor) neuron. The reacting muscle is called the effector organ. (para 11-15c(2))
33. The autonomic nervous system is that portion of the nervous system generally concerned with commands for smooth muscle, cardiac muscle, and glands. (para 11-16)

34. In the ANS, the number of neurons connecting the CNS with a visceral organ is always two. The cell bodies of the second neurons form a collection outside the CNS, called a ganglion. The first neuron extends from the CNS to the ganglion and is therefore called the preganglionic neuron. Cell bodies of the second neurons make up the ganglion. The second neuron's processes extend from the ganglion to the visceral organ. Thus, the second neuron is called the post-ganglionic neuron. (para 11-16b)
35. The efferent pathways of the ANS fall into two major divisions. The one most active during a "fight-or-flight" reaction is the thoraco- lumbar outflow (sympathetic nervous system). The other is the cranio- sacral outflow (parasympathetic nervous system). (para 11-16c)
36. The intermediolateral gray columns from the T-1 to the L-2 levels of the spinal cord are made up of the cell bodies of the preganglionic sympathetic neurons. The sympathetic ganglia are made up of the post- ganglionic sympathetic neurons. The sympathetic NS activates those visceral organs needed to mobilize energy for action. It deactivates those which are not needed. (para 11-17)
37. Four pairs of nuclei in the brainstem and the intermediolateral gray columns at the S-2 through S-4 levels of the spinal cord are made up of the cell bodies of the preganglionic parasympathetic neurons. The intramural ganglia within the walls of the central visceral organs are made up of the cell bodies of the post-ganglionic parasympathetic neurons. As compared to that of the sympathetic NS, the parasympathetic NS has the opposite effect on visceral organs. (para 11-18)
38. A pathway is the series of nervous structures utilized in the transmission of an item of information. (para 11-19a(1))
39. The neuraxis is the brainstem and the spinal cord, considered together as one structure. (para 11-19a(2))
40. A sensory pathway is a series of nervous structures used to transmit information from the body to the CNS. (para 11-19b(1))
41. A motor pathway is a series of nervous structures used to transmit information from the CNS to the body. (para 11-19b(2))
42. The human nervous system has several levels of control. The lowest level is the simple reflex arc. The highest level is the conscious level. Between, there are several progressively higher levels. All information input and all information output are monitored and evaluated. (para 11-19c)43. The right half of the brain controls the left side of the body. The left half of the brain controls the right side of the body. (para 11-20)

44. A pyramidal motor pathway is primarily concerned with volitional (voluntary) control of body parts, particularly the fine movements of hands. These pathways are called pyramidal because their neuron processes help to make up structures in the base of the brain called pyramids. (para 11-20a)
45. An extrapyramidal pathway is primarily concerned with automatic (nonvolitional) control of body parts for purposes of coordination. (para 11-20b)
46. Examples of general senses are:
- Pain.
 - Temperature (warm and cold).
 - Touch (light and deep).
 - Proprioception ("body sense"). (para 11-21c)
47. Examples of special senses are:
- Smell (olfaction).
 - Taste (gustation).
 - Vision.
 - Hearing (auditory).
 - Equilibrium. (para 11-21d)
48. The general sensory pathway is from the receptor organ, via the PNS nerves, to the CNS. This general pathway then ascends fiber tracts in the neuraxis. The pathway ends in the central area of the opposite cerebral hemisphere. (para 11-21e)
49. The receptors for the sense of smell are special hair cells called chemoreceptors. These are found in the olfactory epithelium, high in the nasal chambers in the head. The information received is transmitted by way of the olfactory nerves to the olfactory bulbs and then into the opposite cerebral hemisphere. (paras 11-22, 11-23)
50. Special hair cells (chemoreceptors) are found in the taste buds, scattered over the tongue and the rear of the mouth. These cells, which react to dispersed or dissolved food molecules, are the sensory receptors for the special sense of taste. The information received is transmitted to the opposite side of the brain by three cranial nerves. (paras 11-24, 11-25)
51. The eyeball is the sense organ containing the receptor tissues for the special sense of vision. The eyeball is shaped like a bulb (or sphere). (paras 11-26c, 11-27a)

52. The outermost layer of the eyeball is colored white and is made up of very dense FCT; it is known as the sclera, scleral coat, or fibrous tunic. Its anterior portion is called the cornea. The major focusing device for the eyeball is the cornea. (para 11-27b(1))
53. The middle layer of the wall of the eyeball is known as the choroid, choroid coat, or vascular tunic. This layer is richly supplied with blood vessels and pigmented with a black material. (para 11-27b(2))
54. The inner layer of the wall of the eyeball is known as the retina, retinal coat, or internal tunic. The actual photoreceptor elements are located at the back and the sides. These elements are the rods and the cones. (para 11-27b(3))
55. The elements which register colors are the cones. However, cones require more intense light than do rods. Rods register only black and white. (para 11-27c(1)(a))
56. The fovea centralis is a small depression at the posterior end of the eyeball opposite the pupil. The macula lutea is a small yellow area of the retina where vision is sharpest. It includes the fovea centralis. (para 11-27c(1)(b))
57. The blind spot is the point of exit of the optic nerve, at the posterior end of the eyeball where there are no rods and cones. (para 11-27c(1)(c))
58. The thickening of the choroid layer around the edge of the lens is called the ciliary body. It includes radial muscle fibers making up the ciliary muscle. (para 11-27c(2))
59. The lens is biconvex. The anterior surface is flatter than the posterior surface. The lens is transparent and elastic. Its thickness varies with contraction or relaxation of the ciliary muscle. Accommodation is the process in which close objects are seen more clearly; it involves contraction of the ciliary muscle, reduction in pupil size, and convergence of the lines of sight. (para 11-27c(4))
60. The space between the cornea and the iris is called the anterior chamber. The space between the iris and the lens is called the posterior chamber. Together, these make up the space between the cornea and the lens called the anterior cavity and filled with the aqueous humor. This drains into the encircling canal of Schlemm, located in the angle between the cornea and the iris. Behind the lens is a jellylike material called the vitreous body. It fills the posterior cavity of the eyeball. (para 11-27c(6), (7))
61. The orbit is the cavity in the upper facial skull which contains the eyeball and its adnexa. The orbit is shaped roughly like a cone. (para 11-28a)

62. Examples of the adnexa are the:
- Extrinsic ocular muscles.
 - Eyelids.
 - Lacrimal apparatus.
 - Eyebrow.
 - Optic nerve. (para 11-29)
63. Of the six extrinsic ocular muscles, four are called recti muscles. Two are oblique muscles. The lateral rectus M. is on the outer side of the eyeball. The superior rectus M. is above the eyeball. The medial rectus M. is on the inner side of the eyeball. The inferior rectus M. is below the eyeball. The superior oblique and inferior oblique muscles approach the eyeball from the medial side. (para 11-29a)
64. Attached to the margins of the orbit are the upper and lower eyelids. These have special hairs called eyelashes. The inner lining of the eyelids is continuous with the conjunctiva, a membrane over the anterior surface of the eyeball. (para 11-29b)
65. In the upper outer corner of the orbit is a lacrimal gland, which secretes a lacrimal fluid, which is ultimately collected and delivered into the nasal chamber by the nasolacrimal duct. (para 11-29c)
66. Neurons carry information from the photoreceptors located in the nervous retina. They leave the eyeball at the blind spot. Passing to the rear of the orbit, the neurons now belong to the optic nerve (cranial nerve II). The optic nerve enters the cranial cavity by passing through the optic canal. Beneath the brain, the optic nerves from both sides join to form the optic chiasma, in which half of the neurons from each optic nerve cross to the opposite side. From the optic chiasma, the right and left optic tracts proceed to the brain proper. (para 11-29e)
67. The human ear has two major special sensory functions: hearing (auditory) and equilibrium (balance). The three parts of the human ear are the external (outer) ear, the middle ear, and the internal (inner) ear. (para 11-30)
68. The external flap of the ear is called the auricle (pinna). It directs airborne sound waves into the canal called the external auditory meatus, which extends into the temporal portion of the skull. (para 11-31)
69. The tympanic membrane is between the external auditory meatus and the middle ear cavity. On the medial side of the tympanic membrane, there is a space within the temporal bone called the middle ear cavity. The auditory ossicles are three very small bones linking the tympanic membrane to the medial wall of the middle ear cavity. The auditory ossicles respond to a sound stimulus by vibrating (mechanically oscillating). From the lateral to the medial ends, the names of the

ossicles are: malleus, incus, and stapes. The auditory tube connects the middle ear cavity with the nasopharynx. (para 11-32)

70. The bony labyrinth is a complex cavity within the temporal bone. It has three semi-circular canals, a vestibule (hallway), and a snail-shaped cochlear portion. The membranous labyrinth is a hollow tubular structure suspended within the bony labyrinth. (para 11-33a)
71. The endolymph fills the space within the membranous labyrinth. The perilymph fills the space between the membranous labyrinth and the bony labyrinth. (para 11-33b)
72. The cochlea is a spiral structure associated with hearing. It has 2-1/2 turns. Its outer boundaries are formed by the snail-shaped portion of the bony labyrinth. (para 11-33c)
73. The central column of the cochlea is called the modiolus. Extending from this central column is a spiral shelf of bone called the spiral lamina. Connecting this shelf with the outer bony wall is a fibrous membrane called the basilar membrane. This membrane forms the floor of the spiral portion of the membranous labyrinth called the cochlear duct. This contains a structure with hairs, sensory receptors of hearing; this structure is called the organ of Corti. (para 11-33c(1))
74. Within the bony cochlea, the space above the cochlear duct is known as the scala vestibuli and the space below is known as the scala tympani. Between the middle ear cavity and the upper space is an oval window called the fenestra vestibuli. Between the middle ear cavity and the lower space is a round window called the fenestra cochleae. (para 11-33c(2), (3))
75. A sound stimulus is transferred from the stapes to the fluid perilymph of the scala vestibuli. In response, the basilar membrane of the cochlea vibrates. The hair cells of the organ of Corti are mechanically stimulated. This stimulation is transferred to the neurons of the acoustic nerve, which passes out of the modiolus into the internal auditory meatus of the temporal bone. From here, the nerve enters the cranial cavity and goes to the brain. (para 11-33d)
76. The two sac-like portions of the membranous labyrinth are the sacculus and the utricle. They are filled with endolymph. On the wall of each sac is a collection of special hair cells known as the macula, which serves as a receptor organ for static and linear kinetic gravitational forces. The saccular macula and the utricular macula are oriented at more or less 90° angles to each other. (para 11-35)
77. Extending from and opening into the utricle are three hollow structures called the semicircular ducts. The utricle completes the circles for each duct. The three ducts are all oriented at 90° angles to each other. Where it opens into the utricle, each semicircular duct ends in an enlargement called an ampulla.

Movement of the fluid endolymph bends the hairs of the crista in specific directions. These are responses to linear and/or angular kinetic gravitational forces. (para 11-36b)

78. Carrying the information from the maculae and the cristae to the brain is the vestibular nerve. Contained in the same fibrous sheath from the membranous labyrinth to the brain are the vestibular and auditory nerves. (para 11-37)
79. The simplest and lowest level of control is the reflex arc. Producing wider reactions to stimuli are segmental reflexes. A number of nuclei in the hindbrain monitor and control visceral functions of the body, including respiration and heartbeat. The facilitatory and inhibitory areas of the reticular formation monitor and control general body functions, including sleep. The thalamus is a primary relay for information going to and from the cerebrum and cerebellum. One of the most important integrators of motor activity of the body is the cerebellum. (para 11-39)
80. In humans, the highest level of control is in the cerebrum. Here, we can clearly designate three levels of control.
- a. The first level is concerned with visceral activities of the body, as related to fight-or-flight, fear, and other emotions.
 - b. At the second level, activities of the body are standardized and repetitive in nature. An example is the sequence of muscle actions involved in walking.
 - c. At the third level, brand new solutions can be created. This is the volitional level.
- (para 11-39g)

End of Lesson 11

COMMENT SHEET

SUBCOURSE MD0006 Basic Human Anatomy

EDITION 100

Your comments about this subcourse are valuable and aid the writers in refining the subcourse and making it more usable. Please enter your comments in the space provided. ENCLOSE THIS FORM (OR A COPY) WITH YOUR ANSWER SHEET **ONLY** IF YOU HAVE COMMENTS ABOUT THIS SUBCOURSE..

FOR A WRITTEN REPLY, WRITE A SEPARATE LETTER AND INCLUDE SOCIAL SECURITY NUMBER, RETURN ADDRESS (and e-mail address, if possible), SUBCOURSE NUMBER AND EDITION, AND PARAGRAPH/EXERCISE/EXAMINATION ITEM NUMBER.

PLEASE COMPLETE THE FOLLOWING ITEMS:

(Use the reverse side of this sheet, if necessary.)

1. List any terms that were not defined properly.

2. List any errors.

paragraph error correction

3. List any suggestions you have to improve this subcourse.

4. Student Information (optional)

Name/Rank _____

SSN _____

Address _____

E-mail Address _____

Telephone number (DSN) _____

MOS/AOC _____

PRIVACY ACT STATEMENT (AUTHORITY: 10USC3012(B) AND (G))

PURPOSE: To provide Army Correspondence Course Program students a means to submit inquiries and comments.

USES: To locate and make necessary change to student records.

DISCLOSURE: VOLUNTARY. Failure to submit SSN will prevent subcourse authors at service school from accessing student records and responding to inquiries requiring such follow-ups.